



American  
Association  
of Clinical  
Anatomists

38<sup>th</sup>  
**ANNUAL  
MEETING**

June 28–July 2, 2021  
**VIRTUAL**

[www.clinical-anatomy.org](http://www.clinical-anatomy.org)




# The Anatomical Record

Advances in Integrative Anatomy and Evolutionary Biology

EDITOR-IN-CHIEF:  
**HEATHER F. SMITH**  
MIDWESTERN UNIVERSITY  
GLENDALE, AZ  
**SPECIAL ISSUES**

*The Anatomical Record* regularly publishes special thematic issues on topics of current interest. Articles from many of these issues are freely accessible via the journal's home page, where you can find our most recent Special Issue on The Dog-Human Connection



Upcoming Special Issues will focus on  
New Anatomy of robotics and prosthetics  
New research on the nasopharynx

**AAA JOURNALS:**  
Committed to Providing  
Fast, Fair, Friendly  
Service for Our Authors.

**No Page Charges**  
**No Color Charges**

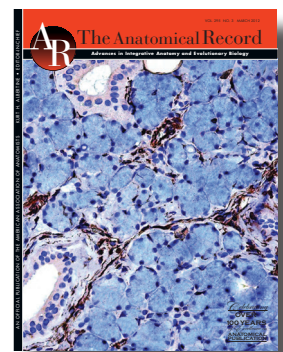
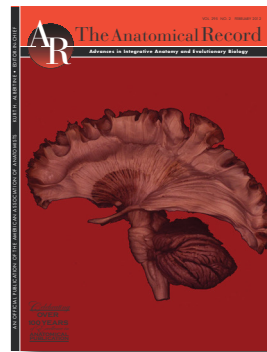**No Cost For  
Supporting  
Information**

## EDITORIAL FOCUS

*The Anatomical Record* is positioned to be the premier publication venue for hypothesis-driven research that uses **biomolecular imaging and image analysis** approaches to integrate morphology with other scientific disciplines:

- cell & molecular biology
- physiology
- biochemistry
- neuroscience
- paleontology
- pathology

In addition to its focus on Full length papers, the journal also includes Reviews, Commentaries, and Letters-to-the-Editor, and AR WOW Video Papers.



## AR FOR AUTHORS


**AR articles receive over 5,000 citations per year:** *AR* has a Cited Half Life of 10 years. You can use our Citation Tracking tool to monitor citations of your own research.

**Open Access=increased discoverability:** *AR* content is openly available 12 months from the publication date. Last year, there were nearly 400,000 clicks on abstracts in the journal, and 130,000 text downloads were made by scientists in 87 countries around the world.

**Speed:** EarlyView publication of all articles is available online within four weeks of final acceptance.

**Online Submission and Peer Review:** Take advantage of our quick and easy process. Submit your manuscripts online via <http://mc.manuscriptcentral.com/ar-wiley>

**AR Insights** articles by the editorial office describe methods or topics of common interest to readers



## #AACA Strong

This has been a unique time to be President of a major society. Over the past two years, much has happened. It has been daunting to lead a society through a time fraught with unknowns. If the struggles and challenges of COVID have not been enough, the crisis of social unrest has also brought us to our knees. Sadly, the word tragic has become all too common in our vocabulary.

Our society has reacted strongly. We are changing, learning, and adapting, despite the obvious fear, anger, vulnerability, and uncertainty of the times: our present and future. As a group, we are performing admirably, courageously and responsibly. Despite the challenges, we are advancing our field and incorporating new ways to teach. Despite the social distancing and isolation, we recognize it's all about people: communicating and collaborating by sharing ideas and experiences and tightening our alliances.

We have been forced to cancel two face-to-face annual meetings which were already well in motion (June 15-19, 2020 at Weill Cornell in New York City which was to be hosted by Estomih Mtui, MD, and Anthony D'Antoni, MS, DC, PhD, and June 28 - July 2, 2021 in Bellevue, Washington planned to be hosted by R. Shane Tubbs, PhD, PA-C and Joe Iwanaga, DDS, PhD). Kudos to Jennifer Burgoon, PhD and MOPP for organizing and reconfiguring these meetings to occur at the prescheduled times. The 2020 meeting was the best virtual meeting ever! It far exceeded our typical target audience – with more than 400 registrants (250 members and 150 guests). It consisted of e-posters and platform presentations, symposia with Q and A (reflecting on lessons learned during this COVID pandemic), exhibitor sessions and business meetings. The 2021 meeting will have a similar scientific format with a continued focus highlighting the Clinical in Clinical Anatomy. This year we will add various social activities to foster engagement, team spirit and friendships: daily coffee talks and evening events (a Welcome Reception, Mentoring Session, Trivia night, a Banquet, and a Jewel Heist). On Monday, we will partner with international groups to share our global perspectives. Nirusha Lachman, PhD, Professor and Chair of the Department of Clinical Anatomy and Robert (Bob) Morreale, MS, Administrative Chair, Division of Experiential Learning (overseeing these specialty areas: Biomedical and Scientific Visualization, Clinical Anatomy, Microsurgery training, Multidisciplinary simulation and the procedural skills Mastery) at the Mayo Clinic, will present a talk "Putting the Clinical Back into Anatomy and Anatomy Back into the Clinic: A Reciprocal Model for Enhancing Education, Practice and Research." On Tuesday, our Presidential Speaker L. Scott Levin, MD, FACS, the Paul B. Magnuson Professor of Bone and Joint Surgery, Chair of the Department of Orthopaedic Surgery at the University of Pennsylvania, a board certified orthopedist and plastic surgery (responsible for developing the field of 'orthoplastic surgery'), and the Chair of the American College of Surgeons Board of Regents, will deliver an address "From the Hunter Brothers to the Perforator Kings: The History of Anatomic Dissection and its Impact on Reconstructive Microsurgery." We celebrate Susan Standring, PhD with the 2021 Honored Member Award and Fiona Stewart, PhD, the R. Benton Adkins Service Award.

This past year, we held a successful regional virtual meeting on Innovation in Integration which was cosponsored with HAPS and was cohosted by Eustathia Lela Giannaris, PhD and Alexandra Wink, PhD (October 3, 2020). We held virtual CART (Clinical Anatomy Round Table) Luncheons with Anne Agur, PhD on February 3, 2021 and Rebecca Pope-Ruark, PhD (Keeping the spark: Avoiding faculty burnout) on March 10, 2021, the latter co-sponsored with HAPS.

Our society, which has prided itself on being safe and inclusive, is fighting louder against discrimination, racism and sexual harassment. We have added an ad hoc Diversity, Equity and Inclusion Committee led by Yasmin Carter, PhD. Sarah Greene, PhD is championing the needs of the deaf and hard of hearing.

Executive Committee, Council and Standing committees have been active: helping make difficult decisions seem easy and fostering innovation. Our membership is engaged. Finances are strong. Clinical Anatomy is flourishing under Shane's leadership. We owe a huge debt of gratitude to ASG, specifically Caitlin Hyatt, Jennifer Whitlow, and Kendra Tyner.

Our society has always led: successfully dealing with these events is consistent with our rich tradition --part of our DNA. This is a time for optimism. Our individual and collective journeys continue. Armed with lessons learned, we will emerge smarter and stronger. The new normal will be different by definition. Our society will forge ahead. We look forward to the **Fort Worth, TX meeting hosted by Rusty Reeves, PhD June 13 - 17, 2022 and with Tom Gest, PhD serving as President –and beyond... 2023 in Orlando, FL (July 9 – 12), 2024 at Weill Cornell Medicine in New York, NY and 2025 in Bellevue, WA. The future of AACA is secure and exciting.**

We have a responsibility to continue to lead in all respects - at work, at home, and in our society. Be safe. Be healthy. Find JOY. Model this for others.

**Robert J. Spinner, M.D.**



The AACA believes that each conference attendee should be treated with respect and dignity and that any form of sexual harassment is a violation of human dignity. The AACA condemns sexual harassment and maintains a "zero - tolerance" for sexual harassment. All conference attendees have the right to participate and learn free of sexual harassment. The AACA will take all reasonable efforts to prevent and promptly correct instances of sexual harassment. Any conference attendee who believes himself or herself to be a victim of sexual harassment is encouraged to report the information to the Program Secretary.

# Table of Contents

Member Sponsors .....	7
Meeting Sponsors .....	8
Exhibitors .....	9
Pre-Meeting Events .....	11
Scientific Program.....	12
Honored Member – Susan Standring MBE, PhD, DSc, FKC, FRBS, Hon FAS, Hon FRCS .....	18
Distinguished Service Award – Fiona Stewart, MB BS (Syd) BSc (UNE) FACBS MACLM.....	19
Presidential Speaker – L. Scott Levin, MD, FACS, FAOA <i>From the Hunter Brothers to the Perforator Kings: The History of Anatomic Dissection and its Impact on Reconstructive Microsurgery</i> .....	21
Live Invited Presentations:	
British Association of Clinical Anatomists.....	23
International Federation of Associations of Anatomy.....	24
Pre-recorded Invited Presentations:	
American Association of Anatomists .....	25
Macedonian Association of Anatomists .....	27
<i>Putting the Clinical Back into Anatomy and Anatomy Back into the Clinic: A Reciprocal Model for Enhancing Education, Practice and Research</i> .....	28
Welcome Reception	
<i>Medicine Meets Museum: How the FWMSH Interprets Prehistoric Surgery</i> .....	29
Coffee Talks .....	30
Committee Meeting Descriptions (Open to All) .....	31
Committee Symposium Descriptions .....	33
Mentorship Reception .....	35
Annual Business Meeting Agenda .....	36
Annual Business Meeting Minutes – Virtual.....	37
Officers of the AACA Council .....	41
<i>Clinical Anatomy</i> – the Official Journal of AACA.....	42
Committee Reports: .....	43
Anatomical Services Committee	
Ad hoc Diversity Inclusion and Equity Committee	
Brand Promotion and Outreach Committee	
Career Development Committee	
Clinical Anatomical Terminology Committee	
Educational Affairs Committee	
Journal Committee	
Listserv Report	
Membership Committee	
MOPP Committee	
Nominating Committee	
Abstract Listing by Author:	
ePlatform Presentations.....	52
ePoster Presentations .....	57

# Bone Clones®

OSTEOLOGICAL

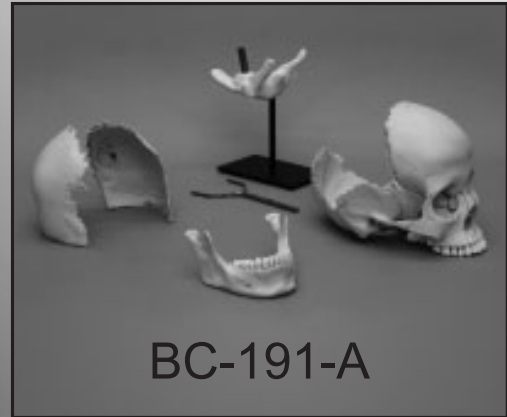
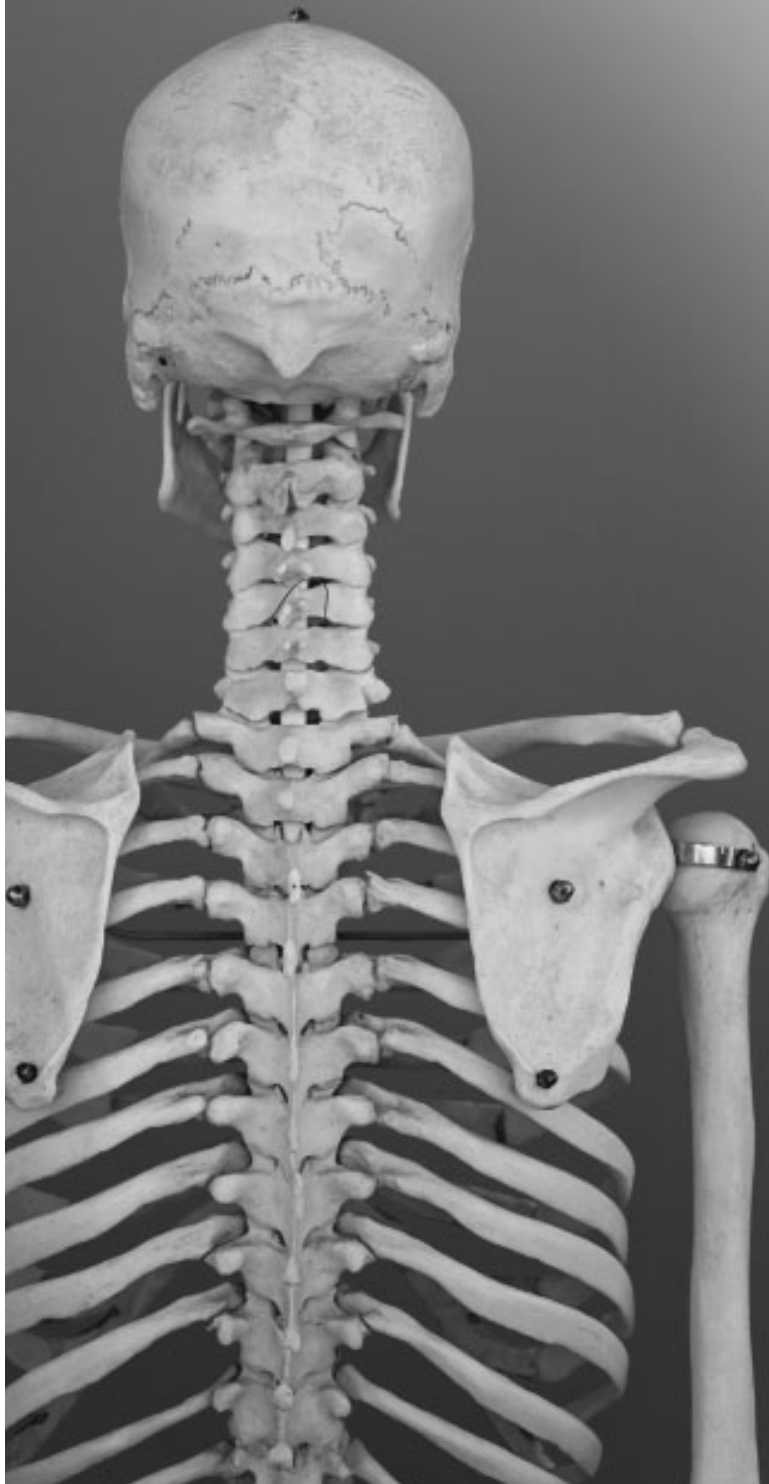

REPRODUCTIONS

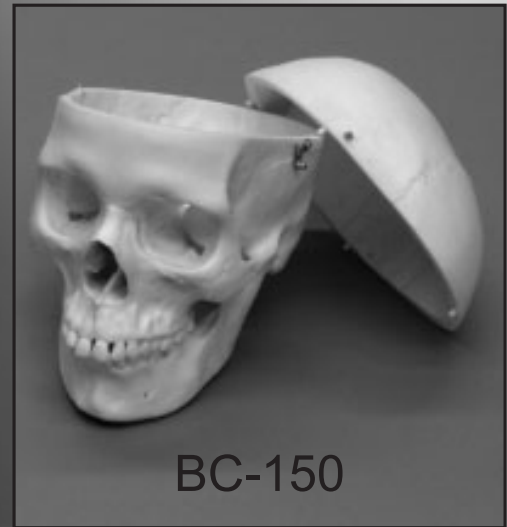[www.boneclones.com](http://www.boneclones.com)

800-914-0091

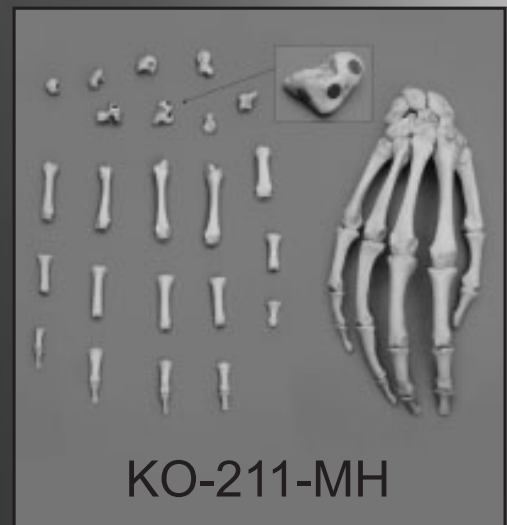818-709-7991



BC-191-A



BC-150



KO-211-MH

# 2021 Member Sponsorship Donors

as of 4-29-21

*Interested in becoming a member sponsor donor?*

Visit the [AACA website](#) for more details.

---

## **Diamond (\$1000)**

---

### **Emerald (\$500)**

*Nancy Halliday*

---

### **Ruby (\$250)**

*Lawrence Wineski*

---

### **Sapphire (\$100)**

*David Davies*

*Ameed Raoof*

*Kimberly S. Topp*

---

### **Other Amount**

*Kelsey Byers*

## 2021 Virtual Meeting Sponsors

AACA would like to thank these generous sponsors!

---

**Welcome Reception Sponsor: Thieme**



---

**Awards Ceremony Sponsor:  
Touch of Life Technologies**



# Exhibitors Listed Alphabetically

---

## **3B Scientific**

Exhibitor Session: Wednesday, June 30, 4:00 – 4:30 PM  
2189 Flinstone Dr, Suite O  
Tucker, GA 30084  
USA  
3bscientific.com  
Anatomical models with awesome digital content!

---

## **3D Organon | Medis Media Pty Ltd**

Exhibitor Session: Tuesday, June 29, 4:30 – 5:00 PM  
2/23 Illawong St  
Surfers Paradise, QLD 04217  
Australia

<https://www.3dorganon.com/>

3D Organon is a cutting-edge anatomy teaching & learning platform, available for Virtual Reality (VR), Mixed Reality (MR), Augmented Reality (AR), desktop, tablet, and mobile devices. It proudly serves the global market. Its extensive knowledge-base of anatomical definitions is available in 15 languages.

---

## **Anatomic Excellence, LLC | von Hagens Plastination**

Exhibitor Session: Tuesday, June 29, 3:30 – 4:00 PM  
112 Steerforth Road  
Savannah, GA 31410  
USA

[www.anatomicexcellence.com](http://www.anatomicexcellence.com)

Anatomic Excellence, LLC is the exclusive, full range agent for Dr. Gunther von Hagens lastinated Human Tissue Specimens in the USA, Canada & Caribbean. We are committed to working with our customers to help them to establish a collection of ethically prepared specimens that meets both the anatomical needs of your program and enhances learning opportunities for your students.

---

## **Bone Clones**

Exhibitor Session: Wednesday, June 30, 3:00 – 3:30 PM  
9200 Eton Avenue  
Chatsworth, CA 91311  
USA

[www.boneclones.com](http://www.boneclones.com)

Bone Clones, Inc. manufactures detailed, high-quality osteological reproductions of skeletal elements. In addition to producing specimens exhibiting trauma and pathology, we have an extensive range of skulls and skeletons providing age, sex, and ancestry differences. Our durable replicas obviate the need for a dedicated teaching collection of real human remains.

---

## **Elsevier**

Exhibitor Session: Tuesday, June 29, 2:00 – 2:30 PM  
1600 John F Kennedy Blvd. Suite 1600  
Philadelphia, PA 19103  
USA

<https://www.elsevier.com/education/welcome-3d4medical>

For more than 135 years, Elsevier has specialized in health science content across the entire curriculum, ensuring students, faculty, and institutions have access to reliable and relevant information. As the premier health science information provider, Elsevier attracts the leading authors and editors in their fields. Our content is shaped for diverse teaching and learning purposes, providing students and educators with a wide range of options for achieving successful outcomes.

---

# Exhibitors, Continued

---

## **Mopec**

Exhibitor Session: Wednesday, June 30, 3:30 – 4:00 PM

800 Tech Row

Madison Heights, MI 48071

USA

[www.mopec.com](http://www.mopec.com)

Mopec provides American-made equipment and supplies to anatomy laboratories, pathology labs, animal research facilities and medical examiner facilities. Founded in 1992, Mopec solutions are among the very best as demonstrated by the vast number of installations in America's top healthcare institutions and universities. Our reputation is built on decades of superior customer service specializing in consultation and customization. Mopec is committed to designing and manufacturing ergonomic equipment to enhance your lab's safety, flexibility and productivity.

---

## **Thieme Group**

Exhibitor Session: Tuesday, June 29, 4:00 – 4:30 PM

333 Seventh Avenue

New York, NY 10001

USA

[www.thieme.com](http://www.thieme.com)

Thieme Publishers is a leading medical publisher serving health professionals & students by publishing the latest advancements in clinical practice and advocating medical education for more than 130 years. State-of-the-art online products include MedOne, an e-learning platform provided by master surgeons, incl. videos, step-by-step procedures & Q+A sessions.

---

## **Touch of Life Technologies**

Exhibitor Session: Tuesday, June 29, 3:00 – 3:30 PM

12635 E. Montview Blvd., Suite 350

Aurora, CO 80045

USA

[www.toltech.net](http://www.toltech.net)

Touch of Life Technologies (ToLTech) is a full solutions provider for anatomical hardware and software. Through a broad range of solutions, TolTech enables users to expand the learning experience in and out of the lab or classroom. Decades of research and development have culminated into our VH Dissector™ platform which enables students and educators around the world to interact with real human anatomy on a variety of devices from collaborative multi-touch to iPads and AR and VR devices.

---

## **Visible Body**

Exhibitor Session: Thursday, July 1, 4:00 – 4:30 PM

11 Mercer

Natick, MA 01760

USA

[www.visiblebody.com](http://www.visiblebody.com)

Virtual anatomy educational technology.

---

## **Wolters Kluwer**

Exhibitor Session: Tuesday, June 29, 2:30 – 3:00 PM

2001 Marker Street

Philadelphia, PA 19103

USA

[www.lww.com](http://www.lww.com)

Wolters Kluwer Health is a leading global provider of information and point of care solutions for the healthcare industry. Our solutions are designed to help professionals build clinical competency and improve practice so they can make important decisions on patient care. Our leading product brands include Audio-Digest, Lippincott, Ovid®, UpToDate®, and others.

---




**38<sup>th</sup>**  
**ANNUAL**  
**MEETING**

## Pre-Meeting Events - Sunday, June 27th

Time (Eastern)	Session Name	Session Topic/ Overview	Location
9:00 a.m.	Silent Auction Begins		<a href="#">32 Auctions</a>
10:00 a.m. – 3:00 p.m.	AACA Council Meeting		Closed Zoom Meeting

*continued on next page*

# Scientific Program - Monday, June 28th

Time (Eastern)	Session Name	Session Topic/Overview	Location
All Day Event	Conference attendees can view accepted ePosters and ePlatforms on Planstone all week (Monday, June 28 through Friday, July 2) at their leisure. Be sure to provide evaluations for your colleagues at the end of their presentations. Additionally, CAT and CDC symposia are available for viewing during these days.		Planstone System (Login Required)
All Day	Invited Talk - American Association of Anatomists	<b><i>The Combined Activation of Scleraxis and CD36 in Intestinal Fibroblasts "Potential Role in Fibrosis"</i></b>	Pre-recorded presentations uploaded in Planstone under invited speakers
All Day	Invited Talk - Macedonian Association of Anatomists	<b><i>A Short Review of the Activity of the Macedonian Association of Anatomists</i></b>	Pre-recorded presentations uploaded in Planstone under invited speakers
All Day	Invited Talk - Nirusha Lachman PhD and Robert Morreale MS	<b><i>"Putting the Clinical Back into Anatomy and Anatomy Back into the Clinic": A Reciprocal Model for Enhancing Education, Practice and Research</i></b>	Pre-recorded presentations uploaded in Planstone under invited speakers
All Day	Silent Auction		<a href="#">32 Auctions</a>
12:00 p.m. – 1:00 p.m.	Invited Talk – British Association of Clinical Anatomists (BACA)	<b><i>Clinical Anatomy – should we really call it applied anatomy?</i></b>	Link will be posted in Planstone
1:00 p.m. – 2:00 p.m.	Invited Talk - International Federation of Associations of Anatomists (IFAA)	<b><i>Traditional Versus Modern Clinical Anatomy</i></b>	Link will be posted in Planstone
6:30 p.m. – 8:00 p.m.	Welcome Reception – Sponsored by 	Welcome by Dr. Robert Spinner  Virtual Exhibit presentation by Forth Worth Museum of Science and History - <b><i>Medicine Meets Museum: How the FWMSH Interprets Prehistoric Surgery</i></b>	Link will be posted in Planstone

continued on next page

# Scientific Program - Tuesday, June 29th

Time (Eastern)	Session Name	Session Topic/ Overview	Location
All Day	Conference attendees can view accepted ePosters and ePlatforms on Planstone all week (Monday, June 28 through Friday, July 2) at their leisure. Be sure to provide evaluations for your colleagues at the end of their presentations. Additionally, CAT and CDC symposia are available for viewing during these days.		Planstone System (Login Required)
All Day	Silent Auction		<a href="#">32 Auctions</a>
9:00 a.m. – 10:00 a.m.	Coffee Talk		Link will be posted in Planstone
10:00 a.m. – 11:15 a.m.	Presidential Speaker <b><i>From the Hunter Brothers to the Perforator Kings: The History of Anatomic Dissection and its Impact on Reconstructive Microsurgery.</i></b>	Introduction by Dr. Robert Spinner  Presidential Speaker: Dr. L. Scott Levin, MD, FACS, FAOA	Link will be posted in Planstone
12:00 p.m. - 1:45 p.m.	ASC Lunch Meeting	<b><i>International COVID-19 Reflections from Body Donor Programs</i></b>	Zoom - Link provided under Symposium Tab
2:00 p.m. - 2:30 p.m.	Exhibitor Session #1	Elsevier	Link will be posted in Planstone
2:30 p.m. - 3:00 p.m.	Exhibitor Session #2	Wolters Kluwer	Link will be posted in Planstone
3:00 p.m. - 3:30 p.m.	Exhibitor Session #3	Touch of Life Technologies	Link will be posted in Planstone
3:30 p.m. - 4:00 p.m.	Exhibitor Session #4	Anatomic Excellence   von Hagens Plastination	Link will be posted in Planstone
4:00 p.m. - 4:30 p.m.	Exhibitor Session #5	Thieme	Link will be posted in Planstone
4:30 p.m. - 5:00 p.m.	Exhibitor Session #6	3D Organon   Medis Media Pty Ltd	Link will be posted in Planstone
6:00 p.m. – 7:30 p.m.	Mentoring Session		Link will be posted in Planstone


continued on next page

# Scientific Program - Wednesday, June 30th

Time (Eastern)	Session Name	Session Topic/ Overview	Location
All Day	Conference attendees can view accepted ePosters and ePlatforms on Planstone all week (Monday, June 28 through Friday, July 2) at their leisure. Be sure to provide evaluations for your colleagues at the end of their presentations. Additionally, CAT and CDC symposia are available for viewing during these days..		Planstone System (Login Required)
All Day	Silent Auction		<a href="#">32 Auctions</a>
9:00 a.m. - 10:00 a.m.	Coffee Talk: <b>Meet and Greet with the Diversity, Equity, and Inclusion Committee</b>		Link will be emailed to pre-registered attendees
12:00 p.m. - 1:45 p.m.	CDC Lunch Meeting	<b>How to Build Your Brand and Which role should I emphasize: Research, Teaching, Service?</b>	Link will be emailed to pre-registered attendees
2:00 p.m. - 2:45 p.m.	CAT Symposium Q&A -	<b>“Prone” to Misunderstanding: Technical Terminology, Language Evolution, and the Problem of People</b>	Link will be emailed to pre-registered attendees
3:00 p.m. - 3:30 p.m.	Exhibitor Session #7	Bone Clones	Link will be emailed to pre-registered attendees
3:30 p.m. - 4:00 p.m.	Exhibitor Session #8	Mopec	Link will be emailed to pre-registered attendees
4:00 p.m. - 4:30 p.m.	Exhibitor Session #9	3B Scientific	Link will be emailed to pre-registered attendees
6:00 p.m. - 8:00 p.m.	Trivia Night (separate registration required)		Link will be emailed to pre-registered attendees

continued on next page

# Scientific Program - Thursday, July 1st

Time (Eastern)	Session Name	Session Topic/ Overview	Location
All Day	Conference attendees can view accepted ePosters and ePlatforms on Planstone all week (Monday, June 28 through Friday, July 2) at their leisure. Be sure to provide evaluations for your colleagues at the end of their presentations. Additionally, CAT and CDC symposia are available for viewing during these days.		Planstone System (Login Required)
All Day	Silent Auction		<a href="#">32 Auctions</a>
9:00 a.m. - 10:00 a.m.	Coffee Talk: <b>Promoting Equity and Inclusion through Anatomy: Working with Deaf and Hard of Hearing Patients and Students</b>	Led by Sarah Greene	Link will be emailed to pre-registered attendees
12:00 p.m. - 1:45 p.m.	EAC Lunch Meeting -	<b>Impact of COVID-19 on assessments in anatomy curriculum.</b>	Link will be emailed to pre-registered attendees
2:00 p.m. - 2:45 p.m.	CDC Symposium Q&A	<b>A Review of U.S. Medical Schools' Promotion Standards for Excellence in Education and Unsolicited Advice on Academic Promotion</b>	Link will be emailed to pre-registered attendees
3:00 p.m. - 4:00 p.m.	State of the Association & Business Meeting		Link will be emailed to pre-registered attendees
4:00 p.m. - 4:30 p.m.	Exhibitor Session #10	Visible Body	Link will be emailed to pre-registered attendees
6:00 p.m. - 7:00 p.m.	Awards Ceremony – Sponsored by 		Link will be emailed to pre-registered attendees
7:00 p.m. - 8:30 p.m.	Virtual Jewel Heist (separate registration required)		Link will be emailed to pre-registered attendees

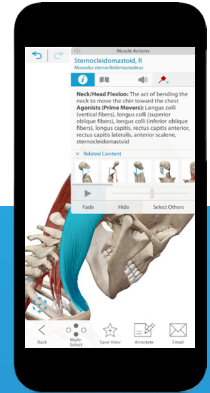
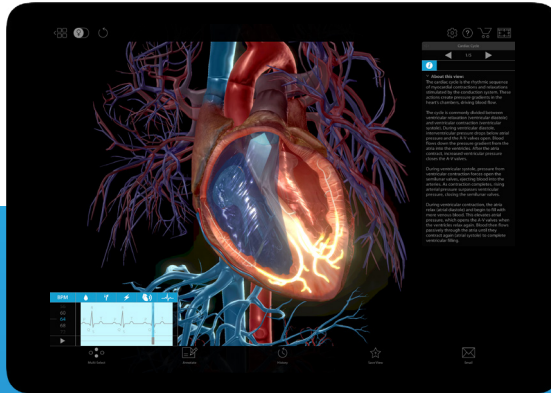
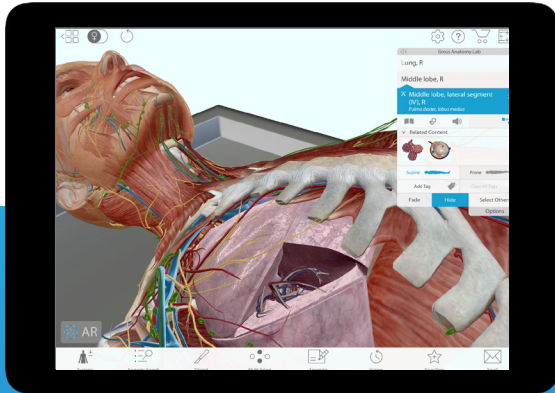
continued on next page

# Scientific Program - Friday, July 2nd

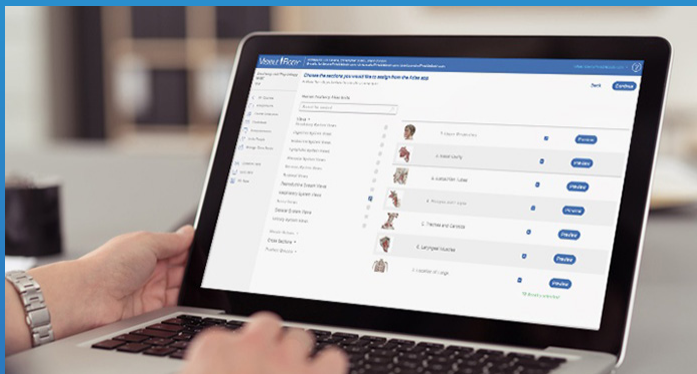
Time (Eastern)	Session Name	Session Topic/ Overview	Location
<b>All Day Event</b>	Conference attendees can view accepted ePosters and ePlatforms on Planstone all week (Monday, June 28 through Friday, July 2) at their leisure. Be sure to provide evaluations for your colleagues at the end of their presentations. Additionally, CAT and CDC symposia are available for viewing during these days.		Planstone System (Login Required)
<b>9:00 a.m. - 3:00 p.m.</b>	Silent Auction		<a href="#">32 Auctions</a>
<b>9:00 a.m. - 10:00 a.m.</b>	Coffee Talk: <b><i>Looking Forward: A preview of the 2022 Annual Meeting</i></b>		Link will be posted in Planstone
<b>12:00 p.m. - 1:45 p.m.</b>	CAT Lunch Meeting	Committee Mtg and 'Pub-Style Quiz' based upon three anatomical terminology-related areas: pronunciations, plurals and etymology and eponyms.	Link will be posted in Planstone
<b>2:00 p.m. - 3:00 p.m.</b>	Teaching During Covid: An Open Dialogue		Link will be posted in Planstone
<b>3:00 p.m. - 3:15 p.m.</b>	Closing Remarks/Final Thoughts		Link will be posted in Planstone
<b>3:30 p.m. - 4:30 p.m.</b>	New Council Meeting		Invitation Only



# Taking Virtual & In-Person Learning to New Heights



Visually engaging 3D + AR human anatomy, physiology and biology content that's increasing grades and saving professors time.



Our LMS Courseware maps to any textbook, features Canvas and Blackboard Single Sign On and allows professors to autograde A+P labs, annotate 3D models, assign immersive dissection quizzing, custom share links on web (PC/Mac) and mobile and so much more.

Be sure to visit us during the Visible Body Exhibitor Session  
**Thursday, July 1 from 4:00 - 4:30pm EST**

**To read professor testimonials and request a free trial, visit:**

[visiblebody.com/aaca](https://visiblebody.com/aaca)

# Honored Member, 2021

## The American Association of Clinical Anatomists Recognizes and Awards Honored Membership to Susan Standing MBE, PhD, DSc, FKC, FRBS, Hon FAS, Hon FRCS



Susan Standing is an Emeritus Professor of Anatomy at King's College London (having previously been Head of the Department of Anatomy at KCL), a Fellow of King's College London and an Honorary Fellow of both the Anatomical Society and the Royal College of Surgeons of England (RCSEng). I taught medical, dental and biomedical science undergraduates and postgraduate surgical trainees for over 40 years and continue to champion anatomy as a fundamental component of medical and dental curricula in my retirement.

My research (as Susan Hall) was predominantly in the field of peripheral nerve repair and Schwann cell biology in primary demyelination/ remyelination and in chronic denervation: I published over 200 papers and chapters and was the recipient of numerous research grants. I am a past President of the Anatomical Society and of the Peripheral Nerve Society and the current Editor-in-Chief of Gray's Anatomy (39th – 42nd editions) and Joint Lead Editor of Gray's Surgical Anatomy. I am a Trustee of the Hunterian Collection at the Royal College of Surgeons of England and President of the Hunterian Society. I have twice been the recipient of the Wood Jones Medal of the RCSEng.

---

### Previous Honored Members of the AACA

1984 - W. Henry Hollinshead\*  
1985 - Chester B. McVay\*  
1986 - Donald James Gray\*  
1987 - Russell T. Woodburne\*  
1988 - Oliver Behrs\*  
1989 - N. Alan Green\*  
1990 - Frank H. Netter\*  
1991 - Ralph Ger\*  
1992 - M. Roy Schwarz  
1993 - Carmine D. Clemente\*  
1994 - Keith L. Moore  
1995 - Ray J. Scothorne\*  
1996 - Robert A Chase

1997 - Tatsuo Sato  
1998 - John E. Skandalakis\*  
1999 - Donald R. Cahill\*  
2000 - Sandy C. Marks, Jr.\*  
2001 - David G. Whitlock\*  
2002 - Robert D. Acland\*  
2003 - Arthur F. Dalley, II  
2004 - John V. Basmajian\*  
2005 - Ian Whitmore  
2006 - Peter H. Abrahams  
2007 - Gary Wind  
2008 - T.V.N. (Vid) Persaud  
2009 - Richard S. Snell

2010 - Raymond F. Gasser  
2011 - Harold Ellis  
2012 - Ronald A. Bergman  
2013 - John Hansen, Ph.D.  
2014 - Victor M. Spitzer, Ph.D.  
2015 - Carol E. Scott-Conner EH, MD, Ph.D.,  
FACS  
2016 - Carlos Machado, MD, Medical  
Illustrator  
2017 - James D. Collins, MD.\*  
2018 - Anne Agur, BSc, MSc, PhD  
2019 - Robert Anderson, MD, PhD, FRCPath  
2020 - Stephen W. Carmichael, Ph.D., D.Sc.

\* deceased

# **R. Benton Adkins Jr. Distinguished Service Award, 2021**

**The American Association of Clinical Anatomists  
Recognizes and Awards the R. Benton Adkins Jr. Distinguished Service Award to  
Fiona Stewart, MB BS (Syd) BSc(UNE) FACBS MACLM**



A member of many specialty committees, including Chair of Royal Australasian College of Surgeons (RACS) Surgical Sciences Anatomy Examinations Committee, an invited teacher and consultant at training courses, Fiona has taught throughout Australia, New Zealand and in USA (UC San Francisco, and Meharry Medical College, Tennessee).

Author of 3 books, she has contributed to numerous publications, and is recipient of many awards for excellence of teaching and courses, and for regional business promotion. She was awarded the RACS Medal for Excellence of Service and the RACS Heslop Medal.

Fiona Stewart began teaching anatomy through dissection at the University of Sydney as a medical student. Leaving school to work at 13, she rode as a jockey and worked as a woolclasser and 'expert' while undertaking correspondence education, matriculated, studied veterinary science and medicine, graduating MB.BS. with a 2-year exemption, she was appointed to Royal Prince Alfred Hospital and Royal Alexandra Children's Hospital, NSW, Australia. Engaged in surgical and clinical work, she continued to empower students and trainees with anatomical knowledge. As a committee member and later Undergraduate Vice-president of Sydney University Medical Society, Fiona initiated the import of various texts, which continue to be the foundation of many anatomical courses within NSW and Australia.

From 1988, as research supervisor, she has contributed to numerous publications by her students. Annually, Fiona has attended surgical specialty, dental, plastination, and anatomy meetings, and made international visits to laboratories to learn and collaborate. She has brought students to meetings in Australia, New Zealand, Britain, Europe, Japan, Canada and USA as poster and platform presenters.

From 1986 to 2008, while working in surgery and at University of Sydney, she co-ordinated and taught clinically applied regional anatomy by dissection to medical and dental students. She designed and delivered an annual RACS State Branch intensive whole cadaver dissection course; postgraduate cadaver courses in head and neck, maxillo-facial, thorax, abdomen, pelvic floor, limbs, spine, flap and digit graft-harvest and anastomoses, specialty endoscopic, dental implant placement in embalmed cadavers (using scanned-image treatment planning, bone and soft tissue harvest/graft, 'sinus-lift' teaching) and collaborated in investigation of bio-compatible 3D printed body 'parts'. From those courses came candidates for research, publications, and conference presentations.

*continued on next page*

The Foundation Professorial Appointment in Anatomy, 2008, at the School of Rural Medicine, University of New England (UNE), Australia, tasked to teach prescribed anatomy in its problem based learning (PBL) curriculum; provide its students with an 'elective', extra-curricular whole cadaver dissection course emphasising regional anatomy and its clinico-pathological application; establish an intensive whole cadaver, regional with application, postgraduate dissection course; prepare prosections; conduct and publish anatomically-based research.

An internationally certified anatomical embalmer; state government 'pathology-medical referee – cremations'; and a NSW Police Service Forensic Medical Officer, she established and administered a body donor programme and memorial ceremony, and a neurosurgical training laboratory using flexible cadavers with in-situ fixed brains at UNE. Some students who sought training as certified embalmers became casual-employee lab-techs. Indeed, Fiona has utilised many medical and dental students with an enthusiasm for teaching and anatomy, to aid her in dissection courses, to various audiences.

During the 1990s, Australian reports of increased medical malpractice litigation, considered to be result of anatomical ignorance among graduates of 'new curricula' medical courses, appeared. Fiona compiled evidence related to anatomical teaching and evidence of procedural anatomical ignorance evident at coronial inquest in pathology photographs, tendered interventional images, and post- mortem reports.

Fiona has a tireless approach to education of students of all levels, and her teaching is centered on clinical / surgical relevance. In all of her courses there has been emphasis on clinicians / surgeons to assist at the dissection table.

*Biography by Michael Hornby, BDS GradDipClinDent (Sedation) GradCertAnat (Surg&Radiol)*

---

### **Previous R. Benton Adkins Jr. Distinguished Service Award Recipients**

2004 – Robert J. Leonard  
2006 – Daniel O. Graney  
2007 – Ralph Ger\*  
2009 – Arthur F. Dalley  
2011 – Carol Scott-Conner  
2012 – Keith L. Moore\*  
2013 – Stephen W. Carmichael  
2015 - Lawrence M. Ross\*  
2016 – Thomas Quinn  
2017 – Ronald S. Wade  
2019 – Brian R. MacPherson, Ph.D.  
2020 – Neil S. Norton, Ph.D.

*\* deceased*

# Presidential Speaker

## Tuesday, June 29th | 10:00 - 11:15 a.m.

### L. Scott Levin, MD, FACS, FAOA

#### *From the Hunter Brothers to the Perforator Kings: The History of Anatomic Dissection and its Impact on Reconstructive Microsurgery.*



The rite of passage for all that practice medicine is the understanding of anatomy as it applies to disease. The history of anatomic dissection is rich with discovery that has had profound impact on medical sciences and particularly surgery. A few hundred years ago, anatomic dissection risked death to those students that were dissecting. Recent trends in medical schools that have curtailed extensive teaching of anatomy are concerning. For more than six decades, the evolution of reconstructive microsurgery and autologous tissue transplantation has relied solely on reconstructive surgeons searching the body for new vascularized territories than can be moved on their vascular pedicles. Terms such as angiosomes or perforasomes are now part of our surgical lexicon and the concept of “Vascularized Composite Allotransplantation” will breathe new life into the study of anatomy and advance reconstructive options for countless patients ravaged by disease.

#### **Biography:**

L. Scott Levin, MD, FACS, is the Paul B. Magnuson Professor of Bone and Joint Surgery (with tenure), Chair of the Department of Orthopaedic Surgery at the University of Pennsylvania School of Medicine, and Professor of Surgery (Plastic Surgery). He is also the Medical Director of the Penn Musculoskeletal and Rheumatology Service Line. Dr. Levin is Board-certified in Orthopaedic Surgery and has a Certificate of added Qualification in hand surgery. In addition, he is Board-certified in Plastic Surgery.

As an accomplished clinician, his expertise focuses on surgery of the hand and upper extremity, reconstructive microsurgical techniques for extremity reconstruction and limb salvage. His research interests focus predominantly on extremity soft tissue reconstruction and vascularized composite allotransplantation.

Working collaboratively with colleagues across medical disciplines, Dr. Levin established and was the Director of Duke’s Human Tissue Laboratory and also directed the Anatomic Gifts Program. He also established a Human Tissue Laboratory at Penn which opened in May 2011. The Human Tissue Laboratory acts as a teaching tool and a research facility benefiting students, residents

*continued on next page*

and CME participants. Dr. Levin heads the Vascularized Composite Allotransplantation (VCA) Program at Penn and directed the teams that performed bilateral hand and arm transplants, one in September 2011 and two international patients, one in August 2016 and then February 2019. In 2015, as Director of the Pediatric Hand Transplantation Program of Children's Hospital of Philadelphia, he led the team that performed the world's first bilateral hand transplant in a child.

As a committed educator, Dr. Levin has been recognized for his commitment to teaching with the 2007 Master Clinician/Teacher Award for his accomplishments in both clinical care and education at Duke and in 2014 was awarded the I.S. Ravdin Master Clinician Award, a Penn Medicine Award of Excellence at the Perelman School of Medicine at the University of Pennsylvania. In 2015, he was named Individual Innovator of the Year at the Philadelphia Business Journal Healthcare Innovator Awards. He was inducted in 2018 into the Academy of Master Surgeon Educators of the American College of Surgeons.

Widely published with 400 peer-reviewed journal articles, 85 book chapters and 11 books, Dr. Levin also actively participates in senior leadership activities of many international and national professional societies and associations including serving as Board of Regents Chair and Orthopaedic Regent of the American College of Surgeons, Past President of the American Society for Surgery of the Hand, Past Chair of the VCA Transplantation Committee of the United Network for Organ Sharing, President of the World Society of Reconstructive Microsurgery (2013-2015), President of the American Society for Reconstructive Microsurgery (2006-2007), member-at-large of the American Society of Plastic and Reconstructive Surgeons, President of the American Society for Reconstructive Transplantation (2010-2012) and member of the Board of Directors of the American Board of Plastic Surgery (2006-2012). In addition, Dr. Levin has been honored as a North American Traveling Fellow, the American British Canadian Traveling Fellow by the American Orthopaedic Association and the Sterling Bunnell Traveling Fellow by the American Society for Surgery of the Hand. In 2015, he was awarded the Andrew J. Weiland Medal by the American Society for Surgery of the Hand. He has served as the Orthopaedic Trauma Association's Landstuhl Scholar, caring for our war-injured soldiers in Germany.

Dr. Levin is responsible for developing the field of "Orthoplastic Surgery" and currently is Editor-in-Chief of the journal *Orthoplastic Surgery* (Elsevier.)

# BACA Presentation

## Monday, June 28th | 12:00 - 1:00 p.m.

### Peter Dangerfield, MD

*Clinical Anatomy – should we really call it applied anatomy?*



The role of anatomy within the healthcare professions and other related areas is becoming ever important as advances in imaging, clinical care and other innovations are leading to significant potential changes in the way health care is practiced.

Historically, the British Association of Clinical Anatomists (BACA) has been at the forefront in the promotion of the importance of clinically applied anatomy, reflected in its recent on-line webinars and seminars initiated since the outbreak of the COVID pandemic. These have been used to illustrate the role of anatomy in a range of talks focussed on clinical procedures, education and other areas.

Education in undergraduate and postgraduate anatomy has had to evolve rapidly to address the significant restrictions that have arisen. Surgery is a good example of these changes, where clinically focussed anatomy is more and more a driver of the postgraduate assessments of the four Royal Colleges in the UK.

But this inevitably raises a fundamental question of What is Clinical Anatomy? Is this actually the right term to use to describe what is effective applied anatomy?

This presentation will hopefully generate discussion relating to the ongoing important role of the science of anatomy in the 21st Century and the focus on clinical need.

Professor Peter Dangerfield MD is President of the British Association of Clinical Anatomists (BACA), United Kingdom.

#### **Biography:**

Peter Dangerfield qualified in Medicine at St. Andrew's in Scotland. He worked in Liverpool in orthopaedic surgery with research interests in the aetiology and pathogenesis of scoliosis and Perthes Disease in hips and how these conditions affect the growing child. The identification of growth pattern abnormalities in the subjects is ongoing and continues to generate new hypotheses of the underlying causes of the conditions.

His educational experience covers applied anatomy with particular interests in imaging. He has been involved extensively in undergraduate education with a role of director of the entry year of students at the Liverpool Medical School. In Postgraduate medicine, he is an examiner at the Royal College of Surgeons of London and is presently working on an educational programme in anatomy for the MRCS assessment. He has interests in Problem and Case based learning and assessment. He is a member of the Medical Academic Staff Committee at the British Medical Association and a past Chair of the committee.

He is a long standing member of the British Association of Clinical Anatomy and currently its President. He is married with two children and three grandchildren and has an interest in music, being Chairman of the Rodewald Concert Society in Liverpool.

**IFAA Presentation**  
**Monday, June 28th | 1:00 - 2:00 p.m.**  
**Bernard Moxham, B.Sc., B.D.S., PhD, FHEA, FRSB, Hon FAS, FSAE**  
*Traditional Versus Modern Clinical Anatomy*



The 'traditional' teaching of gross anatomy with human cadavers is increasingly being supplanted by digital technologies, particular since the arrival of the COVID-19 pandemic. Furthermore, this trend is accelerating because of the perceived cost of maintaining dissecting room facilities, because of issues relating to body donations, and/or following curriculum reviews that consider surgery and anatomy to be more worthy of postgraduate education. Issues have also arisen with the instigation of integrative examinations for the healthcare professions and with students who are more strategic in their learning. In this talk, I will critically assess these trends in the light of pedagogic research that indicates that students and anatomists (whether they style themselves 'traditionalists' or 'modernists') prefer to learn/teach anatomy by practical methodologies, as befits practical healthcare professions within higher educational establishments.

**Biography:**

Bernard Moxham is Emeritus Professor of Anatomy at Cardiff University (Wales, UK) and Visiting Professor at St. George's University (Grenada). He was Deputy Director of the Cardiff School of Biosciences. He is the Immediate Past President of the International Federation of Associations of Anatomists (IFAA) and Past President of the Anatomical Society (of Great Britain and Ireland) and of the European Federation for Experimental Morphology. He is a qualified clinician and is a member of BACA. His research covers craniofacial biology and embryology and connective tissue biology. Because of his interest in pedagogic research, he founded the Trans-European Pedagogic Anatomical Research Group and he has published extensively on matters relating to teaching in Clinical Anatomy. He leads the development of core syllabuses in the anatomical sciences for the IFAA.

# American Association of Anatomists

Pre-recorded – available all week

**Samuel Kirsch, Andrea Nillas,  
Michael P. Czubryt, PhD, Titus A. Reaves, PhD**

## ***The Combined Activation of Scleraxis and CD36 in Intestinal Fibroblasts “Potential Role in Fibrosis”***

Fibrosis can result from dysregulated deposition of excessive and aberrant extracellular matrix proteins, principally collagen. While fibrosis is an organ specific process, it is also a multisystem process. Intestinal fibrosis typically follows Crohn's Disease (CD); which is described as idiopathic transmural inflammation that can emerge anywhere in the gastrointestinal tract from mouth to anus. Such inflammation can result in bowel adhesions intestinal fistulas, and bowel obstructions. Although several cell types may release the collagen, the predominate cell is the fibroblast. Fibroblasts are most active during development and following inflammatory insults. In particular, myofibroblasts display muscle cell characteristics as they contract during wound healing. We investigate CD36 and scleraxis for their effects on the activation of intestinal fibroblasts. CD36 is a scavenger and membrane bound protein that has a variety of effect on cells. Specifically, it's an indicator of inflammation, interacts with TLRs 2,4,6, and is a receptor for collagen. Scleraxis was originally identified as a transcription factor in the basic helix-loop-helix family and involved in the release of type 1 collagen leading to the production of tendon and bone. One gene codes for two proteins. More recent studies show that scleraxis is involved in several diseases, including cardiac fibrosis. Thus, we examine intestinal fibroblasts for a connection between CD36 and scleraxis. In vivo, CD36 deficient mice show reduced expression of scleraxis. In vitro studies using siRNA also show that when CD36 is reduced, scleraxis is also reduced. Immuno-purification studies revealed that both proteins appear connected. Moreover, under inflammatory conditions (DSS colitis) scleraxis appears further reduced. When both proteins are uncoupled scleraxis deficient cells are not as adherent compared to normal and CD36 deficient cells. Results suggests that CD36 may be involved in adhesion and scleraxis involved in migration in intestinal fibroblasts.

### **Biographies:**



Samuel Kirsch, B.S.

Samuel Kirsch received his high school diploma and was the valedictorian with a GPA of 4.00 and graduated from the honors college at the College of Charleston, in Charleston, SC with a major in biology and a minor in psychology with a GPA of 3.978 Summa Cum Laude. He is currently a first year medical student at the University of Maryland expecting to graduate in 2024. For the summer of 2021, he has been worked as a lab assistant at UMMC, in the Department of Gastroenterology in Baltimore, MD. Moreover, and while at the College of Charleston he was also a research assistant at the Medical University of SC investigating the role and Scleraxis (transcription protein) that is involved in collagen processing and CD36 (scavenger and membrane bound protein) that is a receptor for Collagen; in the combined activation of intestinal fibroblasts. Samuel worked at the National Institutes of Health in a projects where he was analyzing the effectiveness and efficacy of iTRAQ technique to other mass spectrometry. His ultimate goals are to continue basic science research as a practicing physician.



Andrea Nillas, MD

Andrea Nillas received her BS degree in biology and minor in music from the honors college at the College of Charleston in Charleston, SC. While at the College of Charleston her focus was in molecular biology and graduated Magna Cum-Laude. She also graduated from the University of South Carolina School of Medicine in Columbia, SC with a Doctor of Medicine Degree. Currently, she is in the Emergency Medicine Residency Program at the UT Southwestern Medical Center in Dallas, Texas. In terms of research, she was a laboratory technician at the Medical University of South Carolina in the Department or Regenerative Medicine & Cell Biology. In that capacity her research focused on epithelial cell biology to evaluate the molecular pathways involved in immune system responses facilitated by regulation Poly Morphonuclear leukocyte migration with special interest in inflammatory bowel disease (Crohn's Disease and Ulcerative Colitis). She worked in Dr. Titus Reaves' laboratory where she maintained cell lines, performing protein assays, western blots and confocal microscopy. As a senior project, she was involved in independent

scinetific research under the guidance of Dr. Andrew Shedlock, meeting IRB certification standards to detect differential selection in six polymorphic human genes across demographically separated ancestral populations. This research work was conducted Hollings Marine Lab at the College of Charleston.

*continued on next page*



Michael P. Czubryt, PhD, FCVS, FAHA, FIACS  
*Interim Executive Director of Research, St. Boniface Hospital*

Dr. Michael Czubryt is a principal investigator in the Institute of Cardiovascular Sciences, St. Boniface Hospital Albrechtsen Research Centre, and full professor in the Department of Physiology and Pathophysiology, Rady Faculty of Health Sciences, University of Manitoba. He currently serves as Associate Dean in the Faculty of Graduate Studies. His research program focuses on discovery of the underlying mechanisms of gene regulation in heart failure, with a focus on cardiac and vascular fibrosis, and the translation of these discoveries to novel therapeutic interventions in the clinic. He has published over 70 research articles and chapters, and his work has been supported by the Heart and Stroke Foundation of Canada, the Canadian Institutes of Health Research, and the Canadian Foundation of Innovation. His work has been recognized throughout his scientific career, including the McDonald Scholarship of the Heart and Stroke Foundation, the Young Investigator Award of the Canadian Cardiovascular Society, the Ronald Duhamel Innovation Fund Award, the Distinguished Service Award

from the International Academy of Cardiovascular Sciences, and fellowship in three scholarly societies including the American Heart Association. Dr. Czubryt has an extensive record of service at the local, national and international level, including more than thirteen years on animal ethics committees, and is currently Vice-Chair of the Board of Directors of the Canadian Council on Animal Care. He has been a reviewer, scientific officer and chair of numerous peer review committees locally, nationally and internationally, and has served in leadership roles for professional organizations such as the American Physiological Society and the International Academy of Cardiovascular Sciences. Dr. Czubryt also maintains an active training program that encompasses high school, undergraduate and graduate students, with more than 50 trainees mentored to date and service on the advisory committees of more than 40 graduate students.



Titus A. Reaves, PhD

Titus Reaves is an Assistant Professor in the Department of Regenerative Medicine and Cell Biology at the Medical University of South Carolina (MUSC). He also has a joint appointment in the Department of Medicine. He holds a Ph.D. in Anatomy from the University of South Carolina School Of Medicine; his thesis was the understanding the biology of the Basement Membrane of the Heart. He completed a Postdoctoral Fellowship Emory University in the Department of Pathology and Laboratory Medicine where he investigated Neutrophil Migration in Intestinal Inflammation. At MUSC, Dr. Reaves is an instructor the Anatomical Basis of Medicine (Human Anatomy) to first year medical students; moreover, he also teaches GI physiology. He has been an instructor of “research ethics” to first year MD, Ph.D. students. Dr. Reaves is the organizer of the Ernest Everett Just Scientific Symposium that supports diversity in graduate Medical Education. In this capacity, nearly 400 undergraduate students from the States’ of SC, NC, GA, Fla, and MD attend a one-day conference on the campus of MUSC on the impact of Dr. Ernest Everett Just, Ph.D., role models in science and medicine, scientific presentations by national

and international scientist in an effort to increase minority student interest in science as a career. Dr. Reaves received the Basic Science Award in recognition of an exemplary research presentation at the Macro Cabrera Poster Session of the NMRI 7th Annual Workshop NIDDK at the National Institutes of Health. He was nominated for an Educator-mentor award for mentoring students at his current position at MUSC. His research aims are to understand the role that intestinal fibroblast play in inflammation in the large intestine and has shown that intestinal fibroblasts can function as non-professional immune cells.

# Short Review of the Activity of the Macedonian Association of Anatomists

Pre-recorded – available all week

**Professor Dr Niki Matveeva, President of the MAA**



Review of the Macedonian Association of Anatomists, its members and activities as well as the projects that are performed in the Institute of Anatomy at the Faculty of Medicine in Skopje, University Ss Cyril and Methodius, the main founder of the MAA.

Professor Dr Niki Matveeva is President of the MAA Institute of Anatomy, Faculty of Medicine in Skopje, University Ss Cyril and Methodius, R. North Macedonia.

## **Biography:**

Niki Matveeva was born in 1961 in Skopje, capital of the Republic of North Macedonia, one of the successor states of former Yugoslavia. She is a graduate from the Faculty of Medicine, “Ss Cyril and Methodius” University in Skopje. Since 1988 has been employed at the Department of Anatomy at the Faculty of Medicine in Skopje and has lectured anatomy in the undergraduate and postgraduate studies for medical doctors at the Faculty of Medicine in Skopje. She has also participated in undergraduate and post-graduate study programmes at other universities and colleges (Faculty of Dental Medicine, Faculty of Pharmacy and Faculty of Physical Education, Sport and Health) members of “Ss. Cyril and Methodius” University. She completed doctoral studies and was promoted a doctor of science in 2005. Since 2018 has been full Professor at the Faculty of Medicine in Skopje. In 2016 was elected and became a President of the Macedonian Association of Anatomists. She has been included in a lot of scientific projects. Her research topics are human osteology, congenital developmental skeletal variations/malformations and spinal functional anatomy. She is an author and coauthor of 6 teaching books for anatomy for students of the Faculty of Medicine and the Faculty of Dental Medicine and for the students of the Three years Professional Studies for speech therapists. She is an author and coauthor of over 40 peer reviewed articles related to the primary topics of research.

She participated in Erasmus plus mobility programme for teaching staff in the Department of Anatomy at the Medical Faculty in the University of Split in Croatia. She has also participated in a variety symposiums, seminars (CHOP/ Salzburg Medical Seminars Pediatric Series “Medical Education”) and congresses within the country and abroad.

# Invited Talk

Pre-recorded – available all week

**Nirusha Lachman, PhD, Robert Morreale, MS**

## ***“Putting the Clinical Back into Anatomy and Anatomy Back into the Clinic”: A Reciprocal Model for Enhancing Education, Practice and Research***

Nirusha Lachman PhD and Robert Morreale MS The aim of this presentation is to share experiences from an evolving Department of Clinical Anatomy at Mayo Clinic. Efforts to realign anatomy within practice imperatives and shape the future direction of anatomy education within an experiential learning platform will be demonstrated. This talk will focus on (1) Clinician and Scientist engagement and collaboration, (2) Use of technology in a hybrid learning platform and (3) Evolving tools for developing anatomical competence.

### **Biographies:**



Nirusha Lachman, PhD

Nirusha Lachman, PhD is Full Professor and Chair of the Department of Clinical Anatomy, Mayo Clinic with joint appointment in the Department of Surgery, Division of Plastic Surgery at Mayo Clinic. Her primary focus lies in integrating patient centered anatomical knowledge for practice and research using anatomical data in translational approaches to close clinical practice gaps. Dr. Lachman’s main educational focus is built on Mayo Clinic’s BOLD FORWARD initiative of technological integration and advancement in driving new authentic anatomy curricula for practice-based learning. She is one of few clinical anatomists in the world who works collaboratively on a daily basis with clinicians in an active practice-based setting.

In her 28-year career as a clinical anatomist, Dr. Lachman has contributed over 111 scientific publications in peer reviewed journals, 20 book chapters and numerous abstract publications, editorials and national and international presentations. Dr Lachman’s leadership role extends to Mayo Clinic institutional committees, the Council of the American Association of Clinical Anatomists, and holds the position of Associate Editor of Anatomical Sciences Education Journal under the oversight of the American Association of Anatomists.



Robert Morreale, MS

Bob Morreale is a medical artist, creative thinker, educator, innovator, and administrative leader. Bob is passionate about how visual experiences are crafted to inform, educate, and empower patients, learners, and healthcare professionals alike.

As technological advancements began to race forward at the turn of the 21st century, Bob was at The Johns Hopkins University School of Medicine (JHU) in Baltimore, MD creating unique opportunities to leverage his creativity. Bob was at the forefront of JHU’s engagement with National Library of Medicine/ National Institutes of Health’s “*Next Generation Internet Initiative*” -- explored leading-edge information technologies in image annotation, visualization, collaboration, and networking to create the beginnings of the project “*The Visible Human Embryo*”.

After leaving JHU, and as a creative entrepreneur and owner of his own studio, Bob participated in several innovative initiatives with medical associations and publishers that explored utilizing visuals with evolving

Web technologies in unique ways. He would later take his passion for visualizing medicine to the classroom -- Bob was the Chair of the Graduate Medical Illustration Program at the Cleveland Institute of Art in Cleveland Ohio and participated in several adjunct projects at the Case Western Reserve University and The Cleveland Clinic.

The Association of Medical Illustrators (AMI) has recognized Bob as a Fellow and has been awarded its Outstanding Service Award; given to professional members whose actions or creations have had a significant positive impact on the profession of medical illustration.

Today, Bob is the Division Chair of Experiential Learning at Mayo Clinic and an Assistant Professor of Biomedical Communications in Mayo Clinic College of Medicine and Science.

# Welcome Reception

Monday, June 28th | 6:30 - 8:00 p.m.

Sponsored by



## ***Medicine Meets Museum: How the FWMSH Interprets Prehistoric Surgery***

Attendees will be welcomed by the Association President, Dr. Spinner, and addressed by our sponsor, Thieme. Following that, participants will hear from the Fort Worth Museum of Science and History on “Medicine Meets Museum: How the FWMSH Interprets Prehistoric Surgery”. Not only did the 1960s bring new advancements for modern medicine worldwide, but on a smaller note it defined a new wing of the Fort Worth Children’s Museum. The Hall of Medical Science debuted fall of 1965 with areas devoted to various cultures throughout history and their medical knowledge. Case #21 would be called the “Trepanning – The Primitive Art of Skull Surgery”. Through the years, the diorama would come to be fondly referred to, by many, as the “Cavemen doing brain surgery”. The museum drew inspiration from archaeological research in Peru and other burial sites with evidence suggesting brain surgery. Using the museum’s institutional history, we will explore how our Exhibits Team designed the new space and created a Neolithic surgical scene in the process.



# Themed Coffee Talk Descriptions (Open to all)

---

## Coffee Talk *Meet and Greet*

**Hosted by: The Diversity, Equity, and Inclusion Committee**  
**Wednesday, June 30th | 9:00 – 10:00 a.m.**  
**Open to All Attendees**

The Committee on Diversity, Equity, and Inclusion will be hosting a coffee talk from 9:00 a.m. - 10:00 a.m., on **Wednesday, June 30th**. During this session, attendees will have the opportunity to hear from committee members regarding upcoming initiatives and learn how to update their biographical information online.

---

## Coffee Talk

### *Promoting Equity and Inclusion through Anatomy: Working with Deaf and Hard of Hearing Patients and Students*

**Hosted by: Sarah Greene**  
**Thursday, July 1st | 9:00 – 10:00 a.m.**  
**Open to All Attendees**

We will be discussing the work of the Sub-Committee for Initiatives with the Deaf Community, which this year focused on educational opportunities for members to learn about American Sign Language, Deaf Culture and history, challenges in healthcare, communication, and how we can address health disparities in anatomy education. We will have a Deaf presenter joining us, Amy Cohen Efron, who has been instrumental in developing and implementing educational initiatives at Morehouse School of Medicine. Attendees will have an opportunity to discuss activities at their own institutions and how such educational opportunities can be developed at other institutions.

---

## Coffee Talk

### *Looking Forward: A preview of the 2022 Annual Meeting*

**Friday, July 2nd | 9:00 – 10:00 a.m.**  
**Open to All Attendees**

Rustin Reeves, PhD and Cara Fisher, PhD, UNT Health Science Center at Fort Worth, will host and answer general questions after Visit Fort Worth provides a short video and answers questions related to what Fort Worth has to offer.

# Committee Meeting Descriptions

(Open to all – not restricted to members of the committee)

---

## Anatomical Services Committee Lunch Meeting

Tuesday, June 29th | 12:00 – 1:45 p.m.

Open to all attendees

The Anatomical Services Committee meeting is a great place to learn about what ASC does and how you can get involved. We will be discussing ASC business and electing a new member of the committee. If you would like to be a member of ASC, or know someone who would, please come to the meeting and nominate them or be nominated!

Our meeting theme is “International COVID-19 Reflections from Body Donor Programs.” We have reached out to our international colleagues to present and discuss the current global pandemic for body donor programs and anatomy laboratories. For our “Lessons Learned” segment this year, Quenton Wessels from University of Namibia will present, “*Impact of COVID-19 on Anatomical Services in southern Africa.*” A presentation reflecting on the direct effects of the coronavirus pandemic in Africa. **Please review the presentation and submit your questions in advance.**

Our pre-recorded presentation will be followed by a very special Q<sup>2</sup> & A session where we will expand our discussion from Dr. Quenton Wessels with the addition of Dr. Quentin Fogg (President of the Australian and New Zealand Association of Clinical Anatomists), Dr. Albert van Schoor (President of the Anatomical Society of Southern Africa), and Dr. James Coey (AACA, Anatomical Services Committee). This event promises to be a very lively and diverse discussion, you won't want to miss it!

The ASC meeting is a perfect forum to “Ask an Expert”. This meeting is filled with experts on all aspects of body donation, from technical preparations to ethics, policies to PPE. Your colleagues bring years of experiences to the table, making our meeting a great place to find information and network. Committee member can always be reached by email if you have any concerns or questions throughout the year. We are even open to Zooming if you prefer.

Come to the ASC meeting to listen or to be part of the conversation by sharing your experiences. We hope to see you there!

Bobbi Morgan, Technical Co-Chair

Eileen Kalmar, Academic Co-Chair

### Quenton Wessels (MSc, PhD, MSc (Clin Ed), FHEA) Lecturer University of Namibia

I currently hold the position of Associate Professor at the Department of Anatomy, University of Namibia. I have experience in the philosophy and practice of pedagogy ranging from the principles of learning and teaching, educational management, assessment, and standard setting. My international experience in medical education was gained at Lancaster University between 2013 and 2016. This includes expertise on the GMC's guidelines on medical education with the emphasis on patient safety and quality of patient care. Broadly, my research interests rest within the anatomical sciences, its pedagogy and the historical aspects of anatomy and medicine. My research focus in medical education rests upon the facilitation and assessment of anatomical competence, as well as students' approaches towards the study of anatomy and their metacognition.



---

## Career Development Committee Lunch Meeting

Wednesday, June 30th | 12:00 – 1:45 p.m.

Open to all attendees

The CDC will host a lunch meeting building on the themes considered during the Mentor Reception to provide attendees the opportunity to discuss “How to Build Your Brand” and “How to Prioritize Your Roles”. In addition, we will be voting for a new member to join the CDC. AACA members with an interest in career development and mentorship can be nominated during the meeting. Interested attendees will access this lunch meeting via a single Zoom link. Once attendees are all in, a new CDC member vote will take place followed by a brief overview of the meeting agenda to be provided by CDC Committee members. The attendees will then be

assigned randomly to one of 2 Breakout rooms that take place simultaneously. Dr. Padma Gadepally ("How to Build Your Brand" topic) and Dr. Estomih Mtui ("How to Prioritize Your Roles" topic) will be moderating the two Breakout rooms separately.

At the conclusion of 20 minutes of initial sessions, the participants will stay where they are, but Dr. Mtui and Dr. Gadepally will switch places carrying with them their respective topics to be discussed between the breakout rooms participants for the next 20 minutes. Once both the breakout room sessions are completed discussing the two topics identified for this Lunch Meeting, the attendees will all be brought back for the concluding 25 minutes of wrap-up and take-home messages, which will be captured in a Google Doc to be shared at the end of the AACA conference.

---

## **Educational Affairs Committee Lunch Meeting**

**Thursday, July 1st | 12:00 – 1:45 p.m.**

**Open to all attendees**

The topic for the 2021 EAC lunch meeting is "Impact of COVID-19 on assessments in anatomy curriculum."

Assessments drive learning. The main purposes of assessments are to inform students about gaps in their knowledge and provide feedback to direct their future learning. During the EAC lunch session, participants will be introduced to various forms of assessments in anatomy followed by a facilitated open forum discussion. Participants will discuss and share modifications to their anatomy assessments during the COVID-19 pandemic.

At the end of the session participants will achieve the following objectives:

- Describe various adaptations to anatomy assessments during COVID-19
- Discuss the impact of these adaptations on student performance
- Reflect on lessons learned from assessment modifications during COVID-19

---

## **Clinical Anatomical Terminology Committee Lunch Meeting**

**Friday, July 2nd | 12:00 – 1:45 p.m.**

**Open to all attendees**

Please join the Clinical Anatomical Terminology (CAT) Committee for our virtual lunch meeting. Following an overview of the activities and outputs of the committee we will be running an entertaining (and of course educational) 'Pub-Style Quiz' based upon three anatomical terminology-related areas: pronunciations, plurals and etymology and eponyms. So, bring your 'A-game' and refreshments of your choice, and be prepared for a lively discussion.

Following the quiz, we will be holding elections for a new member at-large. Anyone interested in anatomical terminology is welcome to run.

The lunch is open to all members and we look forward to seeing you there.

# Committee Symposium Descriptions

(Open to all via Planstone)

---

## Clinical Anatomical Terminology Committee Symposium

Pre-recorded for viewing all week.

Please watch prior to attending the Q&A Session on  
Wednesday, June 30th at 2 PM Eastern.

Session Title: ***“Prone” to Misunderstanding: Technical Terminology, Language Evolution, and the Problem of People***

The terminology of highly technical fields can be fraught in unexpected ways. How do you maintain a terminological standard when language is always changing? (Surprise: language is always changing!) How does plain language interface with technical terminology in general, and who decides what constitutes “plain language”? When is upholding a terminological standard part of maintaining the cohesiveness of a field, and when is it nothing more than gatekeeping? Lexicographer and author Kory Stamper will discuss how language changes, where technical terminology sits compared to general terminology, and whether changing views of anatomy and the language of anatomy among the general public should (or shouldn't) impact technical terminology.



**Kory Stamper, BA**  
**Senior Project Editor for American English, Cambridge University Press**

Kory Stamper has been a lexicographer and editor for two decades and has grappled with everything from the meaning of “god” to the vagaries of “the.” Her writing on language, lexicography, and usage has appeared in *The New York Times*, *The Boston Globe*, *The Washington Post*, and in her best-selling book *Word by Word: The Secret Life of Dictionaries*. She currently works with Cambridge Dictionaries as a senior editor of *American English*.

---

# Career Development Committee Symposium

Pre-recorded for viewing all week.

Please watch prior to attending the Q&A Session on  
Wednesday, June 30th at 2 PM Eastern.

Session Title: ***Promotion in Medical Education***



**Adam Wilson, PhD**  
Rush University

Title of Presentation: ***A Review of U.S. Medical Schools' Promotion Standards for Excellence in Education***

**Biography:** Adam Wilson is an Associate Professor at Rush University in Chicago where he serves as the Director of Anatomy Education and is a course director for the medical preclerkship curriculum. He has taught numerous learner populations in the medical and allied health fields. Dr. Wilson holds a doctoral minor in education and conducts research related to the field of educational measurement and evaluation.



**William J. Schwartz, MD**  
Dell Medical School and The University of Texas at Austin

Title of Presentation: ***Unsolicited Advice on Academic Promotion***


**Biography:** William J. Schwartz is currently Assistant Dean for Faculty Affairs and Professor of Neurology in the Dell Medical School, and Professor of Integrative Biology in the College of Natural Sciences, at The University of Texas at Austin. He completed his M.D. degree and neurology residency at the University of California San Francisco, a research fellowship at the National Institute of Mental Health, and was on the faculties of Harvard Medical School, Massachusetts General Hospital, and University of Massachusetts Medical School before his current position.

# Mentorship Reception

**Tuesday, June 29 | 6:00 – 7:30 p.m.**

The Career Development Committee (CDC) of the AACA focuses on mentor-mentee relationships and career development. We will have 3 separate events at this year's virtual meeting that will focus on promotion. First, the CDC will provide links to two pre-recorded talks on "A Review of U.S. Medical Schools' Promotion Standards for Excellence in Education" by Adam Wilson PhD and "Unsolicited Advice on Academic Promotion" by William Schwartz MD. If possible, please view these pre-recorded talks early in the week to make the most of the CDC sessions. Second, the CDC will host a mentor reception with the opportunity to hear from two seasoned experts on education and clinical related themes with respect to promotion. And third, the CDC will host a lunch meeting to provide attendees the opportunity to discuss "How to Build Your Brand" and "Which role should I emphasize: Research, Teaching, Service?". In addition, we will be voting for a new member to join the CDC. Anyone with an interest in career development and mentorship can be nominated during the meeting.





American  
Association  
of Clinical  
Anatomists

# Annual Business Meeting

Agenda

Thursday, July 1, 2021

Virtually Held - Via Zoom

PO Box 2945  
LaGrange, Ga 30241  
Ph: 706-298-0287

[www.clinical-anatomy.org](http://www.clinical-anatomy.org)


**CALL TO ORDER: 3:00 pm**

Approval of Minutes of 2020 Annual Business Meeting (ABM) and the 2021 ABM Agenda

- 1. President's Report – Robert Spinner – 10 minutes**
  - a. 2021 Election Results
  - b. 2022 Election – Positions open to the AACA Membership in 2022
    - a. President-elect (1)
    - b. Treasurer (1)
    - c. Special councilor – Clinical (1)
    - d. Councilors-at-large (2)
  - c. Presidential Committee Appointments
  - d. State of the Association
- 2. Treasurer's Report – Anthony D'Antoni – 5 minutes**
- 3. Membership Committee Report – Thomas Gest – 5 minutes**
  - a. Remembrance of Deceased Members – Sarah Greene – 1 minute
- 4. Journal Committee Report – Marios Loukas – 2 minutes**
  - a. Report of Editor-in-Chief of *Clinical Anatomy* – R. Shane Tubbs – 7 minutes
- 5. Meeting Organization & Program Planning Committee Report – Jennifer Burgoon – 10 minutes**
  - a. Report of 2021 Annual Meeting Committee
  - b. Future Meetings:
    - 2022 AACA Annual Meeting, Fort Worth, TX. – Rusty Reeves
    - 2023 AACA Annual Meeting, Orlando, FL
    - 2024 AACA Annual Meeting, New York, NY – Estomih Mtui
    - 2025 AACA Annual Meeting, Seattle, WA – Shane Tubbs
- 6. Committee Elections<sup>1</sup> – Robert Spinner – 15 minutes**
  - a. Election of Members-at-Large for Nominating: 3 vacancies
  - b. Bylaws Committee: 2 vacancies
  - c. Financial Affairs Committee: 1 vacancy
- 7. Annual AACA Awards – Robert Spinner -5 minutes**
  - a. Honored Member Award 2021 – Susan Standing
  - b. R. Benton Adkins Service Award – Fiona Stewart
- 8. Old Business – 2 minutes**
- 9. New Business – 3 minutes**

**ADJOURNMENT: 4:00pm**

<sup>1</sup> The Special Interest Group (SIG) Committees (Educational Affairs, Career Development, Clinical Anatomical Terminology, and Anatomical Services) elects members at their committee meetings.



**CALL TO ORDER: 3:00 pm**

Approval of Minutes of 2019 Annual Business Meeting (ABM) and the 2020 ABM Agenda

**1. President's Report – Rob Spinner – AACA President**

**e. 2020 Election Results**

Rob announced the winners of the 2020 AACA election.  
Sarah Green is the new Association Secretary  
Gilbert Willett is the new Special Councilor - Allied Health  
Vaughan Lee and Kazzara Raeburn are our new Councilors-at-Large

**f. 2021 Election – Positions open to the AACA Membership in 2020**

President-elect (1)  
Special councilor – Anatomical Services (1)  
Councilors-at-large (2)

**g. Presidential Committee Appointments**

Rob updated the membership regarding the committee appointments and elections.

**Anatomical Services Committee**

**Anatomical Services Councilor, ex officio**

Ex Officio: James Coey

**Presidential Appointees**

2018-2021: Bobbi Morgan, **Technical Chair**

2019-2022: Eileen Kalmar, **Academic Chair**

2020-2023: Nirusha Lachman

**Members Elected at Annual SIG Meeting of Committee**

2018-2021: Scott Barton

2019-2022: Kelsey Byers

2020-2023: Amanda Collins

**Bylaws Committee**

**Presidential Appointees (2020-2022)**

Kathleen Bubb, Chair

Mathangi Gilkes

Ameed Raof

**Elected Members-at-Large (2020-2021) - One year term**

Two members to be elected during business meeting

**Career Development Committee**

**Presidential Appointees**

**2018-2021: Estomih Mtui**

**2019-2022: Kirsten Moisio**

**2020-2023: Quentin Fogg**

**Members Elected at Annual SIG Meeting of Committee**

2018-2021: Eiman Abdel Meguid

2019-2022: Adam Wilson

2020-2023: Padma Gadepally

**Clinical Anatomy Terminology Committee**

**Clinical Councilor, ex officio**

Koichi Watanabe

**Presidential Appointees**

*continued on next page*

2018-2021: Paul Gobe  
2018-2021: Evan Goldman, **Chair**  
2019-2022: Brad Martin  
2019-2022: Ian Whitmore  
2020-2023: Chelsea Lohman-Bonfiglio, Co-chair  
2020-2023: Richard Tunstall

**Members-at-Large**

2018-2021: Noel Boaz  
2018-2021: Amy Mork  
2019-2022: Efrain Miranda  
2019-2022: Sara Sulaiman  
2020-2023: Anthony Weinhaus  
2020-2023: Alexandra Wink

**Educational Affairs Committee**

**Presidential Appointees**

2018-2021: Priti Mishall, **Chair**  
2019-2022: Lela Giannaris  
2020-2023: Dolgor Baatar

**Members-at-Large Elected at Annual SIG Meeting of Committee**

2018-2021: Saskia Richter  
2019-2022: Krista Johansen  
2020-2023: Haley Nation

**Financial Affairs Committee**

**Treasurer *ex officio*, Chair (non-voting)**

Anthony D'Antoni

**Presidential Appointees (2020-2023)**

Beom Sun Chung  
Lonie Salskowski

**Elected Member-at-Large (2020-2021) - One year term**

One member to be elected during business meeting

**Journal Committee**

**AACA Past President, *ex officio*, Chair**

Marios Loukas

**AACA President**

Robert Spinner

**AACA Treasurer**

Anthony D'Antoni

**BACA President, *ex officio*, Vice-Chair**

Peter Dangerfield

**Publisher's Representative (non-voting)**

Jinnie Kim - Wiley

**Editor-in-Chief *ex officio* (non-voting member)**

Shane Tubbs

**Presidential Appointee (2020-2023)**

Kazzara Raeburn (KRaeburn1@sgu.edu)

**Membership Committee**

**President-Elect, *ex officio*, Chair**

Tom Gest

**Past President, *ex officio***

Marios Loukas

**Presidential Appointee (2019-2021)**

Rachael George

**Presidential Appointee (2020-2022)**

Jim Foster

**Nominating Committee**

**Presidential Appointees (2020-2021)**

Anthony D'Antoni, **Chair**

Jorge Lazareff

**Elected Members-at-Large (2020-2021)**

Three members to be elected during business meeting.

*continued on next page*

## **h. State of the Association**

We had a great deal of momentum after the Tulsa meeting and we aligned the interim council meeting and regional meeting in Oakland, CA. This worked out very nicely.

Obviously, the COVID pandemic has derailed the finer points of many of our plans. Thankfully our decision to cancel the in-person meeting turned out to be the correct course of action and we were able to extricate ourselves from the hotel and other commitments with a minimum of financial trouble. Tremendous thanks are due to ASG for their efforts. We have adapted to the new circumstances admirably and the MOPP committee, Jennifer Burgoon, and ASG have created this virtual meeting with phenomenal efforts.

In addition to the COVID pandemic, recent events have highlighted the ongoing pandemic of racism. The AACA has put out a statement explicitly condemning racism and we hope that our organization can contribute to the equitable resolution of this crisis.

Rob has noticed that joy and positivity have begun to re-emerge in interactions with colleagues and that some benefits of our “cocooning” have begun to emerge. Completion of lingering projects, learning new skills, and embracing creative efforts have all been noted at his institution and he believes that similar growth and innovation will be coming from the AACA as well.

Rob would like us to contemplate how we can harness this creativity to put the “clinical” back in Clinical Anatomy. The invited speakers at the New York meeting would have discussed the history of transplant surgery and its deep links to clinical anatomy. We will also look for ways to showcase the efforts of the other speaker who has transitioned from artist to administrator and how this sort of shift allows for new and exciting interactions between colleagues. Looking toward the future, we should support and expand departments of clinical anatomy, making efforts like those of Nirusha Lachman at Mayo. These topics will be explored in the next annual meeting in Seattle in 2021. The social aspect of the annual meeting will be a challenge but this will undoubtedly be a venue we can explore to improve these sorts of virtual events.

The 2020 virtual meeting had 404 registrants with 254 members and 150 guests.

Rob thanked Tom and Marios for their support and help in carrying out the duties of the president. Nirusha thanked Rob for his push to keep clinicians and anatomists connected in their teaching and research.

### **2. Treasurer’s Report – Anthony D’Antoni**

We have not lost money in the past year despite the financial disruption caused by the pandemic. The majority of our funds are in the investment account with a significant amount in the checking account and some small funds in other accounts. We are not making money with registration for the virtual meeting but we are not losing money due to hotel contracts and travel reimbursement being cancelled. We received \$2000 in donations during registration.

### **3. Membership Committee Report – Tom Gest**

While membership in some areas has increased, regular membership numbers are slightly down in 2020 compared to 2019.

Affiliate members from 2019-2020: 5 to 9

Associate members: 97 to 115

Regular members: 445 to 377

Senior members: 17 to 19

Honored members: 2 to 18

Total: 566 to 538

For the last 6 years, we have had an average of 39 members join or renew during the last 3 months of the year, so we may be back to 2019 levels before 2021.

#### **b. Remembrance of Deceased Members – Peter Ward**

The membership recognized the members who have passed away during the last year:

Keith Moore, MSc, PhD, DSc, FIAC, FRSM, FAAA

### **4. Journal Committee Report – Marios Loukas**

#### **Report of Editor-in-Chief of *Clinical Anatomy* – R. Shane Tubbs**

*Clinical Anatomy* has had a banner year. The sources of our submissions continue to be diverse: USA, China, Turkey, India, and South Korea are in the top 5. Over 2,200 reviewer invitations were sent this year. We had a massive uptick in the number of article downloads to above 350,000. This puts us into a very good position with Wiley. Our impact factor for 2018 was 1.813 and the impact factor for 2019 is 1.967. Shane highlighted some upcoming papers of interest.

*continued on next page*

**5. Meeting Organization & Program Planning Committee Report**–*Jennifer Burgoon*

**c. Report of 2020 Annual Meeting Committee**

The MOOP continued customizing the Planstone software, improved submission guidelines, reviewer guidelines, and the post-conference survey. During submission of abstracts they screened for IRB approval. The committee had to shift from planning the in-person meeting in New York to the new virtual method, featuring ePosters and ePlatform presentations delivered via Planstone. Submissions to the 2020 virtual meeting were considerable greater in number than in 2019.

Initial abstracts submitted in 2019 and 2020: 97 to 141

Late-breaking submissions: 11 to 15

Registrants: 290 to 399 (as of this morning)

Platform presentations: 20 to 22

**d. Future Meetings:**

Jennifer thanked the New York hosts, Estomih Mtui, Anthony D’Antoni, and the Weil Cornell School of Medicine for their efforts despite the disruption of the pandemic. The committee chairs, meeting managers, and ASG pulled a high-quality, virtual conference together in short order. She then highlighted our upcoming meetings.

- Oct 3<sup>rd</sup> – AACA/HAPS Fall Regional Meeting. Hosted by University of Massachusetts Medical School – meeting will be held virtually – *Lela Giannaris* and *Jon Wisco*
- 2021 AACA Annual Meeting, Seattle, WA. – *Shane Tubbs*
- 2022 AACA Annual Meeting, Fort Worth, TX. – *Rusty Reeves*
- 2023 AACA Annual Meeting, Orlando, FL (tentative)
- 2024 AACA Annual Meeting, New York, NY (tentative)

Jennifer concluded by welcoming members to email her if they are interested in hosting a regional or national meeting and to fill out their post-conference survey.

**6. Committee Elections**<sup>1</sup>– *Rob Spinner*

Rob updated the membership regarding the committee elections and we elected members to three committees during the business meeting.

d. Election of Members-at-Large for Bylaws: 2 vacancies

e. Financial Affairs Committee: 1 vacancy

f. Nominating Committee: 3 vacancies

**Bylaws Committee**

**Elected Members-at-Large (2020-2021) - One year term**

Amy Amabile

Christina Lewis

**Financial Affairs Committee**

**Elected Member-at-Large (2020-2021) - One year term**

Jon Jackson

**Nominating Committee**

**Elected Members-at-Large (2020-2021)**

Estomih Mtui

Rebecca Pratt

Brandi Schmitt

**7. Annual AACA Awards** – *Rob Spinner*

Rob recognized our 2020 AACA Honored Member, Dr. Stephen Carmichael and the 2020 R. Benton Adkins Service Award Winner, Dr. Neil Norton

**8. Old Business**

None

**9. New Business**

Sarah Greene presented a short video highlighting the opportunities for incorporating sign language into the teaching and practice of clinical anatomy, along with possible outreach initiatives to the deaf and hard-of-hearing communities.

**ADJOURNMENT: 4:00pm**

<sup>1</sup> The Special Interest Group (SIG) Committees (Educational Affairs, Career Development, Clinical Anatomical Terminology, and Anatomical Services) elects members at their committee meetings.

# **2020-2021**

## **Officers of the AACA Council**

**President – Robert J. Spinner, M.D.**

**President-Elect – Thomas Gest, Ph.D.**

**Secretary – Sarah J. Greene, Ph.D.**

**Treasurer – Anthony V. D’Antoni, D.C., Ph.D.**

**Past-President – Marios Loukas, MD, Ph.D.**

**Program Secretary – Jennifer M. Burgoon, MS, Ph.D.**

### **Councilors**

James Coey

Joe Iwanaga

Nirusha Lachman, Ph.D.

Kazzara Raeburn, MD

Estomih P. Mtui, MD

Maria du Plessis, MS

Shane Tubbs, Ph.D.

Gilbert M. Willett, Ph.D., PT, OCS

Koichi Watanabe, MD, Ph.D.

# Clinical Anatomy

The Official Journal of the American Association of Clinical Anatomists, the British Association of Clinical Anatomists, the Australian and New Zealand Association of Clinical Anatomists, and the Anatomical Society of Southern Africa.

**Editor-in-Chief** – R. Shane Tubbs

**Editor Emeritus** – Stephen W. Carmichael

**AACA Senior Editor:** Robert J. Spinner

**AACA Co-Editors** – Anthony V. D’Antoni, Thomas R. Gest, Joe Iwanaga, Marios Loukas, Susan Standing

**BACA Editor** – Philip Addis

**Assistant BACA Editor** – Jenny Clancy

**ANZACA Editor** – Stephanie Woodley

**ASSA Editor** – Graham Louw

**Founding Editors:** Ralph Ger and Ray J. Scothorne

## Editorial Board - 2021 Associate Editors

Marwan F. Abu-Hijleh,  
Keiichi Akita  
Mahindra Kumar Anand  
Robert H. Anderson  
Nihal Apaydin  
Ronald L.A.W. Bleys  
Peter Dangerfield  
Raffaele De Caro  
Beom Sun Chung  
Aaron S. Dumont  
Fabrice Duparc  
Georgi P. Georgiev  
Jerzy Gielecki  
Duncan Lee Hamilton  
Mohammed Khalil  
Hee-Jin Kim  
Sanjib Kumar

Nirusha Lachman  
Chelsea M. Lohman Bonfiglio  
Vishy Mahadevan  
Tarik Massoud  
Joanna Matthan  
Stuart McDonald  
Ali Mirjalili  
Niladri Kumar Mahato  
Stanley Monkhouse  
Garrett Moore  
Shumpei Mori  
Martin M. Mortazavi  
Alan Moulton  
Bernard Moxham  
Horia Muresian  
Richard Newell  
Roelof-Jan Oostra

Friedrich Paulsen  
Michał Polgaj  
Elias Rizk  
Daisy Sahni  
José Ramón Sañudo  
Louise Scheuer  
Gulgun Sengul  
Thomas Shiozawa-Bayer  
Richard Tunstall  
Albert van Schoor  
Ivan Varga  
Jerzy Walocha  
Koichi Watanabe  
Peter L. T. Willan  
Bülent Yağcin  
Lukasz Olewnik

### Managing Editor:

Isaiah Tubbs  
me.clinicalanatomy@gmail.com

### Production Editor:

Reeni Sunder  
sreeni@wiley.com

# Committee Reports

Anatomical Services Committee  
Ad hoc Diversity Inclusion and Equity Committee  
Brand Promotion and Outreach Committee  
Career Development Committee  
Clinical Anatomical Terminology Committee  
Educational Affairs Committee  
Journal Committee  
Listserv Admin Report  
Membership Committee  
MOPP Committee  
Nominating Committee

---

## 2021 Anatomical Services Committee Report

The Anatomical Services Committee (ASC) represents academic and technical members of the Association who are active in the operations and administration of institutional whole body donation programs. ASC functions to serve the AACA membership by developing symposia, special sessions, courses, and guidance documents and promoting technical and academic aspects of human anatomical tissue use in healthcare, university education, and research. The group advocates for the informed, ethical, and safe operation of body donation programs in order to support the human anatomical tissue requests of students, faculty, staff, and researchers who contribute to the advancement of medicine through education and research. The ASC meets monthly to focus on topics relevant to the operation of body donation programs including current practices, compliance, ethics, public relations, and to plan future Association annual meeting activities.

### 2020-2021 ASC Highlights

- During our virtual meeting, we welcomed new member, Amanda Collins, to our committee and are thrilled to have Nirusha Lachman return to serve another term as the Presidential appointee.
- Review of the 2020 ASC meeting and planning for 2021 meeting.
- Sent a follow-up COVID survey to our membership and will present our result shortly.
- COVID related Best Practices will be posted as a New addition to the AACA website.
- No Submissions for the Anatomical Services Award were received. We are planning on advertising the award when the call for abstracts goes out in Spring of 2022.
- Submitted a 'Best Practice Guideline for Social Media Use in the Anatomy Lab'. We are waiting for Council's decision to post this information to our website.

Information about the ASC, including position statements, best practices, contact information, and links can be accessed from the Association website: <http://clinical-anatomy.org/Committees>

### Anatomical Services Committee events at the 2021 AACA Annual Meeting:

Members of the Anatomical Services Committee (ASC) will be present at the Welcome Reception on Monday, June 28, 6:30 to 8:30pm. AACA meeting attendees interested in anatomical services are encouraged to attend, meet the committee members, and learn what we do and how to get involved.

The Anatomical Services Committee Lunch Meeting will be held on Thursday, June 29, 12:00 pm to 1:45 pm.

Annually, our committee elects a new member from our at large AACA membership. Please submit your nomination to any ASC member in advance. Self-nominations are welcome if you are interested in running for our open ASC position.

The agenda for this year's meeting features our popular Lesson Learned session where real case studies in academic donation programs will be presented and Ask an Expert where questions concerning anatomical donation programs will be posed and advice solicited from AACA colleagues in attendance at the session. Other agenda items include a report on the work of the ASC during the last year and discussion of current topics, future meetings, and symposia. Active AACA members will also be electing a new ASC member. All meeting attendees are welcome! Details of the ASC meeting are at:

<http://clinical-anatomy.org/AnatomicalServicesCommitteeMeeting>.

The 2021 ASC Lessons Learned titled “Impact of COVID-19 on Anatomical Services in southern Africa” is presented by Quenton Wessels, from the University of Namibia, and will take place on Tuesday, June 29, 12:00 – 1:45pm. This presentation reflects on the direct effects of the coronavirus pandemic in Africa. Please review the presentation and submit your questions in advance. We will follow up with a very special Q2 & A session where we will expand our discussion from Dr. Quenton Wessels with the addition of Dr. Quentin Fogg (President of the Australian and New Zealand Association of Clinical Anatomists), Dr. Albert van Schoor (President of the Anatomical Society of Southern Africa), and Dr. James Coey (AACA, Anatomical Services Committee). This event promises to be a very lively and diverse discussion, you won't want to miss it!

The ASC meeting is a perfect forum to “Ask an Expert”. This meeting is filled with experts on all aspects of body donation, from technical preparations to ethics, policies to PPE. Your colleagues bring years of experiences to the table, making our meeting a great place to find information and network. Committee member can always be reached by email if you have any concerns or questions throughout the year. We are even open to Zooming if you prefer.

Come to the ASC meeting to listen or to be part of the conversation by sharing your experiences. We hope to see you there!

Bobbi Morgan, Technical Co-Chair

Eileen Kalmar, Academic Co-Chair

### **ASC Membership**

#### **Presidential Appointees:**

2018-2021: Bobbi Morgan, West Virginia School of Osteopathic Medicine, Technical Co-Chair [bmorgan@osteo.wvsom.edu](mailto:bmorgan@osteo.wvsom.edu)

2019-2022: Eileen Kalmar, Ohio State University, Academic Co-Chair [Eileen.kalmar@osumc.edu](mailto:Eileen.kalmar@osumc.edu)

2020-2023: Nirusha Lachman, Mayo Clinic College of Medicine [Lachman.nirusha@mayo.edu](mailto:Lachman.nirusha@mayo.edu)

#### **Elected Members:**

2018-2021: Scott Barton, University of California, [stbarton@ucsd.edu](mailto:stbarton@ucsd.edu)

2019-2022: Kelsey Byers, Indiana University, [ktbyers@iu.edu](mailto:ktbyers@iu.edu)

2020-2023: Amanda Collins, University of Massachusetts Medical School, [Amanda.Collins@umassmed.edu](mailto:Amanda.Collins@umassmed.edu)

Ex Officio:

James Coey, St. George's University - ASC Special Councilor, [jamescoey@me.com](mailto:jamescoey@me.com)

The anatomical services committee would like to thank all our exhibitors and we include a special thank you to our Welcome Reception sponsor the Thieme Group and our Awards Ceremony Sponsor Touch of Life Technologies.

---

## **Ad-Hoc Diversity, Equity, and Inclusion Committee (DEIComm)**

Members: Yasmin Carter (Chair), Chelsea Lohman Bonfiglio, Amanda Collins, Thomas R. Gest, Edgar R. Meyer, Haley L. Nation, Jonathan J. Wisco

Created in 2020, this was the inaugural year for the Ad-Hoc Diversity, Equity, and Inclusion Committee (DEIComm). This committee is charged by the AACA with promoting and fostering a culture that values diversity, equity, and inclusion in clinical anatomy.

The charges of this ad hoc committee are as follows:

1. Surveying and evaluating AACA membership, statements, and activities on issues affecting diversity, equity and inclusion in the clinical anatomy profession and
2. Identifying gaps and making recommendations to:
  1. Raise awareness and provide education on the importance of diversity and inclusion in the profession
  2. Promote outreach and mentorship
  3. Identify resources for training
  4. Support a forum for discussion on diversity and inclusion.

### *Current DEIComm Activities*

The committee met monthly to discuss the needs of the membership and future projects. In our first year, we were able to collaborate with the American Association for Anatomy (AAA), to create a 2-day symposium focused on the shortage of anatomists and the central role diversity plays in this shortage. We wrote the AACA Statement on Violence against Asian-American and Pacific Islander (AAPI) released in March 2021. We are currently working on new, more appropriate ways of surveying the membership to collect more accurate biographical information.

At the 2021 meeting we will be hosting a coffee talk to introduce association members to the goals of the committee and will provide a guided demonstration on the new online biographical information collector. In the next election cycle, we plan to move from an

ad-hoc to a full committee. The DEIComm will also be presenting an interactive poster at the 2021 AACA conference entitled “The Sum of Our Voices: Toward Achieving Diversity, Equity, and Inclusion in the AACA”.

#### *Sub-committee Work*

Sub-committee for Initiatives with the Deaf Community.

Members: Sarah Greene and Alexandra Wink

This year, the Sub-Committee focused on educational opportunities for society members to learn about American Sign Language (ASL), Deaf Culture and history, challenges in healthcare, communication, and how we can address health disparities in anatomy education. They are working on developing collaborations with Deaf and Hard of Hearing medical professionals to begin an initiative focusing on anatomical terminology in ASL.

---

## **Brand Promotion & Outreach Committee (BPOC)**

### **Members**

Soo Kim, University of Saskatchewan, Chair, soo.kim@usask.ca

Christina Lewis, Samuel Merritt University, Out-going Chair  
clewis@samuelmerritt.edu

Scott Barton, UC San Diego stbarton@health.ucsd.edu

Nena Mason, Rocky Vista University, nmason@rvu.edu

Mikaela Stiver, University of Toronto, mikaela.stiver@mail.utoronto.ca

Jessica Immonen, University of Nevada Las Vegas, jessica.immonen@unlv.edu

### **BPOC Bylaws**

The bylaws governing this *ad hoc* committee are as follows: The Brand Promotion and Outreach Committee (BPOC) is responsible for the promotion and maintenance of strategic initiatives of the AACA by:

- Providing oversight of regional meeting proposals and selecting hosts, in conjunction with the MOPP committee; and, providing logistical support in conjunction with the AACA’s professional management service
- Establishing a promotional and collaborative presence with other professional organizations with complementary missions (particularly those involved with initiatives related to clinical anatomy research and educational scholarship)
- Maintaining and updating the AACA website and social media outlets to reflect current events, connect members, and seamlessly tie the efforts of the standing committees together in order to unify the public presentation of the Association
- Soliciting information from the membership and monitoring current trends and emerging issues in the field of clinical anatomy to determine how AACA can best meet members’ needs; this information will be communicated with the standing Committees and Council
- Soliciting information from the membership regarding their perception of: events at the annual meeting, interface of the Society’s social media outlets, events that would benefit the Association in the future
- Interacting with media on behalf of the Association and directing inquiries to an appropriate member or member of Council
- Selectively promoting products or services offered by or endorsed by the Association
- Working with each of the standing committees to promote their initiatives to the public and other stakeholders
- Recommending further suggestions, as needed, to Council to improve promotion of AACA as a clinically oriented, scientific and educational scholarly institution.

### **Subcommittee Work**

During the 2020-2021 monthly BPOC meetings, we focused on creating and supporting several new initiatives. One new initiative was the creation of Clinical Anatomy Round Table (CART) sessions. The CART sessions are meant to help engage AACA members on a variety of topics and to facilitate discussions and connections outside of the annual meetings. On September 24, 2020, the AACA had its first CART session organized in collaboration with the Educational Affairs Committee (Theme: “Interactive Teaching Session: Lessons Learned”). On February 3, 2021, the AACA had its second CART session organized by the BPOC (Theme: “Lunch with Anne Agur”). Other new initiatives our committee has worked on include AACA video testimonials, t-shirt design contest for the annual meeting, and an AACA SWAG shop which will be launched soon.

The BPOC has continued to create promotional materials for various events throughout the year and grow our presence on social media platforms (current followers: Twitter >2600, Facebook >2150 and Linked in >450). We also continue to support regional meetings. On October 3, 2020, the AACA had our first joint regional meeting HAPS which was hosted by the University of Massachusetts School of Medicine, Worcester, MA (Theme was “Innovation and integration: Resources and relationships needed for a successful cross-disciplinary education.”). We had approximately 66 attendees from the AACA side, and over a 100 total. The BPOC also continues to raise funds to support student/post doc travel awards.

We thank everyone for their support! If you are interested in getting involved, ask how!

---

## Career Development Committee

The Career Development Committee (CDC) supports the career growth and advancement of clinical anatomy knowledge for an individual at any stage of their career. The CDC encourages high quality anatomical research and educational scholarship through responsibilities such as judging student posters (Sandy C. Marks, Jr. Award) platform presentations (Ralph Ger Award), and hosting the mentor reception at the annual meeting.

During the 2020-2021 monthly CDC meetings, committee members focused on planning for the CDC symposium, mentor reception, and lunch meeting. The overall theme for the CDC events this year is promotion. The objectives of these 3 events surrounding promotion are to:

- provide an overview of current promotion standards in medical education
- provide suggestions for academic promotion
- engage attendees in discussions centered around education, clinical, and research related themes and promotion

Please view the two pre-recorded talks for the CDC symposium in Planstone early in the week to take advantage of discussions throughout the conference.

If you are interested in serving, have a passion for mentoring, or have innovative ideas to promote career growth, please consider becoming a member of the CDC. We will be electing one new member at our virtual lunch meeting on Wednesday, June 30th from 12:00 pm- 1:45 pm (EST).

### Presidential Appointees

Estomih Mtui (epmtui@med.cornell.edu)

Kirsten Moasio (k-moasio@northwestern.edu)

Quentin Fogg (quentin.fogg@unimelb.edu.au)

### Members Elected at Annual SIG Meeting of Committee

Eiman Abdel-Meguid (e.abdel-meguid@qub.ac.uk)

Adam Wilson (adam\_wilson@rush.edu)

Padma Gadepally (gadepadm@isu.edu)

---

## Clinical Anatomical Terminology Committee

### Co-Chairs

Chelsea Lohman Bonfiglio (chelsea.lohmanbonfiglio@cuanschultz.edu)

Richard Tunstall (r.g.tunstall@warwick.ac.uk)

### Presidential Appointees

2018-2021: O. Paul Gobée (o.p.gobee@lumc.nl)

2018-2021: Evan Goldman, (Egoldman1@pennstatehealth.psu.edu)

2019-2022: Brad Martin (bdmartin@llu.edu)

2019-2022: Ian Whitmore (iwhitmore@argonet.co.uk)

2020-2023: Chelsea Lohman-Bonfiglio, Co-Chair (chelsea.lohmanbonfiglio@cuanschultz.edu)

2020-2023: Richard Tunstall, (Co-Chair) (r.g.tunstall@warwick.ac.uk)

### Members-at-Large

2018-2021: Amy Mork (amork@msm.edu)

2018-2021: Noel Boaz (nboaz@ehc.edu)

2019-2022: Efrain Miranda (dremiranda@gmail.com)

2019-2022: Sara Sulaiman (sara.sulaiman@bristol.ac.uk)

2020-2023: Anthony (Tony) Weinhaus (weinh001@umn.edu)

2020-2023: Alexandra Wink (alexandra.wink@umassmed.edu)

The CAT committee holds meetings on the 1st Wednesday of each month. Subcommittees meet on alternate weeks to the regular CAT meetings, or as needed. All CAT meetings are held using video conferencing using “Zoom”. The CAT has continued creating and reviewing definitions, based on the Patterns and Guidelines document. The definitions are created using CAT’s online “definition machine” (a web-based, database system hosted by LUMC, Netherlands). During 2020-2021, the CAT has worked on improving the

content of the AnatomicalTerms.info (ATI) website. The website formally houses the official Terminologia Anatomica terms and CAT-created plain language definitions. The CAT is currently working to fix any existing errors on the website with TA terms to ensure they are accurate and current. The CAT is currently working towards collaboration with the TA2viewer online to share our plain language definitions in their repository, and is working toward developing the capability of the definition machine. Finally, the CAT is working on increasing international awareness and recruit individuals for participation in the CAT initiatives (ATI/definition machine). To that end, the CAT is working on having a presence at a variety of conferences and working towards promoting ATI to journal and book editors as the recommended reference for authors.

At the 2021 virtual meeting, CAT's symposium will include guest speaker Kory Stamper, lexicographer and editor, and CAT's lunch meeting will include annual updates and a "pub-quiz" style activity.

---

## Educational Affairs Committee Report

Purpose of Committee: The Educational Affairs Committee (EAC) shall promote the teaching of clinical anatomy, track national and international curricular changes, and develop educational initiatives that will benefit the Association's members, health care professionals, the education community, and the general public. The Committee shall disseminate data and recommendations for best practices for all aspects of anatomical education as it relates to clinical practice. The Committee shall plan and implement the Educational Affairs Symposium when scheduled by the Meeting Oversight and Program Planning Committee. The Committee shall consist of six (6) members, each serving a three (3) year term. The President-Elect shall appoint one (1) member in the second year of his/her term, and the President shall appoint one (1) member in the first year of his/her term. One (1) member shall be nominated and elected by the Active Members in attendance at its annual open meeting.

During the 2020-2021 monthly EAC meetings, discussions focused on planning for the Clinical Anatomy Round Table (CART) event and EAC lunch meeting. The virtual CART event "Interactive Teaching Session: Lessons Learned" was scheduled on September 24, 2020. This was the first virtual CART event; it was very successful with participation of around 60 members. Participants actively engaged in small zoom breakout rooms to network with educators from around the globe and share the lessons learned from their recent teaching experiences during COVID-19.

Furthermore, EAC committee members, both past and present, collaborated to publish a review article in *Clinical Anatomy*: "[\*Integration of clinical anatomical sciences in medical education: Design, development and implementation strategies.\*](#)" Khalil MK, Giannaris EL, Lee V, Baatar D, Richter S, Johansen KS, Mishall PL. *Clin Anat.* 2021 Apr 27. doi: 10.1002/ca.23736. Online ahead of print. PMID: 33905130 Review.

During the 2021 virtual AACA conference, EAC will host a lunch meeting entitled: "Impact of COVID-19 on assessments in anatomy curriculum." We invite you to participate and share your experiences related to recent changes in your anatomy assessments. For those interested in getting more involved, during the lunch meeting on July 1st we will be electing a new member to the Educational Affairs Committee. Looking forward to seeing you!

### EAC Members:

#### Presidential Appointees 2018-2023:

2018-2021: Priti Mishall, Chair ([priti.mishall@einsteinmed.org](mailto:priti.mishall@einsteinmed.org))

2019-2022: Eustathia Lela Giannaris ([EustathiaLela.Giannaris@umassmed.edu](mailto:EustathiaLela.Giannaris@umassmed.edu))

2020-2023: Dolgor Baatar ([Dolgor.X.Baatar@kp.org](mailto:Dolgor.X.Baatar@kp.org))

#### Members-at-Large Elected at Annual SIG Meeting of Committee

2018-2021: Saskia Richter ([srichter@udel.edu](mailto:srichter@udel.edu))

2019-2022: Krista Johansen ([krista.johansen@tufts.edu](mailto:krista.johansen@tufts.edu))

2020-2023: Haley Nation ([Nation@uthscsa.edu](mailto:Nation@uthscsa.edu))

---

## Journal Committee Report

Committee Members: Robert Spinner, Marios Loukas, Anthony D'Antoni, Tom Gest, Jinnie Kim (Wiley editor), Phil Addis (ex officio; Editor BACA), Shane Tubbs (Editor-in-Chief), and Kazzara Raeburn (Presidential Appointee).

The Journal has continued to thrive this year with the most submissions in our history. The Journal is publishing very high quality articles from prestigious institutions from around the world." Our articles continue to have large numbers of downloads and citations. Please consider submitting your work to the Journal and continue to follow us online, in print, or on your mobile device with the *Clinical Anatomy* app for Android or iPhone users.

---

## Listserv Report

AACA's Education Issues Listserv was moved from the mail server at Einstein to being hosted on Google Groups in February of 2016. There are currently 1,130 subscribers to AACA's Listserv. From May 1, 2020 to April 1, 2021 there were 34 subjects posted. To the right of this report is a table of those posts that received the most responses.

### AACA Education List

Total Subscribers (as of 4/1/21) =

Activity 5/1/20 - 4/1/21 =

May 2020 – April 2021 Monthly Email Activity

May '20 = 7

June '20 = 7

July '20 = 1

August '20 = 3

September '20 = 3

October '20 = 3

November '20 = 1

December '20 = 0

January '21 = 6

February '21 = 2

March '21 = 0

April 1, '21 = 1

Most Commented upon Threads
Cleaning of anatomy towels in dissection lab (6)
Connecting Art and Anatomy in Italy - June 2021 - Registration Now Open! (6)
Maintaining cadaver moisture (3)
Virtual Anatomy Survey – Update (3)
Laboratory barriers for COVID protection (3)
Anatomy Lab Remote Teaching (3)

**Total Emails = 34**

**Total Replies = 35**

---

## Membership Committee Report

President-Elect – Thomas Gest

(2017 – 2021) Past President – Marios Loukas

(2019 – 2021) Presidential Appointee – Rachael George

(2020 – 2022) Presidential Appointee – James Foster

The membership committee is pleased to state that the following new members have joined AACA from July 25, 2020 to April 1, 2021. The total number of active members in the association is 549.

### AFFILIATE

### ASSOCIATE PRINT COPY

### ASSOCIATE POST-DOC ELECTRONIC

Ahmad Albaghdadi, PhD

Ryan Hillmer

Natalie Kandinata

Karol Silla

### ASSOCIATE ELECTRONIC

Lauren Adams

Austin Alexander

Ashton Amos

Shreya Anand

Zubeen Azari

Madison Bagley

Connor Blythe

Emma Stefanie Campisi

Mackenzie Carroll

Jason Ciccotelli

Anastasia Filimonov

Cassandra Giner

Jared Hall

Tyler Hall

Stephanie Hayden

Zoe Henkes

Joseph Hong

Emily Kelly

Andrew Kleehammer

Chung Yoh Kim

Amy Lawton

Dustin Lin

Maurice Maglasang

Joey Marion

Myka Masters

Amanda Moorefield

Micaela Motzko

Ahmad Odeh

Ben Palleiko

Michael Peng

JonAngelo Perry

L. Ashton Porter

Dhanya Prasad

Austin Dwight Rodgers

Shelby Saenger

Dylan Salazar

Raissa Zuim Dantas de Souza

Alex Taylor

Charity Thomann

Rebecca Thomas

Brittany Walters

*continued on next page*

**REGULAR ELECTRONIC**

Abimbola Aiku  
 Maryna Al-Fauri  
 Husein Alghurairy  
 Hana Anderson  
 Cassandra Ang  
 Homaira Azim  
 Andrey Bilyy  
 Boris Boyanovsky  
 Tanya Cabrito  
 Linda Callahan  
 Kennedy Carpenter  
 Hurriyet Cetinok  
 Dragomir Dardanov

Jennifer Dennis  
 Richard Gonzalez  
 Vasavi Gorantla  
 Emma Handler  
 Georbrina Hargrove  
 Laurieanne Hemric  
 DeLoris Hesse  
 Ijeoma James-Okorie  
 Inga Kadisha (Kadish)  
 Walter Kolbinger  
 Judy Lau  
 Steven Lewis  
 Hector Lopez-Cardona  
 Roberto Lopez-Rosado

Janelle Mapes  
 Mansour Mathkour  
 Farida Mehrhoff  
 Geoffrey Meyer  
 Amy Lovejoy Mork  
 Satoru Muro  
 Anniesha Noel  
 Temitayo Olagbemi  
 Opeyemi Omosebi  
 Elio Plevneshi  
 Cheryl Purvis  
 Miguel Angel Reina  
 Deet Scott  
 Feimatta Sowa

Eleftherios Spartalis  
 Michelle Spear  
 Karen Stevens  
 Matt Stump  
 Grant Boxey  
 Shawn Callahan  
 Amanda Collins  
 Aaron Dumont  
 Ariel Gubatina  
 Tripti Jacob  
 Mario Loomis  
 Kristy McClellan  
 Michael Morris  
 Elise Orellana  
 Faustino Salcido  
 Kiran Kumari Singh  
 Robert Sturgeon  
 Williams Swartz

Krishna Thakore  
 Alison Thompson  
 Masahiro Tsutsumi  
 Edidiong Udoyen

Jennifer Weil  
 Sarah Williams  
 Darryn Willoughby  
 Lu Xu

Akihiro Yamashita

**REGULAR – PRINT**


---

## Meeting Organization & Program Planning (MOPP) Committee Annual Report, 2020-2021

**Members:****Special Interest Committees**

Anatomical Services Committee, Co-Chairs – Bobbi Morgan & Eileen Kalmar  
 Career Development Committee, Chair – Kirsten Moisia  
 Educational Affairs Committee, Chair – Priti Mishall  
 Clinical Anatomical Terminology Committee, Co-Chairs – Chelsea Lohman-Bonfiglio & Richard Tunstall

**Meeting Managers** (Formerly Known as Annual Meeting Committee Co-Chairs)

Yasmin Carter 2020-2021  
 Melissa Quinn 2021-2022

**Local Hosts**

Rusty Reeves & Cara Fisher – 2022  
 Estomih Mtui & Anthony D’Antoni – 2024  
 R. Shane Tubbs – 2025

**ASG Representatives** (Contracted Professional Organization Management Company)

Caitlin Hyatt, Executive Director

Jennifer Whitlow, Assistant Executive Director  
Kendra Tyner, Program Coordinator

### **Executive Committee**

Robert Spinner, President  
Thomas Gest, President Elect  
Marios Loukas, Past President  
Anthony D'Antoni, Treasurer  
Sarah Greene, Association Secretary  
Jennifer Burgoon, Program Secretary & MOPP Chair

This report is being filed on May 21, 2021. The information contained herein is the most accurate available as of this date. I am completing my third year of my 3-year term as Program Secretary, after serving a 2-year term as a Meeting Manager.

During the 2020-2021 year, the Meeting Organization and Program Planning (MOPP) Committee has again worked energetically to bring you a virtual meeting, specifically the 2021 American Association of Clinical Anatomist (AACA) Virtual Annual Scientific Conference. Planning began in earnest immediately following the 2020 Conference, the society's first virtual annual meeting ever, by a thorough review of the post-conference surveys. During the year, the MOPP Committee held conference calls during the second week each month. Asked to join us on the MOPP Committee calls this year was the Chair of the Brand Promotion and Outreach Committee, as this committee's tasks and endeavors often are tied to conference activities. While the initial plans were to hold the Conference in Seattle during Summer 2021, the AACA Executive Council made the decision in Autumn 2020 to cancel the in-person meeting due to the implications regarding the COVID-19 pandemic. While we deeply regret that we could not gather as an association in Seattle this summer, we look forward to gathering there in June 2025 with R. Shane Tubbs as our local host.

The 2021 AACA Virtual Annual Conference and the program you are reading are the direct result of the tireless effort of the MOPP Committee and through the exceptional professional support by ASG. Special thanks to Caitlin Hyatt, Kendra Tyner, Jennifer Whitlow, Melissa Quinn, and Yasmin Carter whose work behind the scenes on behalf of the MOPP Committee has made the 2021 AACA Annual Conference possible.

This year's meeting is certainly an energizing experience and one that we hope all attendees will enjoy. We have brought back many positive aspects of the 2020 Virtual Conference. For example, pre-recorded ePlatforms and ePoster presentations will be available in the virtual setting (i.e., Planstone). Again, attendees will be able to provide feedback for all ePlatform and ePoster presentations they view. It is our hope that this will offer a virtual forum for collegiality that is often experienced at the in-person Annual Meeting.

A major focus in this year's planning of the 2021 Virtual Conference, was the social, networking aspect that was lost at the 2020 Virtual Conference, as indicated in the post-conference surveys. As such, we have added a number of events to the 2021 Virtual Conference schedule to promote social interaction and networking, which includes Coffee Talks, Trivia Night, Banquet & Awards, Virtual Jewel Heist, and Teaching During Covid: An Open Dialogue.

Realizing the importance of the social interaction and networking, MOPP also worked on implementing activities to increase these aspects outside of the 2021 Virtual Conference including the inauguration of the Clinical Anatomy Round Table (CART) sessions with the different AACA committees involved.

### **Preliminary Planning for Future AACA Meetings**

One of my goals for the MOPP Committee is to have in place early the future AACA Annual Conferences. Thus far, we have been able to plan the following:

- 2022 Annual AACA Meeting to be held in Fort Worth, Texas June 13 – 17, 2022 and hosted by Rusty Reeves and Cara Fisher.
- 2023 Annual AACA Meeting to be held in Orlando, Florida July 9 – 12, 2023.
- 2024 Annual AACA Meeting to be held in New York, New York Dates TBD, 2024 and hosted by Estomih Mtui and Anthony D'Antoni.
- 2025 Annual AACA Meeting to be held in Seattle (Bellevue), Washington June 16 – 19, 2025 and hosted by R. Shane Tubbs.

If you are interested in hosting a regional and/or annual meeting, please contact me via email ([jennifer.burgoon@osumc.edu](mailto:jennifer.burgoon@osumc.edu)).

### **Abstract Submissions**

Each year, the MOPP Committee reviews all its documents, including the Abstract Submission Guidelines, in an effort to improve clarity. This year the General Review Criteria for the Level Two Content Reviewer was overhauled, including the questions asked of reviewers about each assigned abstract to be reviewed. The AACA works to accept completed, original, previously unpublished work that has IACUC and IRB approval, if applicable.

The table below shows the recent trends regarding abstracts, attendance, and presentations at our conferences:

Meeting Stats	2021 Virtual	2020 Virtual	2019 Tulsa	2018 Atlanta	2017 Minneapolis	2016 Oakland	2015 Vegas	2014 Orlando
---------------	-----------------	-----------------	---------------	-----------------	---------------------	-----------------	---------------	-----------------

Initial Abstract Subs	78	141	97	147	135	192	147	139
Returned for Format	73	15	16	13	10	32	51	20
Late-Breaking Subs	18	15	11	15	10	4	21	26
Total Rejections	9	6	3	2	1	23	24	10
Registrants	2181	437	290	350	345	350	338	327
Platform Presentations	12	27	20	24	16	18	22	29
Tech Fair Presentations	02	02	02	7	7	5	3	6
Publishable Posters	52	104	63	98	97	115	78	80
Non-Publishable Posters	17	19	11	29	22	26	43	40

<sup>1</sup>As registration for the 2021 AACA Annual Scientific Conference is ongoing, this number is as of May 21, 2021.

<sup>2</sup>No Tech Fairs were held during the 2019-2021 AACA Meeting as not enough abstracts were submitted to necessitate the session. Additionally, virtual meetings do not provide the hands-on opportunities the in-person meetings achieve, which are needed for this event to be successful.

In closing, please let the MOPP committee know of any improvements we can make to the conference through emailing those listed above and/or completing the post-conference survey. As always, we are striving to provide you with the best conference possible.

Respectfully Submitted on Behalf of the MOPP Committee,

Jennifer M. Burgoon

AACA Program Secretary

---

## Nominating Committee Report:

The Nominating Committee consists of presidential appointees Anthony D'Antoni (Chair) and Jorge Lazareff, and elected members-at-large Estomih Mtui, Rebecca Pratt, and Brandi Schmitt. On January 27th, 2021 the Committee met for the first time on a conference call, the main aim of the discussion was to nominate a diverse group of candidates from members who are active within the association. The slate of candidates finalized in February and forwarded to Sarah Greene, the Association Secretary. Prior to the submission of names, each candidate was contacted by a member of the nominating committee to get their acceptance of the nomination, and each candidate was directed to send a copy of their CV to the committee and to the association in care of Caitlin Hyatt, the Executive Director.

# Abstracts – ePlatform Presentations

## **\*Accepted for Publication in Clinical Anatomy (Listed by presenting author last name)**

\*ADAMS, Lauren, Annie G., ALLEN, Nicolas PACE, Tayva F. SONNEFELD, Austin HEO, A., Wayne JOHNSON, and Ulrike H. MITCHELL. Department of Exercise Science, Brigham Young University, Provo, UT, 84602, USA.  
Transversus Abdominis Muscle Size in Trained Collegiate Sprinters.

INTRODUCTION. The Transversus Abdominis muscle plays a significant role in core stability, deep breathing and trunk rotation. Proper core stability is vital to high performance. In a previous study, asymmetry between left and right sides of this muscle was noted in recreational joggers. The purpose of this study was to evaluate the morphology of the muscle and see if the asymmetry persists in collegiate sprinters who arguably use the Transversus Abdominis more for deeper breathing and increased trunk rotation. METHODS. 1 female and 4 male participants; age(years)= 20.6 +- 2.7 height(cm)= 183.8 +- 3.7; weight(kg) = 74.3 +- 5.8; volunteered for this study. With the participants in side-lying position and using a novel technique, a panoramic image of the Transversus Abdominis muscle was scanned using GE Logic-e 12MHz probe. The left and right Transversus Abdominis muscles were imaged twice on each subject at 3 different levels: immediately inferior to the rib cage, immediately superior to the iliac crest and midway between the two. Images were later measured for analysis. SUMMARY. As expected, our data showed a significant difference in length (rest= 12.4 +- 0.94cm; contracted= 11.5 +- 1.93cm; P<.001) and thickness (rest= 0.742 +- .019cm; contracted= 0.791 +- 0.024cm; P=.006) from rest to contracted state. However, our data did not show a presence of asymmetry among collegiate sprinters between left and right sides (Thickness: left=0.778 +- 0.019cm; right= 0.791 +- 0.024cm; P=0.374; Length: left= 12.1 +- 1.6cm; right=11.9 +- 1.7cm; P=.185). CONCLUSIONS. Trained collegiate sprinters exhibit a symmetric Transversus Abdominis between left and right sides. These results are dissimilar to data collected from recreational joggers. It appears intense training and use of the Transversus Abdominis eliminate any morphological differences between left and right sides.

\*BOAZ, Noel T. Laboratory of Biological Anthropology and Anatomy, Integrated Centers for Science and Medicine, Martinsville, VA, 24112, USA.

Onto-Phylogenetic Dissection of the Back: Anatomy with a Narrative.

INTRODUCTION. The back is a region that tends to lead off Gross Anatomy dissection courses, but paradoxically it is many times de-emphasized with little integration with other regions. In fact, the back dissection can provide a prime opportunity to teach foundational anatomical concepts via an onto-phylogenetic ('evo-devo') narrative thread that fosters development of critical-thinking, research, and diagnostic skills in clinical anatomy. RESOURCES. Soft-embalmed (Thiel-Method) cadavers are optimal for an evolutionary and developmental approach because their flexibility facilitates separation of structures along natural fascial planes. Structures that share homologous innervations and neurovascular supply can be more easily comprehended *en bloc* by blunt reflection of intact structures, whereas sharp dissection by arbitrary layers made necessary by inflexible formaldehyde-embalmed structures are not as permissive to this approach. Low-formaldehyde-embalmed cadavers may also be used if their preservation allows separation of tissue planes in such areas as the nuchal region (for complete dissection of the trapezius muscle), the plane between superficial and intermediate back muscles, and the planes between fibers of erector spinae and transversospinalis muscles. DESCRIPTION. Nine structural themes ('precepts') are used to organize the dissection: Notochord Homology, Neural Tube Homology, Somitic Homology, Sclerotome Resegmentation, Dermomyotomal Fusion, Neural Crest Cell Derivation, Cross-fibered Body Wall Musculature, Upper Limb Bud Homology, and Pharyngeal Apparatus Homology. SIGNIFICANCE. Presenting students with a nine-component 'tool box' with which they can construct a coherent scientific narrative for the structures that they will dissect in the back empowers them to supersede 'memorization without understanding' and approach other regions with increased understanding and ability to apply critical thinking to clinical problem-solving and research.

\*CARTER, Yasmin<sup>1</sup>, William S. BROOKS<sup>2</sup>, Adam B. WILSON<sup>3</sup>, Malli BARREMKALA<sup>4</sup>, and Loydie A. JEROME-MAJEWSKA<sup>5</sup>. <sup>1</sup>Division of Translational Anatomy, Department of Radiology, University of Massachusetts Medical School, Worcester, MA, 01602, USA; <sup>2</sup>Department of Cell, Developmental & Integrative Biology, University of Alabama at Birmingham, Birmingham, AL, 35294, USA; <sup>3</sup>Department of Cell and Molecular Medicine, Rush University, Chicago, IL, 60612, USA; <sup>4</sup>Department of Foundational Medical Studies, Oakland University William Beaumont School of Medicine, Rochester, MI, 48309, USA; <sup>5</sup>Department of Pediatrics, Human Genetics, and Anatomy and Cell Biology, McGill University, Montreal, QC, H4A 3J1, Canada.

Recommendations from the AAA/AACA Symposium on the Anatomist Shortage and the Role of Diversity.

INTRODUCTION. There is a known shortage of anatomists to fill current positions and this shortage is expected to carry into the future. Jointly, there is also a need to confront issues of diversity by expanding the multiplicity of anatomists including students, staff, and faculty. RESOURCES. To address these issues, a joint two-day think-tank supported by both the American Association for

*continued on next page*

## Abstracts - ePlatform Presentations continued

Anatomy (AAA) and the American Association of Clinical Anatomists (AACA) brought together a strategically sampled group of 30 thought leaders to brainstorm and prioritize solutions to these issues. Day 1 focused on the anatomist shortage and day 2 focused on the role of diversity, equity, and inclusion (DEI) in addressing the field's needs. DESCRIPTION. This symposium resulted in 10 recommendations. Group consensus revealed the need for increased inter-association collaborations and to create spaces for the collection and sharing of data related to the anatomist workforce and DEI. General themes that emerged throughout the symposium include the importance of association-level support in highlighting the value of anatomy faculty, support for membership through mentoring programs and shared curricular materials and improving the accessibility of annual meeting environments. The need for additional pipeline and doctoral training programs in anatomy was highlighted. The development of formalized curricula regarding DEI and our field's contribution to a history of bias was requested as well as collaboration between associations for outreach to historically underrepresented groups. SIGNIFICANCE. This work serves as a call to action. The recommendations of these symposia will be shared with both national organizations who will be called upon to lead significant change by improving member experiences and recruiting a new, diverse generation of anatomists from multiple sources. These deliverables will provide anatomists with the support, mentoring, and structure to succeed.

\*HUR, Mi-Sun<sup>1</sup>, Seunggyu LEE<sup>2</sup>, Tong Mook KANG<sup>3</sup>, and Chang-Seok OH<sup>4</sup>. <sup>1</sup>Department of Anatomy, Catholic Kwandong University College of Medicine, Gangneung, 25601, Korea; <sup>2</sup>Division of Applied Mathematical Sciences, Korea University, Sejong, 30019, Korea; <sup>3</sup>Department of Physiology, Sungkyunkwan University School of Medicine, Suwon, 16419, Korea; <sup>4</sup>Department of Anatomy and Cell Biology, Sungkyunkwan University School of Medicine, Suwon, 16419, Korea.

### Three Muscle Layers in the Pyloric Sphincter and Their Possible Function During Pyloric Motility.

INTRODUCTION. The present study was conducted to investigate the muscular arrangement of the pyloric sphincter, via a comprehensive approach involving micro-dissection, histology, and microcomputed tomography (micro CT) images. METHODS. Stomachs were obtained from 80 embalmed Korean adult cadavers. Six specimens were histologically analyzed using H & E and Masson's trichrome stain. Another twenty-two specimens were scanned using micro CT. SUMMARY. In all specimens (100%), the thin and loose muscular tissue at the innermost aspect of the muscular wall of the pyloric sphincter ran distally forming the newly-found inner longitudinal fibers, entered the duodenum, and then connected with the circular fibers nearby. In 100% of specimens, approximately one third of the outer longitudinal layer of the pyloric sphincter entered the inner circular layer. These fibers divided the circular layer into several parts and terminated with connecting with the circular fibers of the pyloric sphincter. Anatomical findings of the pyloric sphincter were also confirmed by micro-CT images. CONCLUSIONS. The muscular wall of the pyloric sphincter was composed of three layers: outer layer of longitudinal fibers, middle layer of major circular and minor longitudinal fibers, and inner layer of longitudinal fibers. The outer longitudinal fibers of stomach were connected to the circular fibers of the pyloric sphincter. And the inner longitudinal fibers of pyloric sphincter were connected to the circular fibers of the duodenum adjacent to the pyloric sphincter. These results are expected to advance the current understanding of antropyloroduodenal motility.

\*IWANAGA, Joe<sup>1</sup>, Satoshi TERADA<sup>2</sup>, Aaron S. DUMONT<sup>1</sup>, and R. Shane TUBBS<sup>1,3</sup>. <sup>1</sup>Department of Neurosurgery, Tulane University School of Medicine, New Orleans, LA, 70112, USA; <sup>2</sup>OCD Co., Ltd., Nihonbashi, Tokyo, 103-0026, Japan; <sup>3</sup>Department of Structural & Cellular Biology, Tulane University School of Medicine, New Orleans, LA, 70112, USA.

### Easy 3D Scanning Technology for Anatomy Education Using a Free Cell Phone App.

INTRODUCTION. The COVID-19 pandemic has brought difficult times to anatomy educators and medical/dental students. Gross anatomy classes usually give students opportunities to touch and observe human bones and cadaveric tissues for a better understanding as such morphology is often difficult to learn just from textbooks. However, as many studies have shown, three-dimensional (3D) technologies used in online lectures might alternate real specimens in terms of anatomy knowledge. However, such technologies are often expensive. Therefore, the goal of this study was to create three-dimensional anatomy for online lectures using a free cell phone app. METHODS. Free application software (Qlone) was used to create 3D anatomical models. The adult and fetal skulls, mandible, temporal bone, second cervical vertebra, ilium, external carotid artery and its branches, and thyroid gland were all scanned and exported to the computer in video (mp4) and 3D formats (USDZ) then compared with the photos of same objects. SUMMARY. Important anatomical structures, e.g., foramen ovale, jugular foramen, and the superior thyroid artery, were well captured and viewed on the scanned images. The structures could be observed from different views and angles. CONCLUSIONS. The free and easy 3D scanning app used in this study might enable anatomy educators to provide better anatomy content to students during online lectures.

## Abstracts - ePlatform Presentations continued

\*KALMAR, Eileen L.<sup>1</sup>, Megan ROSS<sup>2</sup>, and Rebecca ROMINE<sup>2</sup>. <sup>1</sup>Department of Biomedical Education and Anatomy, College of Medicine, The Ohio State University, Columbus, OH 43210, USA. <sup>2</sup>Division of Mathematics, Natural and Health Sciences, University of Hawai'i-West O'ahu, Kapolei, HI, USA.

### Under-Represented Minority Students in a STEM Course: Demographics Influence Success.

INTRODUCTION. Under-represented minority (URM) students enrolled in STEM degrees lag behind peers in STEM success and retention. STEM education is disproportionately provided to poor and/or ethnic minority students. Limited exposure to effective learning and activities in science often make it difficult for marginalized students to develop scientific knowledge and skills and envision themselves as a scientist. 90% of University of Hawaii - West O'ahu (UHWO) students identified as URM (non-Caucasian) and 30% as Native Hawaiian and Pacific Islander (NHPI), the least acknowledged ethnic groups among those recognized by the U.S. government agencies as underrepresented in STEM. The purpose of the study was to investigate factors that influence student success in an introductory level, Human Anatomy and Physiology I course. METHODS. 61 subjects (13 male and 48 female) were recruited for this study from three sections of an introductory level Human Anatomy & Physiology I course. Subjects were disaggregated by gender, level in school, prior science and math experience, geographic location, and ethnicity to discern academic performance differences. Averaged student performances (exam scores & final grades) were used to determine student success in achieving learning outcomes. SUMMARY. Significant differences were found within our URM, NHPI, and geographical location student groups ( $p < 0.05$ ). URM students (Pearson  $\chi^2$  (1,  $n=75$ ) = 0.048), NHPI students (Pearson  $\chi^2$  (1,  $n=75$ ) = 0.034), and geographic location (Pearson  $\chi^2$  (1,  $n=75$ ) = 0.033) were all found to have a statistically significant relationship with student success. CONCLUSIONS. Preliminary results indicated that although Native Hawaiian students are the universities' largest ethnic group, they are achieving success at a much lower rate than other groups on several measures including STEM course persistence. (Sponsored by National Science Foundation Award No. 1855379.)

\*MOOREFIELD, Amanda K.<sup>1</sup>, Anna STOCK<sup>1</sup>, Zak ROSE-RENEAU<sup>1</sup>, Barth WRIGHT<sup>1</sup>, and Virender SINGHAL<sup>2</sup>. <sup>1</sup>Division of Clinical Anatomy, Kansas City University, Kansas City, MO, 64106, USA; <sup>2</sup>Private Practice, Singhal Plastic Surgery, Kansas City, MO, 64158, USA.

### Anatomical Considerations in Male Chest Contour: Implications for Gender-Affirming Top Surgery.

INTRODUCTION. Masculinizing chest reconstruction is the most common gender-affirming surgery in transgender males. Despite the current literature's acknowledgement of the vital role that proper placement of the nipple-areola complex (NAC) plays in a masculine chest contour, there is still much debate regarding the best anatomical landmarks to achieve the desired result. The primary aim of this study is to determine landmarks for NAC placement that can be universally applied and aid surgeons in creating a masculine chest across diverse body types. METHODS. A cadaveric study of twenty-five formaldehyde embalmed male cadavers was performed with evaluation of each side of the chest separately for a total sample size of 50 NACs. Measurements were taken of the NAC, nipple, and surrounding bony and muscular landmarks to identify the most consistent variables for proper NAC localization. Linear regression analyses were conducted to determine how distance from the nipple to respective landmarks varied based on body mass index (BMI), height, weight and age. SUMMARY. The measurements for the inferior and lateral borders of the pectoralis major muscle (PMM) displayed the least amount of variance of all the anatomical landmarks studied. Additionally, there was no significant change in these pectoral measurements with varying BMI, height, weight or age, indicating that these measurements are reliable landmarks for NAC placement across various body types. The average NAC placement in relation to the inferior and lateral borders of PMM were 2.6 cm and 2.1 cm, respectively. Additionally, the angle of Louis, sternal notch, and medial PMM measurements are good landmarks for ensuring symmetry of NAC localization on each side of the chest wall, due to their relative low variance as well. The most common NAC shape was horizontal oval (width>height) with the nipple falling within intercostal space 4 (ICS 4). CONCLUSIONS. Based on our cadaveric analysis, aesthetically pleasing masculine chest results can be produced consistently across varying body types when adhering to a simple pectoral approach in NAC placement.

\*MOTZKO, Micaela R., Brandalynn HOLLAND, Edwin GLUECK, Anna STOCK, Zubeen AZARI, and Melissa ZOLNIERZ. Kansas City University, Joplin, MO, 64804, USA.

### Cadaveric Study of the Pectineal Ligament: Tensile Strength and Relationship to Vascular Structures.

INTRODUCTION. The sacral anterior longitudinal ligament is currently the preferred anchoring ligament for pelvic organ prolapse (POP) in a sacrocolpopexy procedure. However, literature has shown that recurrence rate of POP as well as complications due to a narrowing of the pelvis is relatively high using this procedure. An alternative approach, the pectopexy procedure, utilizes the pectineal ligament, which is more conveniently located and potentially stronger than the anterior longitudinal ligament. Comparing the tensile strengths of the anterior longitudinal and pectineal ligaments will provide insight into the utility of these ligaments as anchoring points for POP repair. METHODS. In 22 female formalin-embalmed cadavers, the abdominal cavity was entered using standard

*continued on next page*

## Abstracts - ePlatform Presentations continued

dissection techniques. Once exposed, measurements between the external iliac vessels and the midpoint of the bilateral pectineal ligaments were recorded. Bilateral length and width measurements of the pectineal ligaments were recorded prior to removing them with a scalpel. The sacral anterior longitudinal ligament was harvested, along with one sacrospinous ligament from each cadaver to serve as an external control regarding pelvic ligament tensile strength. A portable mechanical properties tester by Lucas Scientific was used to measure tensile strength of the above ligaments. The strength at failure for each ligament was measured and compared statistically using SPSS. SUMMARY. The pectineal ligament as used in the pectopexy procedure has the potential to be a stronger and more reliable anchor than the sacral anterior longitudinal ligament as used in the sacrocolpopexy. The documented tensile strength of the pectineal ligament compared to the anterior longitudinal ligament provides support for the utility of the pectopexy procedure for recurrent POP. Additionally, the location of the pectineal ligament as used in the pectopexy procedure provides an anchor point for apical vaginal support without narrowing the pelvic outlet. CONCLUSIONS. The pectineal ligament has shown to be a strong ligament and a secure anchor point that has substantial potential in many gynecologic surgeries for pelvic organ prolapse, such as the pectopexy procedure.

\*NGUYEN, Vuvi H.<sup>1</sup> and Shayla D. YOACHIM<sup>2</sup>. <sup>1</sup>Department of Diagnostic and Biomedical Sciences, The University of Texas School of Dentistry, Houston, TX, 77054, USA; <sup>2</sup>Department of Oral Biology, The University of Nebraska Medical Center College of Dentistry, Lincoln, NE, 68583, USA.

### Using Instagram as a Tool to Enhance Anatomy Learning at Two U.S. Dental Schools.

INTRODUCTION. Although growing evidence supports the inclusion of social media in education, no studies to date have investigated the potential role of Instagram in anatomy education. The purpose of this study is to assess dental students' perspectives on the advantages and challenges of using Instagram as a supplement to their anatomy learning at two U.S. dental schools. METHODS. Anatomists at The University of Texas School of Dentistry (UTSD) and The University of Nebraska Medical Center (UNMC) College of Dentistry created unique Instagram pages supplemental to traditional pedagogy, aiming to provide easily accessible, interactive content for our tech-savvy students. In the fall of 2020, 170 students (86 from UTSD and 84 from UNMC) voluntarily participated in an electronic survey via Qualtrics. All data were analyzed using descriptive statistics and Fisher's exact test. SUMMARY. Most respondents (85.1%) had seven or more years of experience with social media, and 96.9% of students reported using social media as a source of information with 92.5% using for educational purposes. All students agreed that their respective professor's page has been helpful for anatomy study and review, added to their understanding of anatomy, is convenient, engaging, and professional. While consistent themes emerged between cohorts, UNMC students had a higher level of agreement regarding their page's added relevance to learning in the class/clinic ( $p=0.0016$ ), while UTSD students reported feeling more comfortable asking their professor questions through Instagram ( $p=0.015$ ). CONCLUSION. The majority of students at both dental institutions agreed that Instagram was a useful educational tool that could help reinforce content learned and engage them outside of class. This image-based social media platform has potential in anatomy education to both support educator's traditional pedagogy and supplement content delivery in unforeseen circumstances such as the COVID-19 pandemic.

\*SUÁREZ-QUIAN, Carlos A.<sup>1</sup>, and Joel A. VILENSKY<sup>2</sup>. <sup>1</sup>Department of Biochemistry, Georgetown University School of Medicine, Washington, DC, 20057, USA; <sup>2</sup>Department of Occupational Therapy, Huntington University, Fort Wayne, IN, 46805, USA.

### Head and Neck Structures Displayed by the Anatomage Table: An Accuracy Assessment.

INTRODUCTION. The Anatomage Virtual Dissection Table is increasingly being used to supplement and/or replace cadaver dissection; however, no prior study has yet assessed the accuracy of the anatomy presented by the Table as an indicator of whether the Table is a suitable replacement for cadaver dissection. RESOURCES. A listing of head and neck structures commonly identified in a classic dissection course was generated and those structures identified in the Asian male and female cadavers available on the Anatomage Table (v.7). DESCRIPTION. Nerves were all depicted as smaller than their actual size and were often inaccurate in their paths. For example, the frontal nerve in the male cadaver is not shown correctly traversing the superior surface of the levator palpebrae, and fails to show continuity with the supraorbital and supratrochlear nerves. The nerve's depiction and its continuity with the supraorbital and supratrochlear nerves are better in the female cadaver, but in neither can the nerve be shown in continuity with the ophthalmic division of V1. Arteries were also typically undersized and sometimes in error; e.g., the common carotid artery is shown to be some distance from the internal jugular vein, when they are, in reality, directly adjacent to each other enveloped within the carotid sheath. Further, the carotid bulb is not evident in either Anatomage cadaver. A large number of important anatomical structures are not depicted or labeled for these cadavers: e.g., parotid and submandibular ducts, vestibular folds, valleculae, lacrimal sac and duct, superior and middle conchae and meati. Bones and muscles were very accurately presented in the Table. SIGNIFICANCE. The Anatomage Table provides a useful resource for learning anatomy especially because students enjoy working with others on the Table. However, in its current form and due to the many inaccuracies, the Table should not be considered a replacement for cadaver dissection.

*continued on next page*

## Abstracts - ePlatform Presentations continued

\*TRAN, John<sup>1</sup>, Loretta HO<sup>2</sup>, Philip W.H. PENG<sup>2</sup>, and Anne M.R. AGUR<sup>1</sup>. <sup>1</sup>Division of Anatomy, Department of Surgery, Temerty Faculty of Medicine, University of Toronto, Toronto, ON, M5S 1A8, Canada; <sup>2</sup>Department of Anesthesiology and Pain Medicine, Toronto Western Hospital, University Health Network, Toronto, ON, M5T 2S8, Canada.

### Cadaveric Study of the Nerve Supply to the Wrist Joint.

INTRODUCTION. In 2011, over 11 million Americans reported chronic wrist joint pain. Joint pain and stiffness are most commonly caused by osteoarthritis and traumatic injuries. Patients with moderate-to-severe symptoms are considered for wrist arthrodesis which significantly impairs range of motion (ROM). Ultrasound (US) guided radiofrequency denervation has emerged as an alternative to manage chronic wrist joint pain while preserving ROM. The effectiveness of wrist denervation protocols requires a detailed understanding of the innervation of the joint. Previous studies are scarce and have not related wrist innervation to anatomical landmarks visible with US. The purpose was to document the course of articular branches supplying the wrist joint in relation to relevant US landmarks. METHODS. Articular nerves innervating the distal radioulnar joint (DRUJ), radiocarpal joint (RCJ), and triangular fibrocartilage complex (TFCC) were meticulously dissected in 5 specimens. The origin, course, and termination of each articular nerve were documented. Relevant US landmarks were identified to locate each articular nerve. SUMMARY. In all 5 specimens, the DRUJ was innervated by articular branches originating from the anterior (AIN) and posterior (PIN) interosseus nerves. The RCJ was innervated by the superficial branch of radial nerve, lateral antebrachial cutaneous nerve, palmar cutaneous branch of median nerve, and PIN. The TFCC was innervated by the palmar and dorsal cutaneous branch of ulnar nerve, AIN, and PIN in all specimens. The medial antebrachial cutaneous nerve also supplied the TFCC in 4 of 5 specimens. Relevant US landmarks to locate the articular nerves included the tendon of flexor carpi radialis, pisiform bone, and dorsal tubercle of radius. CONCLUSIONS. The course and distribution of articular nerves supplying the DRUJ, RCJ, and TFCC provides an anatomical basis for the development of new clinical protocols to manage chronic wrist joint pain.

\*WALTERS, Brittany N.<sup>1</sup>, Stan C. KUNIGELIS<sup>2</sup>, and Mark N. COLEMAN<sup>1</sup>. <sup>1</sup>Department of Anatomy, DeBusk College of Osteopathic Medicine, Lincoln Memorial University, Harrogate, TN, 37752, USA; <sup>2</sup>Department of Physiology, DeBusk College of Osteopathic Medicine, Lincoln Memorial University, Harrogate, TN, 37752, USA.

### SEM Based Determination of the Motor to Sensory Axon Ratio of Median Nerve's Lateral & Medial Roots.

INTRODUCTION. This study quantifies and compares the number of axons, axonal diameter, and fascicular organization within the lateral and the medial roots of twenty-seven adult human cadavers. The lateral and medial cords give rise to the lateral and medial roots, which join to form the median nerve. Increased understanding of axon quantity, axonal diameter, and fascicular organization is critical in the case of brachial plexus root injury (BPRI) to minimize nerve graft failure and to optimize reinnervation. The relative ratios of motor to sensory axons present in the lateral and the medial roots of the brachial plexus were investigated. Such studies are scarce in the literature. METHODS. Peripheral nerve tissue sections of the lateral and the medial roots were surgically removed from the axilla region of formalin-fixed cadavers. The recurrent branch of the median nerve and the proper palmar digital nerve were controls of axonal diameter for sensory and motor nerves, respectively. Excised tissue sections were fractured using liquid nitrogen-based freeze-cracking, and subsequently fixed, dehydrated, dried, mounted, and viewed using scanning electron microscopy (SEM). ImageJ and SPSS software were used to analyze axon count, diameter, and density, plus fascicular bundle count and organization. SUMMARY. Preliminary analysis reveals a higher ratio of sensory to motor axons for the lateral root, and a higher ratio of motor to sensory axons for the medial root. Comparisons were based upon axonal diameter. CONCLUSIONS. Axonal quantification (total number of axons, axonal diameter, and axon density per fascicular bundle) suggests functional differences between the lateral and the medial roots of the median nerve. This data predicts dissimilar neurologic and functional losses following injury of the lateral or the medial roots of the brachial plexus. Clinical applications of this data could provide for improved pairing of nerve grafts to optimize reinnervation following BPRI.

# Abstracts – ePoster Presentations

**\*Accepted for Publication in Clinical Anatomy  
(Listed by presenting author last name)**

ALEXANDER Austin P., Kathryn S. NORTON, and Marsha D. RUTLAND. Department of Physician Assistant, Hardin-Simmons University, Abilene, TX, 79698, USA.

Anatomic Variation of Musculocutaneous Nerve.

INTRODUCTION. Physician Assistant students discover anatomic variation of the musculocutaneous nerve. RESOURCES. A 75-year-old female embalmed cadaver with a left upper extremity variation of musculocutaneous nerve not piercing through the coracobrachialis and three branches originating from the median nerve. DESCRIPTION. Dissection of the upper extremity revealed the musculocutaneous nerve not piercing through the coracobrachialis muscle. Students discovered three separate branches extending off the median nerve to innervate the coracobrachialis, biceps brachii, and brachialis muscles. Review of literature found this specific anatomic variation has a prevalence ranging between 1.5 to 15%. Variability in the origin of the musculocutaneous nerve not piercing through the coracobrachialis increases the susceptibility to damage as the nerve fibers are not protected by the biceps brachii muscle. Exploratory and traumatic surgical interventions can result in clinicians performing invasive procedures without prior knowledge of anatomical variation. Furthermore, anatomic variation of the origin of the musculocutaneous nerve arising from the median nerve could result in variability in the nerve roots supplying muscles of the anterior arm. Variability in the branches arising from the median nerve could result in atypical nerve root distribution to the muscles of the anterior compartment of the arm. This inconsistency could result in atypical myotome clinical presentations. SIGNIFICANCE. Variation in the musculocutaneous nerve requires clinicians to have an in depth understanding of neural pathways and function. Typical anatomy and anatomic variation must be considered to safely evaluate and perform invasive procedures of the upper extremity. Variations in the musculocutaneous nerve could explain atypical clinical presentation and procedural outcomes.

\*AZARI, Zubeen D.<sup>1</sup>, Anna R. STOCK<sup>1</sup>, JonAngelo PERRY<sup>1</sup>, Hannah W. HADDAD<sup>1</sup>, M S. DRAPER<sup>1</sup>, Micaela R. MOTZKO<sup>2</sup>, and Barth W. WRIGHT<sup>1</sup>. <sup>1</sup>Department of Anatomy, Kansas City University of Medicine and Biosciences, Kansas City, MO, 64106, USA; <sup>2</sup>Department of Anatomy, Kansas City University of Medicine and Biosciences, Joplin, MO, 64804, USA.

Analyzing the Effects of Increased Q-angle on Lateral Meniscus of the Knee: A Cadaveric Study.

INTRODUCTION. Increased Q-angle can lead to higher amounts of stress and pressure on the lateral meniscus. As an individual ages, the repetitive forces on the knee joint lead to degeneration of the articular cartilage of the femur and tibia as well as the meniscus. This study aimed to investigate the relationship between an increased Q-angle and lateral meniscus thickness in male and female cadavers with an average age of approximately 76 years. METHODS. This study examined 43 formalin-embalmed cadaveric right knees. The Q-angle was assessed using goniometry. Cadavers were positioned in a supine position with the knee extended, ankle internally rotated until perpendicular to the base of the dissection table, and the medial malleoli in line with one another. The knee cavity was opened through dissection to allow for localization and isolation of the lateral meniscus. The meniscus was marked at the midpoint and a caliper was used to measure the thickness of the lateral meniscus at this site. In addition to Q-angle and lateral meniscus thickness, variables such as weight, height, age and sex were documented. This study was approved by the KCU IBC on September 24, 2020. SUMMARY. After conducting a multivariate regression, when controlling for sex, height, weight, and age, there was not a significant relationship between Q-angle and lateral meniscus thickness (p-value=0.466). However, when controlling for sex, weight and Q-angle, there was a significant relationship between age (p= 0.024), height (p= 0.043) and lateral meniscus thickness. CONCLUSIONS. While we found limited influence of Q-angle on lateral meniscus thickness, it may be that our study sample, which was composed primarily of elderly individuals, led age to overwhelm any variation introduced by increased Q-angle. Further research on a younger sample could prove an interesting counterpoint to the present study.

\*BAEZ, Ramona<sup>1</sup>, Kyle BUCKLEY<sup>1</sup>, Sushama RICH<sup>1</sup>, Olalekan OGUNSAKIN<sup>2</sup>. <sup>1</sup> Anatomy Department, Touro College of Osteopathic Medicine, New York, NY, 10027, USA; <sup>2</sup>Basic Biomedical Sciences Department, Touro College of Osteopathic Medicine, New York, NY, 10027, USA.

Rare Origin of Thyroid Ima Artery in the Absence of the Right Inferior Thyroid Artery: Case Report.

INTRODUCTION. The right Inferior Thyroid Artery (ITA) originates from the right Thyrocervical artery (TCA) which in turn originates from the first part of the right Subclavian artery. The Thyroid Ima artery (TIA) is an accessory thyroid artery that may arise from the subclavian artery, arch of the aorta, common carotid (CCA), Brachiocephalic trunk (BCT), vertebral artery, or even internal thoracic artery. This rare finding is present in about 3-10% of the population and may originate in 80% from the TCA, 13% from the right CCA, and 6% from the aortic arch. Occurrence of the TIA was greater in Asians (10%) than Caucasians (6%), and in both

*continued on next page*

## Abstracts - ePoster Presentations continued

groups, a greater frequency was found on the right side as opposed to the left. The objective of this study was to describe a rare finding of the TIA arising at the bifurcation of the BCT with the absence of the right ITA. **METHOD.** Extensive bilateral dissection in a previously preserved 94-year-old female Caucasian donor. Dissection of the neck region was performed by plane, cleaned, colored, and photographed. Findings from the dissection were documented. **SUMMARY.** Following dissection, it was observed that the right Thyrocervical trunk gave off three branches: ascending cervical, transverse cervical, and suprascapular arteries; but the right Inferior Thyroid Artery was absent. Instead, there was a right TIA originating at the angle of bifurcation of the Brachicephalic Trunk in between the Common Carotid and the Subclavian arteries. The TIA ascended deep heading medially towards the deep surface of the south pole of the right thyroid lobe. Both superior thyroid arteries arose from the external carotid arteries and the left inferior thyroid arose from the left TCA. **CONCLUSIONS.** Knowledge of the presence, origin, and course of the TIA helps prevent its damage and subsequent hemorrhage into the mediastinal cavity during surgical procedures as it can hide behind the manubrium.

BAGLEY, Madison B.<sup>1</sup>, Andrew G. SMITH<sup>2</sup>, David A. MORTON<sup>1</sup>, Candace J. CHOW<sup>3</sup>. <sup>1</sup>Department of Neurobiology, University of Utah School of Medicine, Salt Lake City, UT, 84112, USA; <sup>2</sup>Department of Pediatrics, University of Utah School of Medicine, Salt Lake City, UT, 84108, USA; <sup>3</sup>Department of Internal Medicine, University of Utah School of Medicine, Salt Lake City, UT, 84132, USA.

### Student Perceptions of Active Learning: A Qualitative Study.

**INTRODUCTION.** Research shows active learning is an effective teaching method in medical education. However, few qualitative studies explore student perceptions of active learning. Understanding the role active learning plays in fulfilling students' educational needs requires further investigation. **METHODS.** Homegrown puzzle activities were developed as active learning tools that use retrieval practice principles. Each puzzle involved a series of anatomical images, diagrams, and textual descriptions to be sorted and matched based on clinical concepts. Puzzles were completed in small groups after students finished relevant pre-work. Several sets of these activities were adapted for online delivery and implemented within the medical school's Fall 2020 cardiovascular, pulmonary, and renal organ system course. To investigate second-year medical students' attitudes toward these puzzle activities, three Zoom-based focused groups were held and recorded throughout the course. Students were also recorded while completing the activity. Recordings were transcribed and coded using thematic analysis. **SUMMARY.** Students reported that peer interactions were of high value, though their experiences depended on group dynamics. Some interactions and student-reported thought processes were action-oriented and lacked analysis, whereas others were more metacognitive. Other specific student-outlined benefits of the activities included promotion of learning, provision of structure, and designation of high-yield concepts. Challenges included feelings of confusion, problems with timing or difficulty of the tasks, and low utility without adequate preparation. **CONCLUSIONS.** These data elucidate the student perception of active learning in medical education. Though these outcomes are focused on a single course, the data can be used to refine future learning activities and teach health science educators strategies for integrating active learning into curriculum in a student-centered fashion.

BLYTHE, Connor S., Mikaela S. REYNOLDS, and Laura S. GREGORY. School of Biomedical Sciences, Faculty of Health, Queensland University of Technology, Brisbane, QLD 4000, Australia.

### Predicting Developmental Stage of Calcaneal Apophysis: A Bi-Imaging Modality Regression Analysis.

**INTRODUCTION.** The range of variation in the timing and pattern of the calcaneal apophyseal formation and fusion has not been reported, with the limited studies relying on lateral plain radiographs that limit the 3D evaluation of apophyseal development. A lack of knowledge of the variation in the timing or pattern of ossification can lead to misdiagnosis as pathological findings such as fractures, necrosis, or apophysitis. To improve patient management and outcomes, and limit misdiagnosis, we have created a sex-specific predictive model that can classify the calcaneal apophyseal stage of development from a patient with known sex and age. **METHODS.** A multinomial logistic regression was performed on a truncated 6 stage system that was created using 835 deidentified patient scans (females: 414, males: 421) aged neonate to 20 years from the Queensland Health Enterprise PACS database. Relative risk ratio, classification tables and predicted probabilities were calculated. **SUMMARY.** Based on known age and sex, sex-specific predictive models were created using both lateral radiographs and computed tomography scans, which were able to correctly predict calcaneal apophyseal stage in 80.2% of our sample, with most misclassification occurring in neighbouring stages. These sex-specific predictive models can be used to aid clinicians for diagnostic purposes, for example: If an athletic child of 9 years of age complained of painful heels, clinicians could use our novel sex-specific probability tables to predict apophyseal stage development without medical imaging. Based on the child's age and sex they would fall under stage 3 for females and stage 2 for males, with pain most likely corresponding to inflammation associate with apophysitis which occurs most frequently during these stages. **CONCLUSIONS.** The predictive models can be applied in clinical settings by clinicians to inform diagnosis without the need for scans.

## Abstracts - ePoster Presentations continued

BLYTHE, Connor S., Mikaela S. REYNOLDS, and Laura S. GREGORY. School of Biomedical Sciences, Faculty of Health, Queensland University of Technology, Brisbane, QLD 4000, Australia.

### Calcaneal Apophyseal Development: A Bi-Imaging Paediatric Investigation.

**INTRODUCTION.** Current understanding of calcaneal apophyseal development relies on the interpretation of two-dimensional lateral radiographs, preventing the evaluation of the ossification of the medial and lateral processes. This study investigated the anatomical and spatial development of the calcaneal apophysis in computed tomography (CT) scans of individuals aged birth to 20 years to overcome this limitation. A novel scoring system was constructed to assess the three-dimensional development and fusion of the calcaneus, including the medial and lateral processes; and comparisons made between its application to CT scans and lateral radiographs. **METHODS.** The sample consisted of retrospective multi-slice CT and lateral radiograph images of the heel of 835 deidentified patient scans (females: 414, males: 421), from the Queensland Health Enterprise PACS database. An 11-stage morphological classification system for the ossification and fusion of the calcaneal apophysis was developed and used to score the stage of development in multiplanar formatting views and three-dimensional reconstructions in Horos. **SUMMARY.** An ANOVA analysis demonstrated that ossification of the calcaneal apophysis commenced with several centres at 5.25 years for females and 7.19 years for males, with fusion commencing at 12.85 years for females and 13.67 years for males. Females were observed to undertake ossification and fusion significantly earlier compared to males ( $p < 0.001$ ) in 10 of the 11 stages of development. Additionally, it was found that the medial and lateral processes develop from entirely separate ossification centres in 39% of our samples. **CONCLUSIONS.** This study introduces a detailed staging system to classify the morphological development of the calcaneal apophysis and the medial and lateral processes using two imaging modalities. Application of this staging system in future research and clinical contexts, will continue to improve our understanding of calcaneal development.

BRUECKNER-COLLINS, Jennifer, and Ashton PORTER. Department of Anatomical Sciences and Neurobiology, University of Louisville School of Medicine, Louisville, KY, 40222, USA.

### Impact of a Facebook™ Grief Support Group on Medical Student Grief in Anatomy Lab and Beyond.

**INTRODUCTION.** While training for end-of-life care is common in the clinical curriculum, less time is spent helping medical students manage their own grief when confronted with death. For many, their first death encounter is in the cadaveric anatomy lab and this can be a trigger for grief associated with the loss of loved ones. Learning to regulate emotions under stress when faced with death is a key skill that all trainees must learn. Reflecting on personal experiences with death and the grief that accompanies it has proven effective in clinical settings, particularly in debriefs with faculty, peers and near-peers. **RESOURCES.** To address the need for preclinical medical students to have a safe place to support one another in their grief experiences, a private School of Medicine Student Facebook site was created in November 2019; it is made clear that this group should not replace a licensed counselor and oversight is provided by a third year medical student and a faculty mentor. **DESCRIPTION.** This social media support group has attracted 57 members over the course of 15 months, with an average of 20 posts per month. Some posts are authored by members sharing their own grief experiences, asking for support or sharing their own best practices, while others include articles or podcasts intended to give words to the multiple forms that grief can take. Quotes and stories are routinely posted to maintain a consistent and supportive presence in members' feeds. This group has met in person and virtually to foster camaraderie initiated in this online environment. Group activities included kintsugi (Japanese art of putting broken pottery pieces back together with gold), wellness programming and simply providing an open forum for members in need. **SIGNIFICANCE.** This online grief support group has proven effective in providing information, support and social connection for medical students at all stages of training, who are experiencing various forms of grief.

\*CAMPISI, Emma S., John TRAN, Mai Lan JOHNSTON, and Anne M.R. AGUR. Division of Anatomy, Department of Surgery, University of Toronto, Toronto, ON M5S 1A8, Canada.

### A 3D Modelling Study of the Architecture of Flexor Digitorum Profundus: Functional Implications.

**INTRODUCTION.** The investigation of the muscle architecture of flexor digitorum profundus (FDP) is imperative to understanding the role of FDP in digital (2-5) movements. To date, no studies have quantified three-dimensional (3D) morphology and architectural parameters of FDP. The purpose is to model and quantify in 3D the morphology and architectural parameters of the digital bellies of FDP in situ to determine their relative excursion/force generation capabilities. **METHODS.** The fiber bundles/aponeuroses of the bellies of FDP were serially dissected and digitized (MicroScribe® Digitizer) in 5 embalmed specimens. The skeleton was laser scanned using a FARO® Quantum FaroArm®. The data were reconstructed into 3D models (Autodesk® Maya®). Fiber bundle length (FBL), pennation angle (PA) and physiological cross-sectional area (PCSA) were quantified. The 3D morphology and architectural parameters were compared between digital bellies. **SUMMARY.** Fiber bundles of each digital belly had a distal attachment to the superficial and

*continued on next page*

## Abstracts - ePoster Presentations continued

deep surfaces of an internal aponeurosis. This aponeurosis was continuous with the external tendon. Architectural parameters varied between the digital bellies. Mean FBL of the 2nd and 4th digital bellies were similar ( $78.9 \pm 18.5$ mm) and about 17 mm longer than the 3rd belly and 10mm longer than the 5th. The 2nd and 3rd digital bellies had the largest mean PCSA, and the 4th belly the smallest. Mean PA was similar in all bellies (range  $5.6-8.8^\circ$ ). CONCLUSIONS. The relative functional capabilities of the digital bellies vary, with the 2nd digit having the greatest relative excursion and force generating capabilities as evidenced by the largest mean FBL and PCSA. Of the remaining digital bellies, the 4th had the greatest relative excursion capability and the 3rd the largest relative force generating capability. Further in vivo study is needed to document architectural changes during hand movements to enhance our understanding of the role of each FDP belly.

\*CARTER, Yasmin<sup>1,2</sup>. <sup>1</sup>Division of Translational Anatomy, Department of Radiology, University of Massachusetts Medical School, Worcester, MA, 01602, USA; <sup>2</sup>Innovations Lab, University of Massachusetts Medical School, Worcester, MA, 01655, USA.  
Creation of an Anatomically Accurate Model of the Deltoid for Pediatric Injection Training.

INTRODUCTION. UMASS Medical School students provide yearly flu vaccinations to over 2000 local children who may otherwise lack access. In their first year, all medical students are offered injection training. While reducing the spread of the flu virus, this program also provides practical training and clinical experience; however, it is difficult to safely and effectively train an adequate number of students in response to the increased demand for flu vaccines. To support this, a unique silicon deltoid model for bolus injection practice was designed and created, with the goal of being injectable, reusable, and anatomically accurate for the age of the child being injected. METHODS. Platinum cure silicon was used in layers of differing densities to replicate muscle, fat, and skin and colored accordingly. Layers of fabric represent the fascial planes surrounding the deltoid. A metal plate acts as a proxy for the humerus and as a safety device. The depths of each layer were based on previously reported radiological studies of elementary school children (6-13 yrs). Together these different density layers provide haptic feedback to the injector when they are in the correct position. SUMMARY. The first iteration of the model was used in Fall 2019 through the COVID-19 pandemic. While reusable, some leaked after prolonged use, a second generation is now being deployed which has more lifelike skin texture and greater protection against leakage. This model incorporates optional dimensions that more realistically reflect the diversity of our community including variations in skin coloration, adipose deposition, and muscle mass. CONCLUSIONS. Previous studies suggest CDC needle-length guidelines may lead to under or over penetration of the deltoid up to 60% of the time in children. This model represents the most anatomically accurate pediatric deltoid injection trainer currently available, and as such may allow for practiced placement and reduction of these penetration errors.

\*COLLINS, Amanda J.<sup>1</sup>, Thomas R. GEST<sup>2</sup>, Chelsea Lohman BONFIGLIO<sup>3</sup>, Edgar R. MEYER<sup>4</sup>, Haley L. NATION<sup>5</sup>, Jonathan J. WISCO<sup>6</sup>, and Yasmin CARTER<sup>1</sup>. <sup>1</sup>University of Massachusetts Medical School, Department of Radiology, Worcester, MA, 01655, USA; <sup>2</sup>University of Houston College of Medicine, Department of Biomedical Sciences, Houston, TX, 77204, USA; <sup>3</sup>University of Colorado Anschutz Medical Campus, Department of Cellular and Developmental Biology, Aurora, CO, 80045, USA; <sup>4</sup>University of Arkansas for Medical Sciences, Department of Neurobiology and Developmental Sciences, Division of Clinical Anatomy, Little Rock, AR, 72205, USA; <sup>5</sup>University of Texas Health Science Center in San Antonio, Department of Cell Systems and Anatomy, San Antonio, TX, 78230, USA; <sup>6</sup>Boston University School of Medicine, Department of Anatomy and Neurobiology, Boston, MA, 02118, USA.  
The Sum of Our Voices: Toward Achieving Diversity, Equity, and Inclusion in the AACA.

INTRODUCTION. The Committee on Diversity, Equity, and Inclusion (CDEI) was formed in 2020 with the primary goal of assessing the needs of current AACA members with regard to learning, understanding, and implementing policies and practices of diversity, equity, and inclusion. The secondary goal is to recommend policy and procedural guidelines to establish a global standard. RESOURCES. The member profile on the AACA website is a resource that collects biographical and professional data of each member. The original version of this form was rarely completed by members (~44% provided sex data, ~6.5% provided age), and questions in the member profile were worded in a non-inclusive manner. In response to these oversights, the profile page has been updated to ask specific, inclusive, and appropriate questions around different aspects of diversity. DESCRIPTION. To address the primary goal of the CDEI, a data-driven approach will be used by collecting de-identified multi-dimensional demographics with regard to sex, gender, race/ethnicity, age, religion, and others as appropriate to better understand the make-up and needs of the current membership. The CDEI will use these data to create recommendations for the AACA to improve representation of the overall membership. The CDEI further aims to actively identify and address barriers to recruitment and retention of underrepresented peoples in the society. Secondly, evaluation of current AACA policies, statements, forms, and other documents will lead to recommendations on areas of improvement. The CDEI will actively participate in the organization of the annual meeting to foster a robust, welcoming environment and safe space for participants of all backgrounds to share experiences, develop mentorships, and grow professionally. SIGNIFICANCE. Acknowledging and supporting diversity and inclusion within the AACA, the CDEI will cultivate career development support for our students, colleagues, and institutions.

*continued on next page*

## Abstracts - ePoster Presentations continued

\*COTTAM, Wayne W.<sup>1</sup>, Kellie C. HUXEL BLIVEN<sup>2</sup>, and Rebecca J. HLAVAC<sup>2</sup>. <sup>1</sup>Arizona School of Dentistry & Oral Health, A.T. Still University, Mesa, AZ, 85206, USA; <sup>2</sup>Department of Interdisciplinary Health Sciences, Arizona School of Health Sciences, A.T. Still University, Mesa, AZ, 85206, USA.

### Examination of Proximal Attachments of the Medial Pterygoid Muscle's Superficial Head.

INTRODUCTION. The medial pterygoid (MP) muscle contains a deep (MP-DH) and superficial head (MP-SH) and functions to elevate, protrude, and laterally deviate the mandible. Discrepancy and lack of detail exists about the proximal attachments of the MP-SH, which may limit understanding of its full capacity as a muscle of mastication. The purpose of this study was to more clearly describe the proximal attachments of the MP-SH. METHODS. 18 MP's from 9 adult human cadavers (1 fresh frozen; 8 lightly embalmed) were studied. Serial dissections opened the infratemporal fossa and removed all structures lateral to the MP, and detached the MP from its distal attachment on the mandible to visualize the MP-DH and MP-SH at their proximal attachment(s). Blunt dissection was used to separate the MP-DH and MP-SH. Then, proximal attachments of the MP-DH and MP-SH were identified, confirmed by two investigators, and recorded. SUMMARY. The MP-DH had two apparent bundles; the medial bundle attached into the pterygoid fossa (n=17/17, 100%) and the lateral bundle attached on the medial aspect of the lateral pterygoid plate (n=17/17, 100%). The MP-SH had two distinct bundles (n=17/17, 100%). The anterolateral bundle appeared as muscle fibers. It attached on the inferior edge of the lateral pterygoid plate and extended anterosuperiorly into the pterygomaxillary groove (n=17/17, 100%), and onto the maxillary tuberosity (n=11/17, 65%). The posteromedial bundle was deeper with a tendinous appearance, with attachments onto the maxillary tuberosity (n=16/17, 94%) and palatine's pyramidal process (n=18/18, 100%). The presence and attachments of these bundles displayed little variability between the specimens. CONCLUSIONS. We propose the presence of two previously undescribed and consistent bundles comprising the MP-SH that present with distinct appearances and attachments, potentially suggesting a more complex functional role of this muscle and warrants further investigation and confirmation.

DENNIS, Jennifer F.<sup>1</sup>, Malli BARREMKALA<sup>2</sup>, Danielle C. BENTLEY<sup>3</sup>, Kirsten M. BROWN<sup>4</sup>, Gary J. FARKAS<sup>5</sup>, Haviva M. GOLDMAN<sup>6</sup>, Derek J. HARMON<sup>7</sup>, Kelly M. HARRELL<sup>8</sup>, Barbie A. KLEIN<sup>7</sup>, Christopher J. RAMNANAN<sup>9</sup>, and Stefanie M. ATTARDI<sup>2</sup>. <sup>1</sup>Department of Anatomy, Kansas City University, Joplin, Missouri; <sup>2</sup>Department of Foundational Medical Studies, Oakland University William Beaumont School of Medicine, Rochester, Michigan; <sup>3</sup>Division of Anatomy, Temerty Faculty of Medicine, University of Toronto, Toronto, Ontario, Canada; <sup>4</sup>Department of Anatomy and Cell Biology, George Washington University School of Medicine and Health Sciences, Washington, D.C.; <sup>5</sup>Department of Physical Medicine and Rehabilitation, University of Miami Miller School of Medicine, Miami, Florida; <sup>6</sup>Department of Neurobiology and Anatomy, Drexel University College of Medicine, Philadelphia, Pennsylvania; <sup>7</sup>University of California, San Francisco, School of Medicine, San Francisco, California; <sup>8</sup>Department of Anatomy and Neurobiology, Virginia Commonwealth University School of Medicine, Richmond, Virginia; <sup>9</sup>Department of Innovation in Medical Education, University of Ottawa, Ottawa, Ontario, Canada.

### Shifts in Gross Anatomy Lab Delivery Formats and Assessments During Covid-19.

INTRODUCTION. Traditional gross anatomy lab involves in-person teaching and exam; however, Covid-19 restrictions created challenges to this format. The aim of this study was to describe gross anatomy lab formats during Covid-19 and compare lab assessment before Covid-19 to August-December 2020. METHODS. A 20-item survey evaluated gross anatomy teaching before and during Covid-19. A total of 179 responses were received; narrative data for 3 items on gross anatomy lab format and lab assessment were coded. Responses were statistically compared using Chi-square or McNemar tests. Alpha<5%. SUMMARY. Codes for lab teaching pertained to delivery, lab practice, and student group size, while codes for assessment pertained to setting, exam type, and materials used. Lab formats during Covid-19 emphasized the use of synchronous (59%), asynchronous (3.9%), or mixed (37%) content delivery (P<0.0001). Student dissection (32.3%), prosection (21.3%), and/or utilization of digital anatomical resources (46.5%) were the most frequent lab practices (P<0.0001). Student small groups (76.9%) were used in remote sessions, while large groups (23.1%) were used to present the lab topic by faculty (P<0.0001). Assessment in the lab setting decreased (P<0.0001) while computer exams increased (P<0.0001) during Covid-19 as compared to before the pandemic. Cadavers (P<0.0001) and bones, models, and plastinates (P=0.001) usage decreased, while imaging increased (P<0.0001) during Covid-19. Although most respondents maintained a "bell ringer" lab exam (P=0.65), there were increases in the use of written assessments during Covid-19 (P=0.002). CONCLUSIONS. During August-December 2020, anatomists largely taught through synchronous and mixed delivery formats that relied on the use of cadaveric specimens and digital resources due to Covid-19. Although anatomists continued lab exams, the setting shifted towards computer exams. Thus, imaging use increased with a concurrent decrease in cadaver use.

*continued on next page*

## Abstracts - ePoster Presentations continued

GDOWSKI, Martha J.<sup>1,2</sup>, Sarah E.A. MCCONNELL<sup>1,2</sup>, and Linda M. CALLAHAN<sup>1,2,3</sup>. <sup>1</sup>Department of Neuroscience, University of Rochester School of Medicine and Dentistry, Rochester, NY 14642, USA; <sup>2</sup>Del Monte Institute for Neuroscience, University of Rochester School of Medicine and Dentistry, Rochester, NY 14642, USA; <sup>3</sup>Department of Pathology and Laboratory Medicine<sup>3</sup>, University of Rochester School of Medicine and Dentistry, Rochester, NY 14642, USA.

### Virtual Delivery of Undergraduate Medical Histology: A New Vision for Instruction.

INTRODUCTION. COVID guidelines warranted changes in the delivery of the first-year undergraduate medical histology curriculum at the University of Rochester School of Medicine and Dentistry (URSMD) during Fall 2020. Despite concern about students' learning, this class achieved the 2<sup>nd</sup> highest cumulative histology scores of the last 20 years. The methods used to achieve these results are described herein. RESOURCES. The URSMD histology slide collection had been digitized for delivery through NDP. Serve software (Hamamatsu, USA) in 2010. This digital migration was motivated by a desire to improve instructional efficiency and reduce microscope maintenance costs. In 2020, Zoom meeting software was used to deliver instruction to pods of 20-21 students. DESCRIPTION. After group instruction, students were randomly assigned into Breakout Rooms of 4-5 students for faculty-facilitated collaborative work, guided by laboratory exercises used in prior years. Feedback about instructional efficacy was collected through an end of course evaluation (1<sup>st</sup>-year medical students) and debriefs of teaching assistants (TAs; 3<sup>rd</sup>- or 4<sup>th</sup>-year medical students) who had experienced in-person and observed remote instruction methods of this content. End of course evaluation revealed increased satisfaction in 2020 (4.16/5.0) relative to in-person histology instruction in 2019 (3.94/5.0). TAs noted improvements relative to their own learning experience, citing increased collaboration and improved group dynamics. SIGNIFICANCE. There is considerable debate about virtual instruction. Randomized Zoom Breakout Room assignments fostered clinically-relevant teamwork skills through collaborative, goal-directed small group work. NDP. Serve software engaged learners with a simulated microscope experience. Creative use of technologies facilitated effective delivery of the undergraduate medical histology curriculum that we will continue to implement and refine in the future.

GREENE, Sarah J.<sup>1</sup>, and Amy COHEN EFRON<sup>1,2</sup>. <sup>1</sup>Department of Pathology and Anatomy, Morehouse School of Medicine, Atlanta, GA, 30032, USA; <sup>2</sup>College of Education and Human Development, Georgia State University, Atlanta, GA, 30303, USA.

### Using Anatomy of the Ear to Start a Conversation on Cultural Competency and Health Equity.

INTRODUCTION. Every year, anatomy of the auditory system is taught to students in healthcare professions programs. Hearing loss is often introduced as an associated "pathology," with a focus on what is "wrong" with certain structures, thereby supporting the medical perspective on deafness. Many educators unknowingly use this perspective to perpetuate challenges in healthcare and inequities in the care of the Deaf and Hard of Hearing communities. METHODS. To address this, the authors developed an optional eight-week seminar series that was introduced to medical students at Morehouse School of Medicine in the spring of 2021 to explore challenges in healthcare and the cultural perspective on deafness. Anatomy of the auditory system was used as a starting point for discussion on language development and deprivation, treatment devices for hearing loss and access, eugenics, family dynamics, Deaf Gain and advocacy, associated legislature, and mental health and mistrust. To earn a certificate of completion, students must attend weekly 90-minute virtual meetings, view readings and videos, contribute to weekly discussion posts, and complete pre- and post-assessments and a course evaluation. SUMMARY. To date, 28 students have enrolled in the seminar series, and pre-assessment data (33 questions) demonstrate that there is a significant need for education on realistic expectations surrounding cochlear implants, how to appropriately respond to parents' decisions about implanting their children, and the role of an interpreter in healthcare, among other topics. CONCLUSION. Upon completion, the authors will make comparisons between pre- and post-assessments and complete thematic analyses of discussion posts and course evaluations, and report on the outcomes and impact of this experience. (Sponsored by grant No. P03-1B141018 with the US Department of Education).

\*HALL, Tyler R., Sarah A. BEAM, Madeline F. PARKER, Joy Y. BALTA, and Jennifer M. BURGOON. Division of Anatomy, Department of Biomedical Education and Anatomy, College of Medicine, The Ohio State University, Columbus, OH, 43210, USA.

### Multiple Variations of Forearm Musculature Uncovered During Routine Cadaveric Dissection.

INTRODUCTION. The presence of anatomical variations may exacerbate pathologies and complicate medical procedures. RESOURCES. A 79-year-old male donor, whose cause of death was cardiac arrest, was routinely dissected in preparation for prosection use in an undergraduate human gross anatomy curriculum. DESCRIPTION. Multiple muscular variations were found during a routine dissection of this single donor. First, a rare variation of the extensor indicis radialis muscle was found bilaterally in the deep muscles of the posterior forearm. The muscle had a belly originating from the extensor indicis muscle and it inserted onto both the tendon of the extensor pollicis longus muscle and the extensor hood of the index finger. Second, an extensor medii proprius muscle was present in the left posterior forearm only. Finally, bilateral extensor digiti minimi muscles displayed double tendons distal to the

## Abstracts - ePoster Presentations continued

extensor retinaculum. SIGNIFICANCE. The presence of an atypical extensor indicis radialis muscle may have clinical implications in pathologies affecting the anatomical snuffbox, such as de Quervain's Disease. Knowledge of the presence of extensor medii proprius muscle and extensor digiti minimi muscle variations is important in clinical procedures involving the hand, such as tenoplasty.

\*HAN, Aya<sup>1</sup>, Koichi WATANABE<sup>1</sup>, Eiko INOUE<sup>1</sup>, Yoko TABIRA<sup>1</sup>, Joe IWANAGA<sup>1,2</sup>, Akihiro YAMASHITA<sup>1</sup>, Keishirou KIKUCHI<sup>1</sup>, Kunimitsu NOOMA<sup>1</sup>, and Tsuyoshi SAGA<sup>3</sup>. <sup>1</sup>Department of Anatomy, Kurume University School of Medicine, Kurume, Fukuoka, 830-0011, Japan; <sup>2</sup>Department of Neurosurgery, Tulane University, New Orleans, LA, 70118, USA.; <sup>3</sup>Domain of Anatomy, Kurume University School of Nursing, Kurume, Fukuoka, 830-0003, Japan.

### Histological Study of Cadaver Lower Eyelids to Determine Morphological Changes with Age.

INTRODUCTION. The lower eyelid is prone to age-related cosmetic changes that lead to markedly enlarged tear troughs and palpebromalar grooves. These changes are believed to be due to morphological alterations in orbital fat, increased orbital ligament laxity, and thinning of the orbicularis oculi muscle. To date, however, few histological studies to support these suppositions have been reported. We therefore designed a study to determine morphological changes of the lower eyelid, including the orbicularis oculi and orbital fat, based on increasing maturity, from middle age (in the 40s) to more than 100 years of age. METHODS. The lower eyelids, including the bones, were removed en bloc from formalin-fixed cadaver donors who were in their 40s, 60s, 80s, and 100-plus. The specimens were frozen and then cut into 5-mm-wide sagittal sections using a diamond saw. After observing and recording the gross findings, the eyelids were fixed in paraffin, cut into 25- to 30-  $\mu$ m slices, and stained with hematoxylin-eosin and Masson trichrome. SUMMARY. Review of the orbital fat of the lower eyelids—which was classified into three blocks according to increasing age—showed that the fat protruded more anteriorly due to increasing laxity of the orbital septa with increasing age (i.e., in the middle blocks). With aging, the subcutaneous fat, in front of the orbital fat, showed thinning, as did orbicularis oculi muscle fibers, which displayed increased gaps between them. Additionally, the orbitomalar ligament tended to display more laxity with age. CONCLUSIONS. Histological assessment allowed objective evaluation of the signs and stages of aging of the lower eyelid. We believe that these findings can be useful in future clinical surgery, including blepharoplasty.

\*HAN, John R.<sup>1</sup>, Philip W.H. PENG<sup>2</sup>, and Anne M.R. AGUR<sup>1</sup>. <sup>1</sup>Division of Anatomy, Department of Surgery, University of Toronto, Toronto, ON M5S 1A8, Canada; <sup>2</sup>Department of Anesthesiology and Pain Medicine, University of Toronto, Toronto, ON M5G 1E2, Canada.

### 3D Innervation of Cervical Zygapophysial Joints: Implications for Image-Guided Nerve Ablation.

INTRODUCTION. Fifty-five percent of patients with back pain report cervicofacet joint involvement. Image-guided nerve block (NB) and radiofrequency ablation (RFA) of the medial branches of the posterior rami are used to manage cervicofacetogenic pain. NB/RFA require precise knowledge of the course of the sensory innervation to the cervical zygapophysial joints (CZP) relative to soft and bony tissue landmarks. No 3D studies investigating the sensory innervation to the CZP were found in the literature. The purpose was to capture and model in 3D the course of the sensory innervation to C3-C7 CZP and identify soft and bony tissue landmarks that could be used to localize the nerves with image-guidance systems. METHODS. Two formalin-embalmed specimens were used. The branches given off the medial branches of C3-C7 posterior rami were serially dissected and digitized (Microscribe<sup>®</sup> G2X Digitizer) to their termination. Skeletal features were also digitized. The data were reconstructed in 3D using Autodesk<sup>®</sup> Maya<sup>®</sup>. The models were used to document the course of the nerves innervating C3-C7 CZP. The relationship of the nerves supplying the CZP capsules to soft and bony tissue landmarks were determined. SUMMARY. The innervation pattern of the CZP varied regionally. C6/C7 facet joint was innervated by fine branches from C6 and C7 medial branches. C3 to C5 capsular branches formed a nerve plexus lying on the posterior surface of the articular pillar. Branches from this plexus extended anteriorly to innervate the CZP in this region. Landmarks specifically localizing the capsular branches to the CZP include posterior aspect of the articular pillar and deep segmental intermuscular tendons of semispinalis capitis. The posterior intertransversarii can also be used as landmarks. CONCLUSIONS. The results of this 3D pilot study provide the anatomical basis for the development of novel image-guided NB/RFA protocols that could enable precise targeting of capsular branches to the CZP.

\*HENKES, Zoe I., Dane A. MEYER, Sania V. KARIR, Felicia D. LEE, Young T. LEE, Larry F. YANG, Daniel T. DALY, and Yun TAN. Center for Anatomical Science and Education, Saint Louis University School of Medicine, Saint Louis, MO, 63108, USA.

### Brachial Artery Trifurcation and Associated Radial Recurrent Artery Variation.

INTRODUCTION. Upper extremity vasculature anatomical variations are clinically important for various procedures. Brachioradial artery (BRA) and brachioulnar artery (BUA) are variations resulting from an atypical division of the brachial artery in the arm. Additional variations in the upper limb including the collateral circulation surrounding the elbow have been reported, but unique

*continued on next page*

## Abstracts - ePoster Presentations continued

presentations are still being observed. Particularly, the presence of a radial recurrent artery (RRA) branching from the BUA provides a rare relationship observed in this case. **RESOURCES.** The left upper limb from a 77-year-old female cadaver, received through the Saint Louis University Gift Body Program, was dissected during a gross anatomy course following Grant's Dissector Manual, 16th edition. **DESCRIPTION.** Following typical branching of the deep brachial artery (DBA), a high trifurcation of the brachial artery (HTBA) was seen splitting into the superior ulnar collateral artery, BUA, and BRA at 7.9 cm distal to the lower margin of the teres major. In the arm, an accessory superior ulnar collateral artery branched from the BRA, 6.9 cm distal to the HTBA, while the inferior ulnar collateral artery (IUCA) branched from the BUA, 9.1 cm distal to the HTBA. In the forearm, the BRA and BUA continued as the typical orientation of the radial artery (RA) and ulnar artery (UA), respectively. A common trunk branched from the UA, 14.5 cm distal to the HTBA, and coursed laterally for 0.8 cm before splitting to a descending muscular branch and the RRA. The RRA coursed posteriorly to the RA, anastomosing with the radial collateral artery, which originated from the DBA. **SIGNIFICANCE.** This case report presents a unique variation in the origin of the RRA that provides useful information for procedures involving graft tissue from this area, such as a radial forearm flap for head and neck resection surgeries.

HILL, Robert V., and William P. RENNIE. Donald and Barbara Zucker School of Medicine at Hofstra/Northwell, Hempstead, NY, 11549, USA.

### Diverse Learning Approaches Highlight the Clinical Applications of Abdominal Anatomy.

**INTRODUCTION.** High and low-fidelity learning approaches have both been recommended to supplement or replace dissection-based anatomy education. While each has its advantages, we advocate blending dissection with a multitude of resources to best integrate basic science with clinical application. **RESOURCES.** We designed an educational session on clinical abdominal anatomy that merges high and low-fidelity learning approaches in an integrative lab setting. The session included learning stations that mutually reinforced major concepts of abdominal anatomy already learned via dissection. **DESCRIPTION.** Small groups of students rotated among five 30-minute activities: (1) interpreting CT scans to reinforce normal anatomical relationships and to recognize common pathologic processes; (2) demonstrating layers of the abdominal wall with a fabric model and correlating with prosected donor specimens; (3) guided video observation of critical laparoscopic views for selected surgical procedures; (4) practical use of real laparoscopic instruments to complete simple tasks in the donor body, observing movement, technique, and underlying anatomy in real-time video using iPads; and (5) practical, real-time ultrasonography of the abdomen, acquiring standard clinical images to demonstrate a variety of intra-abdominal relationships. Student evaluations of the session from two academic years were generally positive, with 94% of students agreeing that the session fostered active learning and 90% agreeing that the session represented a good balance between facts and conceptual application. Open-ended comments generally praised the hands-on approach to anatomy and the multiple clinical connections. **SIGNIFICANCE.** The key innovation of this lab session is the blended use of low and high-fidelity resources to accomplish clinically-based integration of anatomical concepts. The modular nature of the session allows it to be adapted, in part or as a whole, to other curricula.

\*HONG, Joseph<sup>1</sup>, Vinayak K. NAHAR<sup>2</sup>, Adam KOLATOROWICZ<sup>3</sup>, and John GASSLER<sup>1</sup>. <sup>1</sup>Department of Anatomy, DeBusk College of Osteopathic Medicine, Lincoln Memorial University, Harrogate, TN 37752, USA; <sup>2</sup>Department of Dermatology, University of Mississippi Medical Center, Jackson, MS 39215, USA. <sup>3</sup>Department of Anatomy, DeBusk College of Osteopathic Medicine, Lincoln Memorial University, Knoxville, TN, 37932, USA.

### Anatomic and Morphometric Differences Between Sexes in the Calcaneonavicular (Spring) Ligament.

**INTRODUCTION.** Flatfoot or pes planus is a common condition with a prevalence of up to 20% in the adult population. When resulting from physiologic or structural changes that cause the medial longitudinal arch to collapse, it is referred to as Progressive Collapsing Flatfoot Deformity (PCFD) and traditionally has been associated with weakening or tearing of the posterior tibial tendon. More recently the interosseous and ligamentous structures of the medial foot have been identified as critical in the pathophysiology. Most commonly, the calcaneonavicular (spring) ligament is affected, and several studies of PCFD have demonstrated females three to six times more frequently affected than males. The purpose of this study is to compare the anatomy of the spring ligament of males to females for variations in morphology: length, width, and thickness. **METHODS.** Using a Mitutoyo handheld caliper, ligament parameters (length, width, and thickness) of the three components of the calcaneonavicular ligament (superomedial (SML), inferoplantar longitudinal (IPL), and medioplantar oblique (MPO)) in a convenience sample of 53 anatomical donor feet were compared between sexes from a modern American adult population. Independent samples t-test were used to compare means and Cohen's d were used to measure effect size. **SUMMARY.** The SML length (superomedial side) ( $p=0.13$ ,  $d=0.7$ ), the SML length (inferolateral side) ( $p<0.001$ ,  $d=1.2$ ), SML calcaneal width ( $p=0.044$ ,  $d=0.6$ ), SML articular thickness ( $p<0.001$ ,  $d=1.4$ ), SML medial thickness ( $p<0.001$ ,  $d=3.1$ ), MPO maximal portion ( $p=0.045$ ,  $d=0.6$ ), MPO central thickness ( $p<0.001$ ,  $d=1.2$ ), MPO medial length

## Abstracts - ePoster Presentations continued

( $p=0.033$ ,  $d=0.6$ ), and IPL thickness ( $p<0.001$ ,  $d=3.2$ ) were shorter in females compared to males. CONCLUSION. There are anatomic and morphometric differences between sexes in the calcaneonavicular ligament. These differences may contribute to support provided by the medial longitudinal arch and ultimately the discrepancy we see between sexes in PCFD.

\*IMMONEN, Jessica A., and Kaiko R. PERKINS. University of Nevada Las Vegas, Las Vegas, NV, 89106, USA.  
The Time and Place for Plastination: Recorded Tutorials Facilitate Remote Learning in Dentistry.

INTRODUCTION. The UNLV School of Dental Medicine acquired 36 Von Hagens plastinated head and neck specimens to be used in the first semester “Head and Neck Anatomy and Neuroscience” course. The 2020-entry class was the first cohort of students to supplement their lecture-based anatomy curriculum with human specimens. From a student perspective, there was trepidation regarding the change and workload addition as previous cohorts were successful on their board exams and gaining employment. Due to COVID-related considerations, students did not have the opportunity to review specimens after their initial laboratory. METHODS. As a means to supplement for the lack of in-person review, brief recorded cadaveric tutorials were prepared using the plastinated dissections. After the administration of two practical exams a survey containing Likert-scale questions on the effectiveness of the tutorials was administered. Informal feedback was also collected face-to-face in an office hours setting. SUMMARY. Surveys revealed that 100% of students assessed ( $N=40$ ) found the tutorials to be helpful overall and impactful on their retention of the presented content. 97.5% of students found the tutorials to be clinically relevant and the appropriate length of time (3-8 minutes). Verbal reports documented that the ability to conceptualize the three-dimensional anatomy was enhanced and practical scores were greatly improved. CONCLUSIONS. Previously, similar tutorials have been prepared on wet dissections and although they were deemed helpful in other clinical programs (PA and PT) it is hypothesized that the length was too long and details clouded the foundational message. Utilization of plastinated specimens opposed to wet dissections was also deemed advantageous by faculty as the plastination process eliminates the presence of adipose tissue in the dissection plane. This tissue would typically obscure structures and planes in wet dissection and would require substantial time to completely remove. Pandemic considerations presented challenges for students to review specimens making these brief cadaveric tutorials, displaying clean dissections with absolutely no adipose tissue, essential to the students’ ability to conceptualize and retain the content for the course assessments and future national licensure.

IMMONEN, Jessica A., and Joshua M. POLANSKI. School of Dental Medicine, University of Nevada, Las Vegas, NV, 89106, USA.  
Variable Presentation of the Pyramidal Lobe of the Thyroid Gland in Plastinated Dissections.

INTRODUCTION. The pyramidal lobe of the thyroid gland is a remnant from the embryological descent of the gland; it typically emanates off the isthmus and may contain a superior fibrous extension. It may be detached from the thyroid gland or it may present in two or more parts. RESOURCES. Thyroid glands were assessed for the presence of pyramidal lobes on 36 Von Hagens plastinated head and neck specimens; 22 specimens had an isthmus of the gland present that could be assessed. DESCRIPTION. 14/22 assessable specimens demonstrated a pyramidal lobe (64%) and half of these specimens demonstrated a superior fibrous extension from the proximal glandular component of the lobe. There was substantial variability in the lengths of the glandular component of the pyramidal lobes (4 mm to 66 mm; average of  $23.9\text{mm} \pm 18.2\text{mm}$ ). 7 specimens ascended to the level of the hyoid bone (50%), 3 to the laryngeal prominence (21%), 2 to the thyroid cartilage inferior to the prominence (14%), 1 lobe crested the anterior arch of the cricoid cartilage (7%) and 1 lobe’s termination site could not be noted (7%). A single specimen with a fibrous extension demonstrated a second glandular segment (10 mm in length) which wrapped around the anterolateral convexity of the thyroid cartilage. SIGNIFICANCE. This assessment is significant as it is the first to discuss the superior extension of the pyramidal lobe beyond a single patient case report while also noting a sporadic occurrence, a specimen with a second glandular component placed superiorly in the pretracheal region. Thyroidectomy may be necessary in the event a patient presents with thyroid pathology and an extrathyroidal extension has been documented to have predictive value specific to the reoccurrence of papillary thyroid carcinoma. It is necessary for surgeons to be aware of the prevalence of various types of pyramidal lobes and these findings may adjust clinical expectations for the presence and location of extrathyroidal tissue.

## Abstracts - ePoster Presentations continued

\*IWANAGA, Joe<sup>1,2,3</sup>, and R. Shane TUBBS<sup>1</sup>. <sup>1</sup>Department of Neurosurgery, Tulane University School of Medicine, New Orleans, LA, 70112, USA; <sup>2</sup>Dental and Oral Medical Center, Kurume University School of Medicine, Kurume, Fukuoka, 830-0011, Japan; <sup>3</sup>Division of Gross and Clinical Anatomy, Department of Anatomy, Kurume University School of Medicine, Kurume, Fukuoka, 830-0011, Japan.  
Localizing the Nerve to the Mylohyoid Using the Mylohyoid Triangle.

INTRODUCTION: The nerve to the mylohyoid muscle has been well studied but there are no specific anatomical landmarks for identifying it. Therefore, we aimed to identify anatomical landmarks for localizing the nerve to the mylohyoid muscle in the submandibular region. METHODS: Sixteen sides from eight embalmed Caucasian cadaveric heads were used in this study. The mean age at the time of death of the specimens was 80.3 years. The anterior and posterior bellies of the digastric muscle, submental artery, and mylohyoid muscle were dissected to verify their relationships with the nerve to the mylohyoid muscle. SUMMARY: The nerve to the mylohyoid muscle was found medial to the submental artery, lateral to the anterior belly of the digastric muscle, and anterior to the posterior border of the mylohyoid muscle on all sides. CONCLUSIONS: Herein, we identified what we term the mylohyoid triangle. This anatomical region can help localize the nerve to the mylohyoid muscle. The authors sincerely thank those who donated their bodies to science so that anatomical research could be performed. Results from such research can potentially increase mankind's overall knowledge that can then improve patient care. Therefore, these donors and their families deserve our highest gratitude.

\*KANDINATA, Natalie N.<sup>1</sup>, Terrence R. MITCHELL<sup>2</sup>, Christian X. TIMMIS<sup>2</sup>, and Maxx C. TOLER<sup>2</sup>. <sup>1</sup>Cape Fear Valley Medical Center, Fayetteville, NC, 28304, USA; <sup>2</sup>Department of Anatomy, Jerry M. Wallace School of Osteopathic Medicine, Campbell University, Lillington, NC, 27546, USA.

Lumbar Paraspinal Compartment Syndrome: Body Size Scaling and Fasciotomy Site Selection.

INTRODUCTION. Compartment syndrome is characterized by pressure greater than 30 mmHg in a space enclosed by a fascial membrane containing muscles, neurovasculature, and lymphatics. While it most often presents in the extremities, it can occur in any muscular compartment. Lumbar paraspinal compartment syndrome is less common, but increasingly reported in the literature. While some mild forms of paraspinal compartment syndromes can heal with supportive treatment that decrease inflammation, others may require a fasciotomy. Most orthopedic and neurosurgeons in the past have opted to use the Wiltse paraspinal paramedian approach, in which an incision is made 3 cm lateral to midline to avoid vasculature in the area to promote better wound healing. However, the relationship between body size and paraspinal compartment dimensions is not well understood. METHODS. This study examined 40 cadavers previously dissected by medical students and compared easily attainable measures of body size (e.g. height) to lumbar paraspinal compartment width (LPCW) at the spinous processes of the five lumbar vertebrae. SUMMARY. A series of linear least-squares regressions found a statistically significant, but weak correlation between height and right LPCW at the L1 (R-square: 0.26) and L2 (R-square: 0.21) vertebrae and no correlation of inter-Posterior Superior Iliac Spine width and LPCW. LPCW ranged from 10.5-6.3cm at L1 and 9.5-5.9cm at L2. Dimensions at the L5 vertebral level were much smaller and more varied than L1-4. CONCLUSIONS. Based on these findings, surgical incisions to access the lumbar paraspinal compartment could be made as far as 5cm lateral to midline between the L1 and L4 vertebral levels and still fall within the minimum observed dimensions of the compartment. Further study to establish other relevant metrics of body size and neurovascular position to tailor surgical site selection are recommended.

KAR, Rekha<sup>1</sup>, PARKER, Morgan<sup>1</sup>, Roland PAQUETTE<sup>2</sup>, and Alan SAKAGUCHI<sup>1</sup>. <sup>1</sup>Department of Cell Systems and Anatomy, Joe R. and Teresa Lozano Long School of Medicine, San Antonio, TX 78229, USA; <sup>2</sup>Department of Physician Assistant Studies, School of Health Professions, University of Texas Health at San Antonio, San Antonio, TX 78229, USA.

Integration of Ultrasound in Anatomy Education for Physician Assistant Students: A National Survey.

INTRODUCTION. Though many medical schools are increasing exposure to ultrasound (US) in their curriculum, to-date, Physician Assistant (PA) programs offer little or no US training. PA clinical practice is related to that of a physician, and they can be expected to perform procedures and diagnostics similar to physicians. Therefore, it is important for PA programs to integrate US into their curriculum. PA programs across North America have expressed a general interest and need to integrate US into PA education. However, there is no consensus among PA programs on the method of integrating US into their curriculum, nor is their agreement on educational milestones concerning US understanding and usage. METHODS. An anonymous survey was sent to PA program directors across the United States to assess the attitude and status of US integration into their respective programs and their education of clinical anatomy. Survey response was received from 31 of the 280 programs solicited throughout the United States. SUMMARY. 84% of survey respondents felt that it is important for PA students to get exposure to US before they begin clinical rotations. The majority of respondents (65%) disagreed with the statement that the current state of US throughout PA curriculum is adequate and does not need modification. 42% of respondents strongly, and 35% agreed that the integration of US into anatomy curriculum was

*continued on next page*

## Abstracts - ePoster Presentations continued

important. 45% of respondents strongly agreed, and 32% agreed that US integration into anatomy curriculum enhances a student's understanding of anatomy. 19% of survey respondents strongly agreed and 35% agreed that their current institution would be interested in integrating US into anatomy curriculum for PA students. CONCLUSIONS. This survey results indicate a growing interest among PA programs across the United States to integrate ultrasound into anatomy education and provide an initial set of suggested milestones for US training in the undergraduate PA curriculum.

\*KLEEHAMMER, A. Chase, Kale B. DAVIDSON, and Brent J. THOMPSON. Department of Anatomy, Lincoln Memorial University-DeBusk College of Osteopathic Medicine, Harrogate, TN, 37752, USA.

### How Many Branches Does the Pectoral Nerve Really Have? Rethinking the Pectoral Nerve Nomenclature.

INTRODUCTION. The textbook description of the pectoral nerves consists of medial and lateral pectoral nerves originating from the medial and lateral cords of the brachial plexus. However, studies have described significant variation in the origins and branching of the pectoral nerves. The objective of this study was to assess the frequency of common pectoral nerve patterns and propose an accurate and intuitive nomenclature for description of the pectoral nerves. METHODS. Previously dissected anatomical donors were examined to identify the frequency of common variations of the pectoral nerves. Observations were done bilaterally, with each side considered an independent observation. Dissections were photographed, and the pectoral nerves' origins, course and branching were recorded. SUMMARY. Of the brachial plexuses observed, 29 had 3 distinct pectoral nerve origins, 20 had 2 distinct nerve origins, and 1 had a single pectoral nerve origin. In most cases, 3 distinct pectoral nerves were observed originating from: the superior anterior division (SAD), the middle anterior division (MAD), and the inferior anterior division (IAD). In all observations, the pectoral nerves had terminal branches innervating 3 distinct regions: the superior or clavicular pectoralis major muscle (PM), the sternal or middle PM, and the costal or inferior PM. CONCLUSIONS. In contrast to the accepted description of 2 pectoral nerve branches arising from the cords of the brachial plexus, we most frequently observed 3 distinct pectoral nerves arising from the SAD, MAD and IAD and coursing to 3 distinct regions of the pectoralis major in a superior to inferior spatial arrangement. Given these findings, an intuitive new nomenclature of superior pectoral nerve, middle pectoral nerve and inferior pectoral nerve to describe their origins, course and spatial relationship would likely be helpful to anatomists, students, and clinicians.

\*KOZLOWSKI, Benjamin J.<sup>1</sup>, John TRAN<sup>1</sup>, Nimish MITTAL<sup>2</sup> and Anne AGUR<sup>1,2</sup>. <sup>1</sup>Division of Anatomy, Department of Surgery, University of Toronto, Toronto, ON, M5S 1A8, Canada; <sup>2</sup>Department of Medicine, Division of Physical Medicine and Rehabilitation, University of Toronto, Toronto, ON, M5S 1A8, Canada.

### Are Intra-Articular Injections of the Shoulder Joint Always Intra-Articular?

INTRODUCTION. Image guided rotator interval corticosteroid injections of the shoulder joint are commonly used to manage pain associated with adhesive capsulitis. Clinically, two injectate spread patterns have been observed, one that is intra-articular and another that is intracapsular but extra synovial and seems to follow the tendon of the long head of biceps. The purpose was to determine the staining patterns of intra-capsular (extra-synovial) and intra-articular structures following an ultrasound guided rotator cuff interval injection. METHODS. Five lightly embalmed specimens were injected with 5 mL of methylprednisolone/methylene blue dye. Using ultra-sound guidance, the needle was inserted in the rotator interval, between the tendon of the long head of biceps and superior glenohumeral ligament. Meticulous serial dissection was carried out to document the extra- and intra-capsular structures that were stained. Specimens were photographed. The frequency of intra-capsular (extra-synovial) and intra-articular injections were compared. SUMMARY. In three of five specimens, intra-articular spread into the joint cavity was observed, and in two specimens, intra-capsular (extra-synovial) spread was observed. In the three specimens with intra-articular spread, the anterior, posterior, and superior surfaces of the fibrous capsule were strongly stained, in addition to intra-articular staining of the entire head of the humerus, glenoid fossa, and synovial membrane lining the joint. In the two specimens with the extra synovial spread pattern light staining of the antero- and posterosuperior parts of the capsule was noted along with spread in this area internally along the synovial membrane. No structures had dark dense staining. CONCLUSIONS. These preliminary results indicate differing frequencies of intra-articular staining pattern depending on the location of the needle tip on injection. Some intended intra-articular injections may not reach the joint cavity, possibly influencing outcomes.

## Abstracts - ePoster Presentations continued

\*KRATOCHVIL, Taylor J.<sup>1</sup>, Kaeli K. SAMSON<sup>2</sup>, and Travis L. MCCUMBER<sup>3</sup>. <sup>1</sup>College of Medicine, University of Nebraska Medical Center, Omaha, NE, 68198, USA; <sup>2</sup>College of Public Health, University of Nebraska Medical Center, Omaha, NE, 68198, USA; <sup>3</sup>Department of Genetics, Cell Biology, and Anatomy, University of Nebraska Medical Center, Omaha, NE, 68198, USA.

### eModule-Based Musculoskeletal Anatomy Education Amidst Curricular Change.

**INTRODUCTION.** Undergraduate medical education is undergoing dramatic curricular reform to better integrate basic and clinical science. An integrated curriculum was implemented at the University of Nebraska Medical Center (UNMC) in 2017 and curricular revisions were made in 2018. After integration and revision, a decline in student performance on distal upper limb (DUL) anatomy content was noted. The purpose of this study was to 1) analyze first-year medical student exam performance on DUL content, 2) identify curricular and environmental variables deleterious to exam performance, and 3) evaluate the efficacy and learner perception of a supplemental DUL eModule. **METHODS.** From 2018 to 2020, a DUL eModule was progressively integrated into UNMC's gross anatomy curriculum. eModule users were asked to complete a short survey evaluating the tool for qualitative analysis. Quantitative outcomes were assessed using the practical (constructed response) examinations of 525 students between 2017-2020. Examination data was plotted to evaluate student performance and detect intra- and inter-cohort trends. **SUMMARY.** Our findings suggest that since 2018, first-year medical students have lower performance trends on DUL examination questions relative to the proximal upper limb. This trend was most notable in students scoring within the first quartile. Both planned and pandemic-related curricular changes appear to have exacerbated this decline in DUL exam performance during the Fall of 2020. Initial analysis and qualitative feedback grant insight into the effect of curricular change and eModule integration on learning outcomes. **CONCLUSIONS.** Review of student performance is necessary amidst curricular reform. While learning outcomes are subject to several environmental variables, trends in exam performance during DUL eModule implementation warrant further investigation. Future analysis in 2021 will attempt to limit curricular variables and isolate the efficacy of the DUL eModule.

\*LAU, Judy S., Nicholas R. STANGE, Lauren T. SU, Nadia F. SIRAJUDDIN, Nicholas L. NGUYEN, Brittany E. WICHMAN, Daniel T. DALY, and Yun TAN. School of Medicine, Saint Louis University, St. Louis, MO, 63104, US.

### Relationship Between Accessory Fissures and Bronchopulmonary Segment Location: A Cadaveric Study.

**INTRODUCTION.** Abnormal pulmonary development may result in variations in morphological fissures in the lung such as absent or accessory fissures. This study investigated the relationship of the variations in fissure morphology to the location of bronchopulmonary segments in lungs. **METHODS.** Cadaveric specimens were obtained through the Gift Body Program at the Saint Louis University School of Medicine. A total of 63 lungs from 32 cadavers were inspected. Any lungs observed with fissure variations were dissected and the bronchopulmonary segments were identified. Bronchopulmonary segments were numbered based on the Jackson and Huber classification. **SUMMARY.** Accessory fissures were present in 15 lungs (23.81%, 4 left, 11 right). Of these, 7 with the most notable abnormalities (4 left, 3 right) were dissected with vessels removed. Of the 4 dissected left lungs, 3 left lungs had one incomplete accessory fissure: one between segment B6 and the rest of the lower pulmonary segments, and the other two between segments B3 and B4. The fourth left lung had a complete accessory fissure between segments B3 and B4. Of the 3 dissected right lungs, one had a complete vertical accessory fissure separating segments B4 and B5 which has not been reported in the literature. Two right lungs contained an incomplete accessory fissure: one fissure separated segment B6 from the rest of the basal pulmonary segments, and another separated segments B4 and B5. **CONCLUSIONS.** Identifying the location of bronchopulmonary segments in lungs with fissure variations is of interest as it impacts preparation for pulmonary surgeries, post-operative complications, and the location of lung infections and pathologies. Understanding anatomical variations of both lung fissures and bronchopulmonary segment locations provides academic value and may be greatly beneficial for medical professionals in the fields of surgery, clinical medicine, and radiology.

\*LIN, Dustin C., Bailey S. BUNCH, Raissa ZUIM DANTAS DE SOUZA, Dickson T. CHEN, Jinyan ZHOU, Ann C. ZUMWALT, Jonathan J. WISCO. Boston University School of Medicine, Boston, MA 02118, USA.

### Effectiveness of Medical Gross Anatomy Pedagogical Tools for Teaching During the COVID-19 Pandemic.

**INTRODUCTION.** Medical institutions have been forced to modify gross anatomy pedagogy in order to comply with the health restrictions imposed by the novel coronavirus (COVID-19). Boston University School of Medicine (BUSM) is one such institution that temporarily restructured its course. We replaced cadaveric dissection activities with prosections and a greater emphasis on a flipped classroom model. This study investigates the effectiveness of new course materials developed to aid these curriculum changes. **RESOURCES.** Course materials were developed for three purposes: (1) for preparation before lab (orientation videos and Complete Anatomy screens); (2) for guidance during lab (laboratory guides); (3) for review after lab (Zoom recitation sessions). We asked students questions regarding the most helpful and least helpful aspects of the course materials. We performed a grounded theory

## Abstracts - ePoster Presentations continued

thematic analysis of students' responses (81/160, 50% response) to qualitative survey questions and to focus group questions (16 students who self-selected between 4 different sessions). DESCRIPTION. Data from both the survey and focus groups demonstrated that the vast majority of students strongly agreed or agreed that the materials helped them navigate through learning gross anatomy. However, students expressed that lab guides were used mostly for post-lab review as opposed to the intended purpose of guidance during lab. Students within all focus groups overwhelmingly touted the value of and advocated for Zoom recitation sessions, with many stating that they were imperative to course success and comprehension of material. SIGNIFICANCE. We propose that the benefits of flipped-classroom learning are augmented via the utilization of course materials that students perceive as time saving, useful integration of information, pertinent to their exam performance, and combined with cadaveric prosection emphasizes the benefits of flipped-classroom learning to help students learn gross anatomy effectively and efficiently during the pandemic - and beyond.

\*LIN, Dustin C., Raissa ZUIM DANTAS DE SOUZA, Ann M. FEFFERMAN, Bailey S. BUNCH, Jonathan J. WISCO, and Ann C. ZUMWALT. Boston University School of Medicine, Boston, MA, 02118, USA.

### Unusual Bilateral Variation of the Flexor Digitorum Accessorius Longus Muscle.

INTRODUCTION. During routine anatomical dissection, we encountered an unusual variant of the flexor digitorum accessorius longus (FDAL) muscle present bilaterally in a 79-year-old male human cadaver. The FDAL has a prevalence of 2-8% and is more common in males. RESOURCES. We documented its course and measured the diameter and length of the FDAL muscle belly, and the full length of its tendinous attachments. DESCRIPTION. On both right and left legs, the FDAL originated from the proximal posterior fibula and distal one-third of the flexor hallucis longus muscle. The tendon had a distal attachment on the flexor digitorum longus (FDL) tendon and traveled with the FDL tendon as it inserted on the third distal phalanx. The left FDAL full length was 42.54 cm; the length of the muscle belly was 16.26 cm; and the circumference of the muscle belly was 4.44 cm. The right FDAL full length was 44.20 cm; the length of muscle belly was 12.06; and the circumference (belly) was 4.44 cm. Surrounding musculature and neurovasculature follow standard anatomical courses. SIGNIFICANCE. The presence of the FDAL suggests that the donor may have experienced tarsal tunnel syndrome bilaterally, described as a compression neuropathy of the tibial nerve to the plantar muscles of the foot. People with tarsal tunnel syndrome have chief complaints of gait abnormalities and numbness. This case provided a unique opportunity to observe the anatomy of this condition.

LOPEZ-OJEDA, Wilfredo<sup>1,2</sup>, and Robin A. HURLEY<sup>2</sup>. <sup>1</sup>VISN 6 MIRECC, W.G. (Bill) Hefner VA Medical Center, Salisbury, NC, 28144, USA; Department of Psychiatry and Behavioral Medicine, Wake Forest Medical School, Winston-Salem, NC, 27103, USA.

### Extended Reality Technologies in Medical Education and Clinical Practice.

INTRODUCTION. Virtual reality (VR) is a suitable instructional method utilized to teach anatomy. In addition, augmented reality (AR) and mixed reality (MR) are extended reality (XR) technologies progressively being applied as valuable instructional resources in medical education (i.e., basic sciences) and clinical practice (e.g., orthopedy, surgery, etc.). RESOURCES. Recent clinical and research reports concerning XR technologies, particularly relevant to clinical care and medical education and training, were reviewed and summarized. The most relevant information and functional descriptions including advantages and disadvantages of XR Innovations were integrated into graphic-rich instructional resources. DESCRIPTION. There is a plethora of peer-reviewed reports regarding the application XR technologies in medical training and clinical care. These technologies represent a suitable option in 3-D imaging and clinical anatomy pedagogies. XR innovations have the potential to increased learning and student engagement by graphically extrapolating medical imaging concepts (e.g., anatomical structures, pathophysiology). They also foster the application of clinical knowledge translatable to the "bedside" helping both, the patients and healthcare practitioners. SIGNIFICANCE. Reports in the literature pose important differences and functional nuances among the XR technologies. The potential for higher integration of basic science concepts and clinical sciences applications to improve medical training and clinical outcomes is a major advantage. However, the high cost, logistics and cumbersome design of most digital lenses, along with the limited clinical integration of software remains a challenge for their application in medicine. AR and MR subset innovations appear to have higher potential to supplement the current practices in medical education and clinical practice.

## Abstracts - ePoster Presentations continued

\*LUFLEER, Rebecca S.<sup>1</sup>, Carolin CARDAMONE<sup>2</sup>, and Jeffrey K. MARCHANT<sup>1</sup>. <sup>1</sup>Tufts University School of Medicine, Boston, MA 02111, USA; <sup>2</sup>Tufts University, Medford, MA 02155, USA.

### The Utility of Virtual and In-Person Pedagogy in the Anatomy Lab.

INTRODUCTION. While debate over effective pedagogical methods for teaching gross anatomy is ongoing, under Covid-19 all educational content used virtual delivery. This study aims to compare the features and quantify the utility of face-to-face instruction to virtual anatomy instruction of cadaveric anatomy. METHODS. Participants included two cohorts of Physician Assistant students: Cohort 1, clinical students who completed the traditional Clinical Anatomy I and II courses in person (2019), and Cohort 2, preclinical students who completed the traditional Clinical Anatomy I course in person and the virtual Clinical Anatomy II course (2020). Cohort surveys on confidence in anatomy skills and knowledge, and perceptions of learning in a cadaver lab were collected and Clinical Anatomy II exam performance was compared. Quantitative data were analyzed using Mann Whitney U and t-tests, qualitative data were analyzed using grounded theory. SUMMARY. There were no significant differences in confidence in ability to locate structures or knowledge after lectures and labs (in-person vs virtual), or perceptions of learning in a cadaver lab. Cohort 2 students were more confident in their knowledge of the clinical applications of anatomy after experiencing virtual workshops ( $p=0.045$ ). The majority (71%) of these students agree/strongly agree that a cadaveric lab experience will lead to longer retention of anatomy, but 68% also felt some structures visualized with virtual tools wouldn't be possible in a cadaver. Cohort 2 students also scored significantly higher on the extremities exam and course final grade ( $p=0.006$ ,  $p=0.03$ ). Thematic analysis revealed 7 themes that provided insight into the benefits of a cadaver lab experience. CONCLUSIONS. While cadaveric instruction is preferred by students for insight that extends beyond exams, virtual lab environments provide a useful resource for student learning and therefore a complementary approach may provide the most benefit.

\*MAGLASANG, Maurice N. A., Shivika AHUJA, Yun TAN, and Daniel T. DALY. Center for Anatomical Science and Education, Department of Surgery, School of Medicine, Saint Louis University, St. Louis, MO, 63104, USA.

### A Unique Case of Extrarenal Calyces and Associated Vascular Variations.

INTRODUCTION. Several urogenital and vascular anomalies were associated with an 81-year-old female cadaver. During routine dissection, three extrarenal calyces, an accessory renal artery originating directly from the abdominal aorta, and a circumaortic renal vein were observed at the left renal hilum. RESOURCES. The cadaver was donated to the Saint Louis University Gift Body Program. DESCRIPTION. The typical renal anatomical structures were identified at the hilum of the left kidney, from anterior to posterior, as the renal vein, renal artery, and ureter. Three extrarenal calyces exited the hilum of the left kidney and united to form the pelvis, then narrowed and became the ureter which descended 21.5 cm to empty into the bladder. The accessory renal artery originated from the lateral aspect of the abdominal aorta and was 7.3 cm below the left renal artery. A corresponding accessory renal vein, identified as a circumaortic vein, left the hilum 4.5 cm below the left renal vein and traveled posterior to the abdominal aorta to drain into the inferior vena cava. SIGNIFICANCE. Extrarenal calyces are rare among urogenital tract variations. They can be associated with other embryological abnormalities such as renal ectopia, horseshoe kidney or malrotation and clinical manifestations such as pelviureteric junction obstruction and hydronephrosis. Compression of the accessory renal artery can cause decreased blood flow to the inferior pole of the left kidney, thereby causing fibrosis, atrophy, or renal failure. The retro-aortic path of the circumaortic renal vein has been associated with posterior nutcracker phenomenon, hematuria, left renal vein thrombus formation, and renal vein hypertension. This unique combination of a collecting system anomaly and extrarenal vessel variations could have significant implications in abdominal surgery.

\*MASSOUD, Tarik F., and Paraag R. BHATT. Division of Neuroimaging and Neurointervention, Stanford Initiative for Multimodality neuro-Imaging in Translational Anatomy Research (SIMITAR), Department of Radiology, Stanford University School of Medicine, Stanford, CA 94305, USA.

### Torus Tubarius MRI Anatomy and Morphometry Applicable to Eustachian Tube Interventional Procedures.

INTRODUCTION. The nasopharyngeal torus tubarius (TT) is formed by raised mucosa overlying the cartilaginous Eustachian tube (ET) orifice. ET dysfunction (ETD) causes failure to open and ventilate the middle ear, whereas patulous ET results in its failure to close. ET balloon tuboplasty and stenting, or endoscopic/percutaneous injection of bulking agents into the TT are respective treatment options. The relative contribution of the surface mucosa covering the TT to the overall size of the TT has not been studied, and is potentially relevant to consider prior to ET and TT interventions. We investigated normative age-related MRI morphometrics of the ET, TT, and TT mucosa in healthy subjects. METHODS. On axial postcontrast T1 MRIs of 60 individuals we measured bilateral cartilaginous ET lengths, TT cartilage thickness, and maximum thickness of surface mucosa on TTs and inferior turbinates. We tested the effect of sex as an independent variable using ANOVA, and performed linear regression with age as an independent variable.

*continued on next page*

## Abstracts - ePoster Presentations continued

We calculated linear correlations between TT and ipsilateral and contralateral inferior turbinate mucosal thickness. Significance was set at  $p < 0.05$ . SUMMARY. Subjects were F:M=31:29 and mean age 56.6 years. Mean cartilaginous ET length and TT thickness were 17.0mm and 5.0mm, respectively. Mean TT and inferior turbinates maximal mucosal thickness were 3.1mm and 4.0mm, respectively. Males had mean longer ETs (17.7mm) versus females (16.3mm) ( $p=0.006$ ). TT mucosal thickness positively correlated with age in females ( $p=0.01$ ). There was also a positive correlation between right TT and contralateral left inferior turbinate mucosal thickness ( $p=0.037$ ). CONCLUSIONS. This is likely the first report of normative MRI dimensions of the TT and its mucosa for pre-procedural planning of ET interventional procedures. Future temporal analysis of potential TT mucosal physiological variations akin to those of the 'nasal cycle' may reveal a new factor to better understand ETD.

\*MASSOUD, Tarik F., and Nicholas S. BATES. Division of Neuroimaging and Neurointervention, Stanford Initiative for Multimodality neuro-Imaging in Translational Anatomy Research (SIMITAR), Department of Radiology, Stanford University School of Medicine, Stanford, CA 94305, USA.

### Skull Diploic Venous Lakes as Potential Receptacles for CSF Diversionary Shunts: MRI Anatomy Study.

INTRODUCTION. Use of the skull diploic space (SDS) to receive CSF shunting has been proposed previously. Diversion into the SDS would use intracranial pressure to propel CSF through cancellous bone toward diploic veins (DVs) and into dural sinuses. We hypothesized that the largest DVs (forming diploic lakes [DLs]) seen on imaging might in theory be the most amenable locations for direct cannulation or nearby insertion of CSF diversionary devices. No prior studies have specifically addressed DL anatomy and frequency. We investigated normative MRI anatomy and morphometry of the DVs and DLs to identify potential sites for intraosseous SDS infusion. METHODS. We retrospectively analyzed orthogonal postcontrast BRAVO MR images of 40 normal subjects for bilateral DV configurations (named and categorized by 6 predefined types), length of longest DVs (mm), areas of widest segments of DVs ( $\text{mm}^2$ ), presence of DLs (i.e. DVs  $>3$  mm in cross section), anatomical skull locations, right-left symmetry, and distances of DLs from external surgical skull landmarks. We examined associations between DV/DL dimensions and subject sex and age. SUMMARY. Subjects were F:M=27:13 and mean age of 48.4 years. We found among 80 bilateral DVs that they were categorized as: Spider (4), thousand lakes (2), serpentine (5), coronal (39), bonsai (10), and hybrid (20) in shape, as illustrated in this exhibit. The longest DVs were a mean 41.5 mm, and DL mean areas were  $12.67 \text{ mm}^2$ , both greater in males but with no differences in those aged below and above 50 years. DLs were seen in 17 (42.5%) subjects. DVs were most common in the parietal bones and were bilaterally symmetrical in 24 subjects. DVs/DLs were mean distances of 15 mm from pterion and 56.5 mm from lambda. CONCLUSIONS. This is the first report of normative MRI dimensions of the DVs and DLs. We studied these in adults prior to similar future comparative studies in children, and further evaluation of the SDS as a distant receptacle for CSF diversion.

MASTERS, Myka D.<sup>1</sup>, Kobe J. KISLING<sup>1</sup>, Jiyoung YUN<sup>1</sup>, Farida MEHRHOFF<sup>1</sup>, Alla G. BARRY<sup>1</sup>, Shelby K. KUHNERT<sup>1</sup>, Mary K. KILMER<sup>1</sup>, and Dmitriy E. TSYPLAKOV<sup>2</sup>. <sup>1</sup>Department of Biology and Environmental Health, Missouri Southern State University, Joplin, MO, 64801-1595, USA; <sup>2</sup> General Pathology Department, Kazan State Medical University, Kazan, 420012, Russian Federation.

### Morphometric Analysis of the Superior Ophthalmic Vein: A Cadaveric Study.

INTRODUCTION. The superior ophthalmic vein (SOV) dilation has been drawing the attention of practicing physicians due to its significance in the early manifestation of neurovascular diseases. A broad range of SOV diameter, fluctuating between 0.5 mm to 5 mm, has been reported. Discrepancies between previous studies regarding the morphometric parameters of SOV cause a potential delay in diagnosis. This study aimed to categorize the morphological pattern of SOV and develop objective criteria for the recognition of dilated SOV. METHODS. Cadavers were selected based on the absence of factors associated with SOV dilation. Fourteen orbits of seven formalin-preserved human cadavers (age  $80.8 \pm 18$ ) were dissected to expose SOV. The branching pattern and length of the veins were documented before collecting samples. Samples from the anterior, middle, and posterior SOV segments were obtained for H&E staining and analysis with a Stereo Microscope. All images were analyzed qualitatively and quantitatively. SUMMARY. Unreported variation of SOV trifurcating at its exit point was observed. No significant relationships between age, diameter, and length were identified. The mean SOV diameter was  $2.063 \text{ mm} \pm 0.712$ . There was no consistent pattern established between anterior, middle, and posterior segments' diameter. Thus, no segment should be preferred over others. A linear association between average diameter measured from pictures taken with the Stereo Microscope and histological slides ( $p=0.00338$ ,  $r^2=0.3874$ ,  $n=20$ ) was observed. The equation of the line could be used to determine morphometrical parameters based on histological data. CONCLUSIONS. The present study did not consider bilateral structures as independent measures in order to eliminate pseudoreplication to obtain the most accurate results. An unreported variation of SOV with posterior trifurcation may have implications in neurosurgery using this vein to approach the cavernous sinus.

## Abstracts - ePoster Presentations continued

\*MEMAR, Shayan A., Caroline VANSICKLE, Sara FUNK, Jeremy J. HOUSER, and Shanu MARKAND. Department of Anatomy, A.T. Still University Kirksville College of Medicine, Kirksville, MO, 63501, USA.

### Anatomical Variations in the Origin and the Course of the Cystic Artery: A Cadaveric Approach.

INTRODUCTION. Understanding potential anatomical variations of the location and the course of the cystic artery (CA) relative to the cystohepatic triangle (Triangle of Calot) may mitigate the incidence of complications during laparoscopic cholecystectomies, or other procedures involving the hepatobiliary system and surrounding structures. RESOURCES. Cadavers obtained from the Gift of Body Program at A.T. Still University Kirksville College of Osteopathic Medicine were dissected in order to study CA anatomy. Of the 25 midwestern, white donors, this study focused on the 18 with gallbladders (11 male, 7 female; average age =  $72 \pm 18$  years). DESCRIPTION. Portal triads were carefully dissected and photographed. Origin, branching pattern, and course of the CA were documented. The length and diameter of the CA were measured using calipers. The CA was present within the cystohepatic triangle in all 18 donors. The CA originated from the right hepatic artery in 17 cases and the left hepatic artery once. The average length and diameter of the CA were  $20.99 \pm 5.95$  mm and  $1.59 \pm 0.39$  mm. The CA crossed the common hepatic duct (CHD) anteriorly in 4 cadavers and posteriorly in 2 cadavers. In the remaining 12 individuals, the proper hepatic artery crossed the CHD instead. SIGNIFICANCE. Familiarity with the variation in the course and origin of the CA, which is demonstrated by these results, may have implications for laparoscopic surgical procedures of the hepatobiliary system (e.g. hemorrhage leading to conversion to an open procedure) and increase the overall safety of these procedures. Notably, the artery was consistently located within the cystohepatic triangle.

\*MESSER, Diana L.<sup>1</sup>, and Saskia D. RICHTER<sup>2</sup>. <sup>1</sup>Department of Anthropology and Sociology, Western Carolina University, Cullowhee, NC, 28786, USA; <sup>2</sup> Department of Kinesiology and Applied Physiology, University of Delaware, Newark, DE, 19716, USA.

### Anatomical Basis for the Ventral Arc of the Os Pubis: Clinical and Forensic Implications.

INTRODUCTION. The ventral arc, defined as a ridge of bone on the ventral surface of the pubic bone, has been described as a reliable indicator of biological sex, primarily present in females after adolescence. However, the anatomical basis for this osteological landmark is not well defined and the few existing studies that examine soft tissue correlations do not agree. METHODS. Eleven commonly used anatomical textbooks and atlases were reviewed to assess possible muscle attachments. In addition, a search for scientific articles that discuss the ventral arc and soft tissue correlations was conducted using PubMed (n=6), Web of Science (n=26), and MEDLINE (n=7) using the search term "ventral arc." All articles not pertaining to the os pubis were excluded. After removing duplicates, a total of 26 articles were reviewed. SUMMARY. A total of 37 textbooks, atlases, and anatomical journal articles were reviewed. The majority of articles were anthropological and/or forensically oriented (88%; 23/26). The ventral arc was not directly mentioned in any anatomy-specific textbook or atlas. Only 2 reviewed articles addressed possible muscular attachments associated with the ventral arc; these included gracilis, adductor magnus, and/or adductor brevis. There were discrepancies between studies in regards to whether there were morphological differences in muscle attachment between sexes. In addition, one article described the ventral arc as a landmark for identification of the dorsal nerve of the penis/clitoris. CONCLUSIONS. Inconsistencies in anatomical literature exist regarding the specific muscle correlated to the ventral arc. Sexual dimorphism between the soft tissue structures related to the ventral arc may have implications in clinical and forensic contexts. Future studies should clarify muscle attachment(s) at the ventral arc through anatomical dissections and examine potential functional differences between sexes. Confirming the anatomical basis for the ventral arc may further allow for expansion of anthropological sex estimation methods to include the associated muscle insertion sites.

MOISIO, Kirsten C., Roberto LÓPEZ-ROSADO, Lindsay BEEDER, Daniel CHRYST, Jacob JUSTESEN, and Kevin LIAO. Department of Physical Therapy and Human Movement Sciences, Feinberg School of Medicine, Northwestern University, Chicago, IL, 60611, USA.

### A Survey of Students' Preferences on Virtual vs. In-Person Gross Anatomy during COVID-19 Pandemic.

INTRODUCTION. In March 2020 due to COVID-19, the Northwestern Doctor of Physical Therapy (DPT) gross anatomy course quickly converted from in-person lecture/cadaver lab to an all-virtual format. Prior to COVID, students completed 27 in-person lecture/labs where lectures were given in a lecture hall with slides, and labs consisted of a full cadaver dissection in teams of 5. During COVID students completed 3 virtual lectures/labs where lectures were given over Zoom with slides; labs consisted of tagged cadaver photos, the Complete Anatomy App, and Acland Videos. This study assessed students' perceptions and preferences for gross anatomy lectures/lab sessions after converting to an all-virtual format (vs. in person) during COVID. METHODS. A 37-item survey with a 5-point Likert scale anchored by "strongly agree" and "strongly disagree" was sent to DPT students (n=89) via Survey Monkey in November 2020. SUMMARY. Data from 81 students (91% response rate) were analyzed. Of all respondents, 85% preferred in-person lecture to a virtual format, and 96% reported it was easier to maintain focus during in-person lectures vs. virtual sessions. For lab,

*continued on next page*

## Abstracts - ePoster Presentations continued

94% preferred in-person dissection cadaver lab vs. virtual approach. Respondents strongly agreed (89%) with the comment “Being hands-on in cadaver lab helped me better understand anatomy” vs. 15% strongly agreeing that “images of lab material helped me to better understand anatomy.” CONCLUSIONS. A higher level of engagement and interaction might explain DPT students’ strong preference for in-person anatomy lectures. Furthermore, respondents’ marked preference for in-person cadaver labs might be due to hands-on active learning with cadaver tissues, dissecting as a team, and seeing variations among donors. Student learning preferences for in-person anatomy educational sessions and the underlying factors must be taken into consideration and should be explored further when designing effective anatomy curricula post-COVID-19.

\*MURO, Satoru, SachiYuki TSUKADA, Keiichi AKITA. Department of Clinical Anatomy, Tokyo Medical and Dental University, Tokyo, 1138519, Japan.

### Tibial Attachment of Anterior Cruciate Ligament and Relationship with Lateral Meniscus.

INTRODUCTION. The anatomy of the anterior cruciate ligament (ACL) is important for understanding the function and pathology of ACL. It is well known that ACL injury is often combined with a tear or radial displacement of the lateral meniscus (LM), suggesting that ACL is functionally associated with LM. However, the details of their structural relationship remain unclear. This study aimed to clarify the detailed anatomy of the tibial attachment of ACL and its structural relationship with LM. METHODS. Ten knees of 5 cadavers were used for macroscopic and histological examination. SUMMARY. The tibial side of ACL was attached to the anterior intercondylar area. Part of the anterolateral fibers of ACL blended with the superficial layer of the anterior horn of LM (AH). The deep layer of AH extended into the anterior intercondylar area, and its attachment adjoined the lateral border of the tibial attachment of ACL. In the anterior intercondylar area, AH was attached to the lateral area, and ACL was attached to the remaining area. In other words, ACL and AH competed for bone attachment area. In addition, ACL medially attached to the articular cartilage of the medial facet extensively. About 30% of the total area of the tibial attachment of ACL was to the cartilage. In addition, the tibial attachment of ACL was medially bordered with the posteromedial crus of the posterior horn of LM (PH) and posteriorly bordered with the anterolateral crus of PH. CONCLUSIONS. The fiber blending of ACL and LM was demonstrated both macroscopically and histologically. In ACL composition, the anterolateral superficial fibers are responsible for the direct connection to LM, which suggests coordination between ACL and LM in stabilization and motion control. Furthermore, this study clarified the close structural relationship between ACL and LM. AH and PH border the tibial attachment of ACL. The extent and shape of the tibial attachment of ACL seem to depend on the attachment location of AH and PH.

\*NATION, Haley L., and Cassandra L. GINER. Cell Systems & Anatomy, University of Texas Health Science Center at San Antonio, San Antonio, TX, 78229, USA.

### A Cadaveric Study of the Otic Ganglion.

INTRODUCTION. The otic ganglion is a small parasympathetic ganglion located in the infratemporal fossa that innervates the parotid gland. There are very few human studies describing its syntropy, morphology, and branches. The goal of this study was to investigate the prevalence, location, and size of the otic ganglion, the relationship of the otic ganglion to the mandibular nerve, and to determine a dissection approach that is fast, accurate, and causes minimal destruction to surrounding structures. METHODS. 16 adult (5 male and 11 female) cadavers were dissected bilaterally; left and right sides were considered independent. Two dissection approaches were studied: a traditional deep infratemporal fossa dissection and a medial dissection via destruction of the torus tubarius and surrounding nasopharynx structures. SUMMARY. The otic ganglion was present in 21 out of 30 (70%) cadaver samples. 14 (66.6%) otic ganglions presented as the classical description: a separate entity independent from the mandibular nerve. Meanwhile, 7 (33.3%) otic ganglions presented as swellings of the mandibular nerve. All 21 (100%) otic ganglions were located inferior to the foramen ovale, within the infratemporal fossa. The otic ganglions averaged 5.96 mm in height, 6.79 mm in length, and 1.75 mm in width. None of these findings were statistically significant in regards to the sex, age, or side of the cadaver. While the traditional deep infratemporal fossa dissection was faster (average 7 min.), the otic ganglia were best visualized from the medial nasopharynx approach. CONCLUSIONS. Thorough documentation of the human otic ganglia’s prevalence, size, location, and details pertaining to dissection approaches will help students more easily identify the ganglia during gross anatomy dissections and also aid head and neck surgeons, dentists, and neurosurgeons in understanding the intricacies of the structure.

## Abstracts - ePoster Presentations continued

OCCHIALINI, Annette P., Haley L. NATION, Linda Y. JOHNSON, and Omid R. RAHIMI. Department of Cell Systems & Anatomy, UT Health San Antonio, San Antonio, TX, 78229, USA.

### Yes, We Can! In Person, Hands-On Cadaver Dissection During a Pandemic.

INTRODUCTION. During the academic year 2020-21, anatomy faculty faced a daunting task of adapting to the constraints brought on by the pandemic. An urgent need to prioritize safety while maintaining the core value of hands on cadaveric dissection became a sudden necessity. RESOURCES. Our team of course directors, while under extreme and fluid circumstances, successfully designed systems to allow for a dissection based, in-person curriculum for medical (220) and dental (105) students. DESCRIPTION. Several novel adaptations were developed. Tank teams of students (6 or 4) were assigned to rotating pairs of dissection or review teams. An intricate peer-teaching component provided a hand-off of the dissection between groups. To minimize potential exposures, a complex plan of staggered entry and exit provided for physical distancing and limited occupancy. Students and faculty wore face shields and facemasks. A strict self-study protocol allowed students lab access outside of class time. Students effectively embraced these designs and safety protocols and complied extremely well. Didactic content was delivered via synchronous and asynchronous modalities. SIGNIFICANCE. Data suggest that student success, as measured by exam performance, was comparable to previous years. While more students required excused absences when experiencing possible COVID-19 symptoms, to our knowledge, none of the students tested positive due to their time in the laboratory. Three students reported testing positive for COVID-19 following the Thanksgiving break. While these modifications required a significant burden on the faculty's time and effort, novel benefits included improved student to faculty ratio, more time for self-directed study, and the additional responsibility and accountability for tank-mates as both learners and teachers. Ultimately, the students were grateful for the opportunity to participate in a learning environment which still included an in person, hands-on, team-based dissection experience in the gross anatomy laboratory.

\*ODEH<sup>1</sup>, Ahmad O., Sania V. KARIR<sup>1</sup>, Felicia D. LEE<sup>1</sup>, Young T. LEE<sup>1</sup>, Zoe I. HENKES<sup>1</sup>, Larry F. YANG<sup>1</sup>, Dane A. MEYER<sup>1,2</sup>, Yun TAN<sup>1,2,3</sup> and Daniel T. DALY<sup>1,2,3</sup>. Saint Louis University School of Medicine<sup>1</sup>, Center for Anatomical Science and Education<sup>2</sup>, Department of Surgery<sup>3</sup>. Saint Louis, MO, 63108, USA.

### Rare Unilateral Branching Pattern of the Axillary Artery.

INTRODUCTION. In this rare case report, a 77-year-old female cadaver, received through the Saint Louis University Gift Body Program, was observed to have a very unique branching pattern of the axillary artery (AA) in the right arm during routine dissection. RESOURCES. Dissection was performed following Grant's Dissector Manual, 16th edition. DESCRIPTION. The first part of the AA lacked a superior thoracic artery; rather, the lateral thoracic artery (LTA), thoracoacromial trunk (TAT) and a large common trunk (CT) were observed originating from this region. The first branch of the AA was the LTA, from which a small branch coursed medially, supplying the first and second intercostal spaces in place of the superior thoracic artery. Distal to the LTA branching, the TAT originated from the AA. Immediately distal to the TAT, the AA gave off a large CT. Both the medial cord of the brachial plexus and the medial antebrachial cutaneous nerve travel in between the AA and the CT. The CT traveled 4.7 cm, giving off an accessory LTA, a large accessory thoracodorsal artery, and a posterior humeral circumflex artery at distances of 2.2 cm, 3.6 cm and 4.7 cm from the origin of the CT, respectively. The CT continued as the subscapular artery and bifurcated into the circumflex scapular artery and a small thoracodorsal artery (TDA). The TDA traveled with the thoracodorsal nerve to supply the latissimus dorsi muscle. A pectoral artery and the anterior humeral circumflex artery originated from the second and third parts of the AA, respectively. The branching pattern of the AA was typical in the left arm. SIGNIFICANCE. Knowledge of the anatomical variations of the AA is of great clinical significance to anatomists, radiologists, and surgeons, particularly because of the high rate of injury to this artery.

\*OTOBO, Tarimobo M., and Anne M.R. AGUR. Division of Anatomy, Department of Surgery, University of Toronto, Toronto, Ontario, M5S 1A8, Canada.

### Anomalous Conjoint Tendon of Accessory Extensor Pollicis Longus/Extensor Indicis: Function?

INTRODUCTION. The incidence of anomalous extensor pollicis longus (EPL) reported in the literature ranges between 1-5%. Usually, there is one anomalous tendon which joins the EPL tendon in the region of the midshaft of the first metacarpal. In the laboratory, we found an anomalous combined accessory EPL and extensor indicis (EI) tendon, which will be documented in this abstract and the functional/clinical implications considered. RESOURCE. This anomalous muscle-tendon complex was found during dissection of the forearm and hand of a formalin embalmed specimen in the laboratory. DESCRIPTION. The anomalous EPL/EI consisted of a small separate muscle belly that was located between the EPL and EI muscles. The proximal attachment was to the posterolateral surface of the ulna and interosseous membrane. At the junction of the inferior and middle thirds of the ulna, the fiber bundles converged on a tendon which accompanied the extensor digitorum and EI tendons in the fourth extensor compartment of the wrist. The narrow anomalous EPL/EI tendon coursed obliquely superficial to the attachments of extensor carpi radialis longus and brevis to the

*continued on next page*

## Abstracts - ePoster Presentations continued

posteroinferior aspect of the first dorsal interosseous, where it divided into two smaller tendons. The longer medial tendon blended with the dorsal hood of the second digit just lateral to the extensor digitorum longus tendon. The shorter lateral tendon joined the tendon of EPL at the level of the head of the first metacarpal. SIGNIFICANCE. The two anomalous tendons by their attachments to the EPL and dorsal hood will influence the line of action of the EPL and EI/second extensor digitorum tendons. Activation of the anomalous tendons could lead to weak concurrent extension of both the interphalangeal joint of the thumb and proximal and distal interphalangeal joints of the second digit. Clinically, knowledge of this anomaly can inform procedures including electromyography and nerve stimulation when rarely observed findings are reported.

\*PALLEIKO, Benjamin A.<sup>1</sup>, Mark W. MAXFIELD<sup>2</sup>, Karl UY<sup>2</sup>, Feiran LOU<sup>2</sup>, Donald CZERNIACH<sup>2</sup>, Philip COHEN<sup>2</sup>, Nicole CHERNG<sup>2</sup>, and Eustathia Lela GIANNARIS<sup>3</sup>.<sup>1</sup>University of Massachusetts Medical School, Worcester, MA, 01655, USA; <sup>2</sup>Department of Surgery, University of Massachusetts Medical School, Worcester, MA, 01655, USA; <sup>3</sup>Division of Translational Anatomy, Department of Radiology, University of Massachusetts Medical School, Worcester, MA, 01655, USA.

### Development of Robotic Surgery Case Videos for a First-Year Medical Student Anatomy Course.

INTRODUCTION. The increasing prevalence of robotic surgery provides countless hours of surgical footage demonstrating anatomy of multiple organ systems that can be repurposed for medical student education. Intraoperative footage from the robotic camera allows for visualization of clinically relevant anatomy that is often difficult to appreciate and from a different perspective than encountered during routine cadaveric dissections. RESOURCES. A series of five robotic surgery videos were edited and annotated to highlight relevant clinical and surgical anatomy of the thorax and abdomen. Videos of the following procedures were utilized: left upper lobectomy, esophagectomy, sleeve gastrectomy, cholecystectomy, and ventral hernia repair. Case write-ups were created to accompany each video and included learning objectives, a brief introduction to the indications and objectives of the surgery, a summary of anatomy encountered in the procedure, and questions to reinforce key structural relationships. DESCRIPTION. A series of surgical videos and case write-ups were provided to students as a supplemental resource in a first-year foundations of medicine integrated anatomy course. The intraoperative video footage highlighted clinical relevance and three-dimensional relationships of thoracic and abdominal anatomy. SIGNIFICANCE. Video footage from robotic surgeries provides an excellent opportunity to create virtual anatomy resources that allow students to learn anatomy on living patients and emphasizes the clinical importance of what they are learning in the classroom. These videos can enhance and extend the learning from preclinical anatomy dissection experiences by presenting views of applied anatomy.

\*PENG, Michael<sup>1</sup>, Paul B. YOO<sup>2</sup>, and Anne M.R. AGUR<sup>1</sup>. <sup>1</sup>Division of Anatomy, Department of Surgery, University of Toronto, Toronto, ON M5S 1A8, Canada; <sup>2</sup>Institute of Biomaterials and Biomedical Engineering, University of Toronto, Toronto, ON M5S 3G9, Canada.

### 3D Model to Inform Electrode Placement Protocols for Percutaneous Saphenous Nerve Stimulation.

INTRODUCTION. Percutaneous saphenous nerve (SN) stimulation is an emerging treatment for overactive bladder (OAB) syndrome. The literature consists of descriptive accounts, photographs, and medical images of SN distribution. However, these resources are not adequate to construct high fidelity finite element models to simulate SN stimulation. The objective is to volumetrically document and model in 3D the course of the branches of SN relative to bony/soft tissue landmarks to enable assessment of electrode placement for percutaneous SN stimulation. METHODS. The SN and its branches along with bony and soft tissue landmarks were serially dissected, digitized (MicroScribe® G2X), and laser scanned (FARO® Quantum FaroArm®) in four embalmed lower limb specimens. The digitized and laser scanned data were registered and modelled (Autodesk® Maya®). The 3D models were used to propose optimal stimulation sites of SN relative to clinically identifiable landmarks and to construct a finite element model of SN stimulation with engineering collaborators. SUMMARY. SN has an extensive subcutaneous network comprised of the infrapatellar and medial crural cutaneous branches (MCC). The MCC consist of an anterior (AB) and posterior (PB) branch, which further ramify to supply the medial aspect of the leg. The AB gives off multiple smaller branches as it courses distally deep to the great saphenous vein to the foot. Superiorly, AB lies just posterior to the medial border of the tibia and inferiorly, on its medial surface. The PB lies on the crural fascia superficial to the medial head of gastrocnemius and terminates superior to the ankle. CONCLUSIONS. The novel 3D data is likely the first providing a cartesian coordinate-based map of the distribution of the AB and PB of the MCC of SN. This high-fidelity data will facilitate more accurate modelling of electrode placement for percutaneous SN stimulation and provide the necessary detail to translate these findings to the clinical setting.

## Abstracts - ePoster Presentations continued

\*PERRY, JonAngelo<sup>1</sup>, Mark W. GENDI<sup>2</sup>, Zubeen D. AZARI<sup>1</sup>, and Barth W. WRIGHT<sup>1</sup>. <sup>1</sup>Department of Anatomy, Kansas City University of Medicine and Biosciences, Kansas City, MO, 64106, USA; <sup>2</sup>Orthopedic Surgery Residency, St. Mary's Medical Center, Blue Springs, MO, 64104, USA.

### Anatomical Variation of the Flexor Digitorum Profundus Muscle: A Cadaveric Study.

INTRODUCTION. Routine cadaveric dissection of the forearm was performed which resulted in the identification of an isolated accessory muscle belly and tendon to the index finger. The muscle belly was identified between the flexor digitorum profundus (FDP) and flexor pollicis longus (FPL) muscles with associated tendon inserting onto the base of the distal phalanx of the index finger. The goal of this study was to identify the prevalence of the anatomic variation within a group of cadavers. METHODS. 60 formalin-embalmed cadaver (16 male, 14 female) forearms were dissected to identify the presence of an accessory muscle belly and tendon of the FDP muscle. SUMMARY. The accessory flexor muscle was identified in 20% of specimens, with 1 cadaver showing presence of the anatomic variant bilaterally. One explanation of this finding could be a signaling error in the migration and differentiation of myogenic precursors early in development as the deep flexor mass recedes into the forearm and splits into the FDP and FPL muscle. CONCLUSIONS. As the tendon of the muscle passes through the carpal tunnel, earlier onset carpal tunnel syndrome could be a consequence of inflammation. Other clinical considerations could be compression neuropathy of the anterior interosseus nerve or false presentation as a ganglion or mass if the tendon or muscle is enlarged. Awareness of this anatomical variation is important for surgeons when it comes to identifying potential root causes of these clinical symptoms in patients.

\*PICHA, Kelsey, Rebecca HLAVAC, Brittany WILLIAMS, Quincy CONLEY, and Kellie HUXEL BLIVEN. A.T. Still University, Mesa, AZ, 85206, USA.

### Strategies for Implementing Team-Based Learning into a Synchronous Online Graduate Anatomy Course.

INTRODUCTION. Team Based Learning (TBL) is a collaborative and structured pedagogical strategy that leverages small group learning to increase student accountability and engagement through preparation, assessments, and application activities. TBL requires structured and time intensive activities designed for in-person delivery, but interest to incorporate online is growing. We present strategies for effectively delivering TBL synchronously online within a graduate anatomy course. RESOURCES. An interdisciplinary collaborative approach of faculty and Teaching & Learning Center colleagues was used to identify a plan to implement synchronous online TBL sessions. DESCRIPTION. Twelve TBL sessions were held during a 20-week course that met online synchronously twice a week (2-hours each; n=125 students; n=3 faculty). Discussions after TBL sessions informed adjustments to maximize time and learning within teams. Readiness assessments and application activities were reduced from 10 to 8 items; individual readiness assessments were delivered as quizzes in Canvas, the learning management system. Qualtrics survey software (Provo, UT) was used to deliver group readiness assessments to provide a similar experience to in-person assessments which emphasize social construction of knowledge and immediate feedback. Peer evaluations were also managed in Qualtrics. We focused TBL preparation by providing patient cases used in the application activities before class along with study tips. Teams were pre-assigned application questions to answer for the group reveal portion to promote participation while managing a large online class discussion. SIGNIFICANCE. Adjustments in use of technologies and course time management while following the principles of TBL allowed for optimal delivery of synchronous online TBL. There was more time for collaborative learning and faculty were able to facilitate more effectively. These successes allow for expansion of TBL to a synchronous online format.

PORTA, Emily M., Nicole HERRING, and Jennifer BRUECKNER-COLLINS. Department of Anatomical Sciences and Neurobiology, University of Louisville School of Medicine, Louisville, KY, 40222, USA.

### Using Yammer™ to Build Community in a Virtual Anatomy Curriculum for First-Year Medical Students.

INTRODUCTION. The COVID-19 pandemic has challenged anatomy educators to find innovative, virtual venues to provide academic support for their students. In Fall 2020, anatomy faculty at the University of Louisville School of Medicine introduced a closed, course-specific social media platform (Yammer™) to enhance students' sense of connectedness with faculty and other first-year medical students in an eighteen-week, integrated anatomical sciences and physical exam course. RESOURCES. Yammer™ is described as Facebook for a professional setting; it allowed our integrated course to have its own 'feed,' through which student and faculty members could engage in open conversations about course content, rather than emailing on a one-to-one basis. DESCRIPTION. The initial intent of introducing Yammer™ in this course was to provide a unified platform for student questions from which the entire class could benefit, as compared to numerous individual email dialogues about the same topic. An additional benefit was shared faculty monitoring of and response to student queries. In addition, this interface allowed faculty to easily post polling questions to provide students with practice questions and formative feedback, which proved to be very effective 'teaching moments' in this asynchronous environment. SIGNIFICANCE. At the end of the semester, a 'Group Insights' report in Yammer™

*continued on next page*

## Abstracts - ePoster Presentations continued

revealed that over a thousand messages were posted and 59,000 messages were read with over 600 message reactions posted. This platform certainly engaged our first-year medical students in both posing questions to the faculty and answering questions (polling and open-ended) posted by faculty. We also observed a gradual increase in student-to-student engagement in Yammer&trade;, answering one another's questions and dovetailing follow up questions to other students' initial queries.

\*PRASAD, Dhanya M., Aaron M. INMAN, Paulina K. BLANC, Joshua A. GAUNT, Heather M. GUZIK, and Joanne L. PETERSON. Department of Anatomy, Arkansas College of Osteopathic Medicine, Fort Smith, AR, 72916, USA.  
[The Effect of an Anatomy Prep Course on OMS-1 Student's Performance During the Fall Semester.](#)

INTRODUCTION. Arkansas College of Osteopathic Medicine (ARCOM) offers an optional anatomical preparatory course to the incoming first-year medical students. The objective of the course was to enable students to preview the anatomy curriculum and provide for a smooth transition into their medical education. Its efficacy was assessed based on the students' academic performance in Fundamentals of Anatomical Sciences (FAS) as well as other Fall coursework. The goal of this study was to ascertain the difference in grades and the ability of the course to reduce anxiety by creating connections in the lab and with their fellow peers. METHODS. Academic performance and survey results were procured from the prep course participants and non-participants. Data was collected for three consecutive first year medical school classes and the exam results were analyzed using a T-test to determine the significant difference in grades across the semester. SUMMARY. Data has shown some suggestive academic differences between groups, however, the academic significance has declined when looking at a one-week course compared to a two-week course. Non-academic impacts, such as reduction in anxiety and transition into medical school, remain positive regardless of duration of the course. CONCLUSIONS. While academic performance varies with each group, participants in the preparatory course reported a facilitated transition into the medical school environment due to earlier exposure to cadavers as well as developing necessary study skills.

RAEBURN, Kazzara T., and Deepak SHARMA. Department of Anatomical Sciences, St. George's University, St. George's, Grenada.  
[Virtual Musculoskeletal Anatomy Lab - Learning to Teach Again.](#)

INTRODUCTION. The current COVID-19 pandemic has created many challenges in Anatomical education especially in the practical teaching of Anatomy using cadavers. At St. George's University, our customary way of teaching in the cadaver wet lab is with the use of prosections integrated with medical imaging and clinical scenarios. Prior to each lab, students receive a handout with the objectives, the clinical questions, and the medical images for preparation. During the live session, students are divided in smaller groups, and paired with a faculty member. With the advent of the pandemic, this hands-on learning environment was transitioned to virtual teaching, which has demanded faculty to develop innovative ideas to enhance the practical learning environment. RESOURCES. DESCRIPTION. We used the ZOOM platform, which can accommodate a considerable number of students and facilitate the desired interaction. It allows maximum of 300 students per session and allows us to use the built-in chat and polling features. Our new virtual lab is live with faculty discussing prosections and corresponding medical images on a camera which is linked to the host account and shared with students. The polling feature allows faculty to create multiple choice questions that are discussed during the session. The chat feature allows live interaction with students as they can pose and answer questions in real time. Image clarity had to be considered while demonstrating the specimens. We experienced a lag time in demonstrating the specimens due to slow connectivity. This was rectified by asking students to switch off their cameras, and connecting to broadband via an ethernet cable in lieu of wireless connection. Faculty learnt to speak slower and clearer. The medical images and clinical questions were incorporated into polling questions and taught alongside the prosections. SIGNIFICANCE. Our experience has shown that it is possible to create a student centric, interactive virtual cadaver lab experience.

\*RAOOF, Ameer, Avelin MALYANGO, Mange MANYAMA, Amina KUNNAMMAL, Charles MSUYA, and Nasnass NASSIR. Medical Education Division, Weill Cornell Medicine-Qatar, Qatar Foundation, P.O. Box 24144, Doha, Qatar.  
[Ensuring Effective Anatomy Teaching during the Pandemic: Our Experience.](#)

INTRODUCTION. An array of new measures has been introduced to cope with the challenges imposed by Covid-19 pandemic. Such challenges included shifting from face-to-face lectures to online sessions, and shortened dissection time. New measures included among other things online self-assessment modules and learning sessions utilizing 3D models. Students' progress was closely monitored. A survey administered to assess students' satisfaction with the new measures showed a general agreement that the measures have been useful in enhancing understanding and facilitating a better performance. METHODS. New measures introduced to the first-year medical gross anatomy course to cope with the pandemic restrictions included: weekly online self-assessment

*continued on next page*

## Abstracts - ePoster Presentations continued

questions and image identification questions; Zoom-based lectures with 3-4 polling questions; focused lab dissection sessions with two students per table instead of four using complete personal protective equipment (PPE); use of pro-sected and plastinated specimens; peer presentation/evaluation; and weekly faculty-driven online reviews of clinical anatomy questions and discussion. Students' performance in the online self-assessment modules was closely monitored on Canvas and compared with their grades in the weekly quizzes. An anonymous survey was administered to assess students' satisfaction. SUMMARY. Class overall anatomy average was 84% ( $\pm 9.7$ ), 3% higher than last year's, 82% of the students agreed that the new measures helped them understand anatomical concepts, appreciate clinical relevance 77%, and improve performance 72%. CONCLUSIONS. The higher class average may be attributed to the wider range of measures introduced and more importantly to the intense monitoring and follow up of students' performance. The Canvas-based self-assessment modules proved to be effective in stimulating students' engagement and comprehension. The new measures have been effective in ensuring better performance and satisfaction despite the curricular challenges faced during the pandemic.

RAOOF, Ameer<sup>1</sup>, Bahram KAZANI<sup>2</sup>, Muna ALMASRI<sup>2</sup>, Zuhair SADIQ<sup>2</sup>, Rawan HUSSEIN<sup>2</sup>, Shehroz RANA<sup>2</sup>, Daniel KIM<sup>2</sup>, Mohammad I. BHATTI<sup>2</sup>, Dabin CHUNG<sup>2</sup>, Omar KHALIL<sup>2</sup>, Hasan ALROOBI<sup>2</sup>, Ahmed ALY<sup>2</sup>. <sup>1</sup>Department of Anatomy in Radiology, Weill Cornell Medicine-Qatar, Education City, Qatar Foundation, Doha, Qatar; <sup>2</sup>2023 Medical Students, Weill Cornell Medicine-Qatar, Education City, Qatar Foundation, Doha, Qatar.

### Utility of the Anatomage Table in Creating Clinical Anatomy and Radiology Learning Modules.

INTRODUCTION. Amid the COVID-19 pandemic, teaching methodology has required heavy use of online-learning modalities for medical schools. This has been especially difficult for anatomy courses, since the nature of the subject requires hands-on experience in laboratories with cadavers to help students visualize structures of the human body. This study was conducted to provide easily accessible online anatomy modules by utilizing the Anatomage Table for first year medical students to facilitate their learning and enhance their online learning experiences. The online modules aimed at exploring the synergistic learning effects of Anatomage with other learning tools such as clinical problem-based learning. Participated students largely agreed that the modules were easy to navigate and reported that the modules were helpful in understanding the concepts. METHODS. Ten online modules, designed by medical students, who have just finished the anatomy course as part of their summer research program, and consisted of practice exercises, self-assessments, as well as anatomical images and radiographs, which were taken from Anatomage and few other sources. Each module was focused on one organ system and one pathology, of which was centered around a clinical case. Structures on the radiographic images were labelled, assisting students in recognizing major organs and comprehending the angles at which sections are taken. Premedical, first-year, and second-year medical students participated in utilizing and testing the effectiveness of the modules. Each module was followed by a short quiz, composed of three-to-thirteen questions, designed by their respective module authors. Students then took the feedback surveys at the end of each module to provide their opinions on their learning experience. SUMMARY. A total number of 110 students volunteered to take the modules. A majority of the students agreed (41%) or strongly agreed (50%) that the modules were easy to navigate and 90% of the students reported that the modules were helpful in understanding the concepts. CONCLUSIONS. Overall, our findings were supportive of the implementation of technology and virtual software in teaching anatomy. The new online-based learning medium can provide for a more enriching and engaged learning experience for medical students.

\*RODGERS, Austin D., Keith N. BISHOP, Anthony A. HEWETSON, and Gregory L. BROWER. Texas Tech University Health Sciences Center, Lubbock, TX 79430, USA.

### A Unique Arrangement of Bilaterally Duplicated Renal Arteries and Aberrant-Origin Gonadal Arteries.

INTRODUCTION. Nearly 500,000 kidney transplant surgeries have been conducted in the United States during the past 30 years. To reduce the risk of organ damage, surgeons must be aware of potential vascular anomalies encountered during harvesting and implantation. Accessory renal arteries are present in 20-30% of the population, being bilateral in ~10%. However, the literature often fails to note the occurrence of these anatomical variants, increasing the risk that less experienced surgeons could damage them during procedures. This case study documents an aberrant arrangement of renal and gonadal vessels which, to our knowledge, has not previously been documented in the literature. METHODS. Multiple abdominal vascular anomalies were identified during routine cadaveric dissection as part of a medical anatomy course. The subject of this report was an adult male whose cause of death was Huntington's disease. SUMMARY. An accessory left renal artery supplying the inferior pole was present at the L2 vertebral level, in addition to the standard left renal artery. The left testicular artery originated from this accessory renal artery, and bifurcation of the left testicular vein was noted. An accessory right renal artery originating at the L3 vertebral level was present, in addition to an early trifurcation of the right renal artery in its expected hilar location. A unique anomaly of the vascular architecture was the right testicular artery originating from the inferior right middle suprarenal artery, and duplication of the right renal vein. CONCLUSIONS.

*continued on next page*

## Abstracts - ePoster Presentations continued

Recognition of this unique combination of anomalous vessels would be important for any surgeon operating in the abdomen. Not only is the presentation of the renal arteries and veins in this case necessary information for transplant surgeons, but it is also important to be aware of the potential loss of blood flow to the right testis which would occur following ligation of the suprarenal arteries as part of an adrenalectomy.

RUTLAND Marsha D., Austin P. ALEXANDER, Ally ARNOLD, Sydney HERBEL, Parker JOHNSON, and Keaton YOWELL. Department of Physical Therapy, Hardin-Simmons University, Abilene, TX, 79698, USA.

### Abnormal Clavicle and Accessory Subclavius Posticus Muscle.

INTRODUCTION. This case evaluates a cadaver with a protruding left clavicle and an accessory muscle, dissected by Doctor of Physical Therapy Students. RESOURCES. An 89-year-old male cadaver with anatomical variation. Cause of death was Parkinson's Disease. DESCRIPTION. An atypical protrusion of the medial head of the clavicle, extending anteriorly 3 cm from sternal clavicular end, and bony growth attaching to the manubrium was discovered. Students' review of literature found multiple clavicular abnormalities including congenital clavicular pseudoarthrosis, and Cleidocranial dysplasia syndrome, although none matched this deviation. Rare sternoclavicular dislocations could result in atypical presentations of the clavicle. Students speculated this anatomic variation could result in sternoclavicular joint hypomobility impairing typical scapulohumeral rhythm. When removing the pectoralis minor on the contralateral side, an accessory muscle, also known as Subclavius Posticus, was found attaching to the inferior clavicle and costal cartilage of the first rib to the superior border of the scapula. This muscle, Subclavius Posticus, exhibits an incidence of 8.9% in 124 cadaver dissections. A kyphotic posture was also speculated with the accessory Subclavius Posticus muscle. In addition, a suprascapular nerve compression may have occurred limiting movements of abduction and external rotation. Students found high-resolution MRI may help evaluate compression of the suprascapular nerve secondary to an accessory Subclavius Posticus muscle. Subclavius Posticus could result in limitations in scapular posterior tilting and upward rotation. Anatomic variation found in the clavicle and subclavius posticus would likely result in impaired scapulohumeral rhythm resulting in impaired humeral elevation above 90 degrees. SIGNIFICANCE. The anatomic variations of an irregular left clavicle and a right accessory Subclavius Posticus muscle encouraged students to critically analyze these irregularities and hypothesize clinical presentations.

\*RUTLAND, Marsha D., Hannah STUEART, Lucas PRUITT, Kaylie ANGELLO, and Caitlin MANNON. Department of Physical Therapy, Hardin-Simmons University, Abilene, TX, 79698, USA.

### Speculation of Neurological Conditions in a Cadaver with Multilevel Stenosis.

INTRODUCTION. Stenosis is frequently seen in those over 60 years of age. With significant stenosis, one may experience multiple neurological symptoms. This case report evaluates a cadaver with multilevel stenotic areas of the spinal cord. RESOURCES. An embalmed 89-year-old female cadaver (of one year) dissected over 8 months. The cause of death was Alzheimer's, dementia, chronic systolic and diastolic congestive heart failure, hypertension, diabetes, and atrial fibrillation. DESCRIPTION. With dissection of the spinal cord, there were multilevel stenotic areas in the cervical, thoracic and lumbar regions. Upon dissecting within the spinal cord, multiple intrathecal calcium deposits were noted in the thoracic and lumbar region. A lumbar laminectomy with spinal fusion was noted at T12-L2. Students speculated that this cadaver would have possible renal failure. They also speculated due to the laminectomy, intrathecal calcifications would form as they often are found post-surgical. In addition, students were able to combine neurological assessment with diagnosis, speculating that this cadaver may have had symptoms associated with spinal stenosis including, but not limited to gait deviations, tingling, numbness, burning, cramping, muscle weakness, loss of sensation, possible loss of sexual ability, and/or loss of bowel or bladder control. Students observed an android body type, stage 3 decubitus in the sacral region, and fat infiltration throughout the multifidus bilaterally which may be found following lumbar surgery. Intrathecal calcifications could have caused intermittent pain and neurological signs but may not have been found unless a CT scan had been performed. SIGNIFICANCE. By speculation, students can learn neurological signs and symptoms which can be associated with stenosis and their future patients and begin applying knowledge to practical scenarios. This allows students to critically think and develop an understanding of the pathophysiology of diseases.

## Abstracts - ePoster Presentations continued

RUTLAND, Marsha, Austin P. ALEXANDER, Mark ARMSTRONG, Natalie MOTT, Kassidy LOTRICH and Morgan MCINTOSH. Department of Physical Therapy, Hardin-Simmons University, Abilene, TX, 79698, USA.  
Spinal Arachnoid Calcifications versus Arachnoiditis Ossificans-A Discovery of Two Disease Processes.

INTRODUCTION. Doctor of physical therapy students found intrathecal calcifications in the spinal cord of a cadaver. RESOURCES. An embalmed 72-year-old male cadaver dissected over 8 months. Cause of death included metastatic lung cancer, chronic obstructive pulmonary disease, and coronary artery disease. DESCRIPTION. Upon dissecting the spinal cord, multiple thoracic and lumbar intrathecal calcifications were found, measuring 3-8 mm in diameter and 1mm in thickness. There is no evidence of lumbar surgeries or laminectomy. No displacement of the spinal cord or nerve roots was noted. Differential diagnosis included asymptomatic calcification plaques of the dura mater or intrathecal ossification associated with chronic arachnoiditis. Calcified asymptomatic calcification plaques can develop with no neurological symptoms and may be an incidental finding. These calcifications could be precursors to spinal arachnoid ossificans. Arachnoiditis ossificans is a rare chronic condition, typically confined to the thoracic and lumbar regions, which may follow spinal trauma, major spinal surgery, or myelography. Other contributing factors for arachnoiditis ossificans can include renal failure, adverse side effects from cancer treatment/medications, and/or more specifically neoplastic arachnoiditis ossificans. Patients with arachnoiditis ossificans often present with debilitating neurologic deficits. Patients could complain of chronic low back pain, leg pain, paresthesia, and weakness. Sensory and motor impairments would likely follow myotome and dermatome patterns. Furthermore, concerns may exist with urinary incontinence. Diagnostic imaging may reveal calcifications on radiographs, MRI- 1 and MRI -2, and CT scans. Neural mobilization may assist in relief of symptoms. SIGNIFICANCE. Discovering intrathecal calcifications allowed students to research two disease processes, evaluate diagnostic imaging and hypothesize initial insult of injury and clinical presentation.

\*SALAZAR, Dylan M., Ricardo BELMARES, and Homaira AZIM. Texas Tech University Health Science Center El Paso Paul L. Foster School of Medicine, El Paso, TX, 79905, USA.  
Assessing the Efficacy of the Novel, Hybrid-Based Surgical Anatomy Elective Course.

INTRODUCTION. The Surgical Anatomy Elective Course (SAEC) at Paul L. Foster School of Medicine (PLFSOM) is an intensive 2-week review of anatomy, common surgeries, and basic surgical techniques aimed at preparing 4<sup>th</sup> year medical students to enter surgical specialties. Due to the COVID-19 pandemic, the participants improved these skills via a novel, hybrid-based platform by using online modules, assigned readings, and hands-on cadaveric dissections. This study investigates the impact that these uniquely adjusted learning methods have on participant performance and confidence levels. METHODS. The research was executed using an Embedded-Quantitative Dominant research design – a type of mixed-methods research design. Participants completed a survey both prior to and after completing the SAEC. Survey data encompassed both quantitative and qualitative data. Survey data included self-reported anatomical and surgical procedure confidence levels, as well as perceptions on various aspects of the course. SUMMARY. There was dramatic improvement in self-confidence ratings with regard to anatomical knowledge, but only slight improvement was seen with self-confidence ratings on surgical procedure knowledge upon completion of the course. Participants conveyed that the most beneficial methods of learning entailed the dissection videos from the University of Central Florida, the hands-on cadaveric dissections, and the New England Journal of Medicine learning tools provided. On the contrary, assigned readings from Moore's Clinically Oriented Anatomy Textbook, 8<sup>th</sup> edition was found to be least helpful for the participants' learning experience. CONCLUSIONS. The hybrid format of the SAEC found that participants gained confidence and knowledge to enter surgical specialties. This hybrid format enabled participants to be exposed to alternative learning methods, some of which may be implemented in future SAECs in order to better prepare 4<sup>th</sup> year medical students for surgical specialties.

\*SANGARI, Santosh K., Sushil KUMAR, Ritwik BAIDYA, Estomih P. MTUI. Division of Anatomy, Department of Radiology, Weill Cornell Medicine, NY, 10065, USA.  
Anomalous Uterine Arteries: A Case Report and Review of the Literature.

INTRODUCTION. Transcatheter embolization and other endovascular techniques are safe effective therapeutic options for management of intractable obstetrical and gynecological bleeding. Detailed knowledge of the uterine vascularization is essential for the management of uterine bleeding. In 51% of cases, the uterine artery arises from the anterior division of internal iliac artery. RESOURCE. The observations were made in a 75-year-old female donor during regular educational dissection session in the gross anatomy lab. DESCRIPTION. The dissection of the hemisected pelvis showed two uterine arteries arising from anterior division of internal iliac artery on both sides. The normal uterine artery was not tortuous and reached the cervix of uterus and ascended to supply the uterus. The aberrant uterine artery was tortuous and directly reached the fundus of uterus to supply it, fallopian tube and the ovaries. The ovarian artery was seen arising normally from the abdominal aorta on both sides and entered the suspensory ligament to supply the ovary. SIGNIFICANCE. Interventional radiologists performing the normal uterine artery embolization should

*continued on next page*

## Abstracts - ePoster Presentations continued

be aware of an additional aberrant uterine artery, which might be encountered during surgical procedure as potential source of collateral blood supply to the uterus. The non-embolization of unknown aberrant arteries supplying the uterus may be responsible for treatment failure.

SHAFFER Kitt<sup>1</sup>, Jonathan J. WISCO<sup>2</sup>, and Ann C. ZUMWALT<sup>2</sup>. <sup>1</sup>Department of Radiology, Boston University School of Medicine, Boston, MA, 02118, USA; <sup>2</sup>Department of Anatomy and Neurobiology, Boston University School of Medicine, Boston, MA, 02118, USA. [Self-Directed Group Workshops on Radiologic Anatomy for Medical Students.](#)

**INTRODUCTION.** Group workshops, with image-based tasks for student evaluation, were developed for 1st-year medical students at Boston University School of Medicine. Modules were designed for 3 anatomic areas (Back/Limbs, Thorax, Abdomen/Pelvis). An Introductory module was developed to introduce students to the website. **RESOURCES.** Each module was designed with three sections: 1-Preview Cases, which offered an introduction to the topic area (to be reviewed by students individually), 2-Workshop Cases, with images for discussion (to be reviewed in student groups via Zoom), 3-Tasks, consisting of a set of assignments (to be completed using drawing tools incorporated in the website, with annotated images uploaded to Blackboard for grading). Task images were graded by a team of anatomy faculty and teaching assistants. **DESCRIPTION.** Students were able to access the website for Preview and Workshop Cases without difficulty, and all student groups submitted a complete set of annotated Task images for each of the topic areas. Faculty and assistants were able to manually grade all submissions (19 group submissions for each topic area) in approximately two hours. Informal feedback from students at mid-course suggested that students were more comfortable interpreting cross-sectional imaging on their own than in past years, when teaching was in the form of a single interactive flipped classroom lecture for each topic. **SIGNIFICANCE.** Students may gain more confidence in recognizing anatomy on cross-sectional imaging, through group and task-based activities than from interactive flipped classroom lectures. Completion of group tasks may also be more instructive than multiple choice questions, requiring higher level comprehension. While manual grading was required for image files, the grading for each topic area was accomplished by teams in approximately two hours. Student comments suggest that an introductory lecture might clarify goals and provide better integration.

\*SILLA, Karol J.<sup>1</sup>, Ameer RAOOF<sup>2</sup>, Avelin MALYANGO<sup>2</sup>, Mange MANYAMA<sup>2</sup>, Nasnass NASSIR<sup>2</sup>, and Charles MSUYA<sup>2</sup>. <sup>1</sup>Department of Otolaryngology-Head and Neck Surgery, Hamad General Hospital, Doha, 00000, Qatar; <sup>2</sup>Medical Education Division, Weill Cornell Medicine-Qatar, Doha, 00000, Qatar.

[The Presence of Tubarial Salivary Glands: A Literature Review and Exploratory Cadaveric Dissection.](#)

**INTRODUCTION.** Several anatomical texts have described the presence of seromucous glands in the nasopharynx close to the torus tubarius. Recently, an incidental finding of these 'tubarial salivary glands' (TSG) in patients with prostate or para-urethral gland cancer visualized in prostate-specific membrane antigen Positron Emission Tomography was reported. The aim of this study is to perform a literature review and to demonstrate the TSG in 3 cadaveric heads in the anatomy lab. **RESOURCES.** A recently published study about TSG as a potential organ at risk during radiotherapy was critically appraised, and a literature search was conducted in Pubmed, Embase, and Google Scholar. In the anatomy lab, the nasopharynx was dissected in 3 sagittally sectioned heads of female donors; their ages ranged from 60 to 92 years old. **DESCRIPTION.** The published study highlighted that TSG with acini and draining ducts were confirmed in male cadavers. Our cross-reference search of articles—including textbook pages, review articles, and letters to the editor—related to TSG broadened the computerized literature review; results showed a knowledge gap still needs to be addressed before acknowledging these tubarial structures as 'salivary glands.' During our cadaveric study, the mucous membrane lining of the nasopharynx was reflected. Grossly, there were submucosal structures that were in the form of small discrete masses. We plan to investigate those structures with microscopy and immunohistochemistry once the pandemic restrictions are eased. **SIGNIFICANCE.** The discussion about TSG is of great interest to clinicians and anatomists, especially with its clinical relevance for patients undergoing radiotherapy with the risk of xerostomia. In the future, looking into fresh cadaveric specimens, dissecting and identifying the anatomical variation among pediatric and pre-pubertal cadaver heads, and performing extended histopathologic studies may deepen our understanding of these organs.

## Abstracts - ePoster Presentations continued

\*TABIRA, Yoko<sup>1</sup>, Akihiro YAMASHITA<sup>1</sup>, Keishirou KIKUCHI<sup>1</sup>, Aya HAN<sup>1</sup>, Joe IWANAGA<sup>1,2</sup>, Kunimitsu NOOMA<sup>1</sup>, Eiko INOUE<sup>1</sup>, Tsuyoshi SAGA<sup>3</sup>, and Koichi WATANABE<sup>1</sup>. <sup>1</sup>Department of Anatomy, Kurume University School of Medicine, Fukuoka, 830-0011, Japan; <sup>2</sup> Department of Neurosurgery, Tulane University School of Medicine, New Orleans, LA, 70112, USA; <sup>3</sup> Domain of Anatomy, Kurume University School of Nursing, Fukuoka, 830-0003, Japan.

### Anatomical Study of the Popliteus Tendon Focusing on the Knee Joint Capsule and the Bursa.

INTRODUCTION. The popliteus muscle originates on the lateral epicondyle of the femur. Its tendon penetrates the knee joint capsule, runs medially downward, and attaches to the posterior surface of the tibia. A bursa called the subpopliteal recess is present in the knee joint capsule between the popliteus muscle and the posterior lateral margin of the lateral tibial condyle, and the popliteus tendon runs within this bursa. The purpose of this study was to clarify the morphology around the popliteus tendon by focusing on the knee joint capsule and the bursa. METHODS. The knee and popliteus muscles were observed in 10 knees from formalin-preserved cadavers. The joint capsule was colored and dissected to examine its communication with the bursa and the positional relationship between the popliteus tendon and the capsule. SUMMARY. In all cases, the subpopliteal recess depression was located between the popliteus tendon and the lateral meniscus, with the synovial membrane of the knee joint capsule acting as the bursa. This depression extended distally along the popliteus tendon or dorsally to the popliteus tendon. We also confirmed other bursae that were associated with the popliteus tendon but that did not communicate with the articular cavity. CONCLUSIONS. The popliteus muscle is considered to be one of the primary structures that maintain the posterior lateral stability of the knee joint. Along with its static function, the dynamic function of the popliteus tendon is also important, guiding the lateral meniscus backward during knee flexion. We believe that it is important to present detailed anatomical findings to provide effective treatment for patients with pain in the posterior knee joint.

\*TAYLOR, Alex M., Shayan A. MEMAR, Shivika AHUJA, Daniel T. DALY, and Yun TAN. Center for Anatomical Science and Education, Department of Surgery, School of Medicine, Saint Louis University, St. Louis, MO, 63104, USA.

### Rare Left Colic Artery Variation of the Gut Arterial System: A Case Report.

INTRODUCTION. Variations of the left colic artery (LCA) are considered very rare, as most variations of the abdominal blood supply tend to be related to the celiac trunk, superior mesenteric artery, and their branches. Therefore, an understanding of possible and common LCA variations is of particular clinical importance, especially for surgical and radiological procedures. RESOURCES. An anomalous origin of the LCA was observed during routine cadaveric dissection of an 84-year-old male donor to the Saint Louis University Gift Body Program. DESCRIPTION. In this cadaver, the LCA originated from the common hepatic artery (CHA), approximately 1 cm lateral from the CHA's origin from the celiac trunk. The LCA traveled inferiorly and quickly emitted two branches along its course. The first branch traveled rightward along the posterosuperior border of the splenic vein, then deep to the hepatic portal vein to supply the head of the pancreas and adjacent duodenum before anastomosing with the posterior superior and inferior pancreaticoduodenal arteries. The second branch coursed leftward, along the posteroinferior border of the pancreas between the splenic vein and body of the pancreas, and formed two anastomotic loops with proximal branches of the splenic artery. Distal to these two branches, the LCA continued inferiorly, between the splenic vein and superior mesenteric artery, to supply the colon near the splenic flexure, forming a collateral route with the middle colic artery and contributing to the marginal artery of Drummond. Only sigmoidal and superior rectal arteries were found originating from the inferior mesenteric artery. SIGNIFICANCE. This anatomical variation appears to be the first of its kind presented in the literature. Knowledge of this variation is clinically relevant for surgical and radiological procedures of the abdominal viscera.

\*THOMANN, Charity L.<sup>1</sup>, Sherif S. HASSAN<sup>2,3</sup>, Allen CORNELIUS<sup>1</sup>, and Debra BENDELL-ESTROFF<sup>1</sup>. <sup>1</sup>School of Psychology, Fielding Graduate University, Santa Barbara, CA, 93105, USA; <sup>2</sup>Department of Anatomy, Faculty of Medicine, Cairo University, Cairo, Egypt; <sup>3</sup>Department of Medical Education, California University of Science and Medicine, Colton, CA, 92324, USA.

### Test Anxiety Related to Course MCQ Exam but Not a Lab Practical Exam: An Art in Anatomy Pilot Study.

INTRODUCTION. Test anxiety during high stakes tests leads to poor outcomes. This pilot study aimed to explore how test anxiety may differently affect creative medical students' performance (lab practical) and objective (MCQ) test outcomes in a clinical anatomy course. METHODS. Medical students from a school in Southern California were invited to participate in a study investigating the relationship between creativity, test anxiety, and achievement of anatomy learning outcomes. Pearson correlations were calculated to determine the relationship between variables. Independent t-tests were used to determine whether differences existed for (1) gender, (2) race, (3) first generation to attend college, and (4) first generation to attend graduate or medical school. SUMMARY. A significant correlation exists between medical students' test anxiety and their MCQ outcomes  $r(34) = -.48, p = .003$ . No relationship was found between the lab practical exam and test anxiety  $r(35) = -.04, p = .790$ . No relationship was found between the lab practical exam and MCQ exams  $r(35) = .21, p = .218$ . No differences in learning outcomes were found for demographic factors. However, greater test

*continued on next page*

## Abstracts - ePoster Presentations continued

anxiety was endorsed by female students,  $t(35)=-3.51$ ,  $p=.001$ , and students who were the first generation to attend college  $t(35) = -2.48$ ,  $p=.018$ . Results may only be generalizable to creative medical students, 97% of participants endorsed participating or viewing the arts. CONCLUSIONS. Our results indicate that further exploration is feasible and needed to understand the different relationships between test anxiety and performance and objective test results. A better understanding of this phenomenon may help anatomy educators create interventions or testing practices that prevent negative outcomes of test anxiety.

\*THOMANN, Charity L.<sup>1</sup>, Sherif S. HASSAN<sup>2,3</sup>, Allen CORNELIUS<sup>1</sup>, and Debra BENDELL-ESTROFF<sup>1</sup>. <sup>1</sup>School of Psychology, Fielding Graduate University, Santa Barbara, CA, 93105, USA; <sup>2</sup>Department of Anatomy, Faculty of Medicine, Cairo University, Cairo, Egypt; <sup>3</sup>Department of Medical Education, California University of Science and Medicine, Colton, CA, 92324, USA.  
Creativity Interferes with Measuring Anatomy Learning Outcomes: An Art in Anatomy Pilot Study.

INTRODUCTION. The theory of multiple intelligences suggests that students have varying strengths that support the achievement and demonstration of learning outcomes. This pilot study aimed to explore how creativity may influence the achievement of medical students' clinical anatomy learning outcomes. METHODS. Medical students from a school in Southern California were invited to participate in the study. Pearson correlations were calculated to determine the relationship between preference for ideation of ideas, premature critical evaluation of ideas, a lab practical exam, and clinical anatomy MCQ. Independent t-tests were used to determine whether differences existed for demographic factors and the belief in having a creative talent and participation in art related student interest groups. SUMMARY. Students who believed they had a creative talent earned lower scores on the lab practical than students who did not believe they had a creative talent  $t(34)=2.19$ ,  $p=.036$ . No difference was found between the belief of a creative talent and MCQ outcomes. No differences in the achievement of learning outcomes were found for medical students who participated in art related student interest groups. A small but not significant relationship was found between the preference for ideation of ideas and the MCQ exam  $r(34)= -.21$ ,  $p=.232$  and between the lab practical exam and premature critical evaluation of ideas  $r(35)= -.20$ ,  $p=.243$ . No differences were found for demographic factors. Results may be generalizable only to students who value creativity, 97% of students participated or viewed the arts. CONCLUSIONS. Further exploration is needed to understand the different relationships between creative beliefs, participation, and achievement of anatomy learning outcomes. Creative medical students might benefit from interventions that support their learning strengths or varied assessments that better demonstrate their achievement of learning outcomes.

\*THOMAS, Rebecca J.<sup>1</sup>, Taylor YANCEY<sup>1</sup>, Chad SKIDMORE<sup>1</sup>, Neal FERRIN<sup>2</sup>, Isain ZAPATA<sup>3</sup>, Jennifer WILLIAMS<sup>3</sup>, and Nena MASON<sup>1</sup>. <sup>1</sup>Division of Anatomy, College of Medicine, Rocky Vista University - Southern Utah, Ivins, UT, 84738, USA; <sup>2</sup>Department of General Surgery Residency, Western Michigan University, Kalamazoo, MI, 49008, USA. <sup>3</sup>Rocky Vista University College of Osteopathic Medicine – Colorado, Parker, CO, 80134, USA.  
Effects of Pre-medical Anatomy/Clinical Experiences on Medical School Anatomy-Related Performance.

INTRODUCTION. The objective of this study was to examine the effects that pre-medical patient-care clinical experiences and anatomical education had on undergraduate medical course grades and anatomy practical exam scores. This study provides a unique perspective to this line of inquiry in that it included data from 9 class year cohorts between academic years 2010-2011 and 2018-2019, all from a single institution. METHODS. A survey to assess pre-medical clinical and anatomical experiences was completed by each new matriculate. Results were compared to each student's course grades and anatomy practical exam scores. The effects of pre-medical experiences on practical scores and final grades were evaluated using Generalized Linear Mixed Models. SUMMARY. Several positive and negative associations were identified. The most obvious effect revealed by data analysis was the class year cohort effect, seen as variation in the academic performance of each cohort from year-to-year. Other significant results included a positive association between pre-medical comparative anatomy coursework and anatomy assessment performance over the entire year's anatomy curriculum. Counterintuitively, some pre-medical clinical experiences, such as nursing experience, had a negative effect on course grades and practical exam performance. CONCLUSIONS. Pre-medical students can use this information to decide whether to enroll in undergraduate anatomy courses or engage in extra pre-medical clinical work. It may also be valuable to medical school admissions departments in regards to determining the anatomy coursework and clinical experience requirements for their applicants.

## Abstracts - ePoster Presentations continued

\*TSUTSUMI, Masahiro<sup>1</sup>, Keiko FUKINO<sup>2</sup>, Sasin SRITARA<sup>2</sup>, Keiichi AKITA<sup>1</sup>. <sup>1</sup>Department of Clinical Anatomy, Tokyo Medical and Dental University, Tokyo, 1138519, Japan; <sup>2</sup>Department of Orthodontic Science, Tokyo Medical and Dental University, Tokyo, 1138519, Japan. Significance of the Medial Surface of the Condylar Process as an Insertion of the Lateral Pterygoid.

INTRODUCTION. Lateral pterygoid (LP) plays an essential role in jaw-opening, protrusion, lateral movement. In general, these three-dimensional (3D) jaw movements of the lateral pterygoid are closely related to its origin and insertion. Recently, we reported that the LP insertion is not limited to the pterygoid fovea but also located on the medial surface of the condylar process (mCP). Morphological features of this insertion may provide better insight into the contribution of the LP to the various jaw movements. This study aimed to investigate the morphological features of the LP insertion on the mCP. METHODS. We analyzed ten jaws from seven Japanese cadavers. In all specimens, the 3D morphology of the condylar process was examined by the micro-computed tomography (inspeXio smx-100ct, SHIMADZU, Japan), and the insertion area on the mCP was measured based on its 3D surface models by the Geomagic Wrap software (3D Systems, Rock Hill, SC). SUMMARY. Insertion area on the mCP occupied 28.8±5.0% of the entire insertion areas. In addition, muscle bundles inserting into the mCP in seven specimens originated from the posterior half of the lateral plate of the pterygoid process, whereas those in three specimens from the posteroinferior portion of the lateral plate of the pterygoid process. Therefore, the LP had a broad insertion area on the mCP and the muscle bundle inserting on the mCP had a specific origin that was distinguishable from the remaining origin. CONCLUSIONS. Although it was conventionally assumed that the LP was composed of the two functional subunits, upper and lower heads of the LP, the muscle bundle of the LP inserting on the mCP can also act as one of the functional subunits. Considering the orientation of the mCP, which is different from those of the pterygoid fovea, the muscle bundle of the LP inserting on the mCP may play a major role in the lateral jaw movement.

\*WATANABE, Koichi<sup>1</sup>, Aya HAN<sup>1</sup>, Yoko TABIRA<sup>1</sup>, Akihiro YAMASHITA<sup>1</sup>, Keishirou KIKUCHI<sup>1</sup>, Eiko INOUE<sup>1</sup>, Kunimitsu NOOMA<sup>1</sup>, Joe IWANAGA<sup>1,2</sup>, and Tsuyoshi SAGA<sup>3</sup>. <sup>1</sup>Division of Gross and Clinical Anatomy, Department of Anatomy, Kurume University School of Medicine, Kurume, Fukuoka, 830-0011, Japan; <sup>2</sup>Department of Neurosurgery, Tulane University, New Orleans, LA, 70118, USA; <sup>3</sup>Domain of Anatomy, Kurume University School of Nursing, Kurume, Fukuoka, 830-0003, Japan. The Subcutaneous Structure That Forms the Three-Dimensional Shape of the Hip.

INTRODUCTION. The hip has a three-dimensional shape with a large variety of surface features. These specific shapes are believed to form by the developing gluteal muscles, enabling bipedalism. Furthermore, some researchers have claimed that subcutaneous structures connect the deep and superficial tissues. The purpose of this study was to clarify the subcutaneous structures that form the shape of the hip and to apply the results to surgical procedures. METHODS. Six buttock tissues were obtained from cadavers that were donated to our medical school for the purpose of anatomical education and research. In three cases, the tissues were cut to a 1-cm width in the horizontal section. In other three cases, the tissues were cut parallel to the longitudinal axis of the trunk; sagittal section in the median and frontal sections in the most lateral part. These sections were then stretched by fixing the deep tissue on the board and pulling the skin outward. The dissection was performed under magnified view to reveal the fibrous structures in the subcutaneous tissue. SUMMARY. The dermis and deep fascia were adhered to the median crest of the sacrum, coccyx, and iliac crest. Dense fibers arose from the periosteum of the ischial tuberosity and inserted into the dermis cranial to the gluteal fold. The subcutaneous tissue over the iliotibial tract was thin, and a fibrous connection existed between the ligament and dermis. The subcutaneous fat was thick toward the lateral and caudal regions with an increasing amount of superficial fascia by ramification. CONCLUSIONS. In contrast to other parts of the body, the buttock has characteristic superficial fasciae in the subcutaneous fat. The adhesions and dense fibers support the skin against the effects of gravity. The findings of this study may be useful for creating a gluteal flap for breast reconstructive surgery as well as for buttock plasty.

\*WEIL, Jennifer A.<sup>1</sup>, Alexander IN<sup>2</sup>, and Hana ANDERSON<sup>1</sup>. <sup>1</sup>Department of Cell Biology and Human Anatomy, School of Medicine, University of California, Davis, Davis, CA, 95616, USA; <sup>2</sup>Graduate Medical Sciences, School of Medicine, Boston University, Boston, MA, 02118, USA. Translation of 2D Anatomical Education to 3D Human Cadaver Prosections: A Pilot Study.

INTRODUCTION. A spatial and visual science, gross anatomy relies on hands-on educational approaches (e.g., cadaver dissection and prosections). In 2020, COVID-19 forced gross anatomy courses to shift from hands-on instruction to remote education. This study compared anatomical identification ability (hands-on prosections vs. images) of Spring 2020 (S20) students who learned gross anatomy from images to Winter 2020 (W20) students who learned gross anatomy in-person from prosections, and the effect of hands-on prosection-based trainings. METHODS. Using a quasi-experimental design, eight participants were assigned to one of three groups: W20 Trained (W20-T) or Untrained (W20-UT), or S20. W20-UT served as a nonequivalent control group. All subjects took two 30-question multiple choice pre-tests, one hands-on and one image-based. W20-T (n=2) and S20 (n=3) then participated

## Abstracts - ePoster Presentations continued

in six 4-hour hands-on prosection training sessions divided by region. W20-UT (n=3) underwent no training and had no access to prosections. After all trainings were complete, participants took hands-on and image-based post-tests. All data are reported as mean  $\pm$  SD (score/30). SUMMARY. No significant differences were found between S20 and W20-T+UT on either the image ( $20.7 \pm 1.5$  vs.  $17.8 \pm 3$ ;  $p = 0.07$ ) or hands-on pre-tests ( $12.3 \pm 5.1$  vs.  $16.2 \pm 6.1$ ,  $p=0.19$ ). For the hands-on tests, training did not produce significant increases in W20-T scores (pre:  $18.5 \pm 4.9$  vs. post:  $24.5 \pm 2.1$ ;  $p = 0.13$ ), while S20 showed significantly increased scores following training (pre:  $12.3 \pm 5$  vs. post:  $21.67 \pm 2.5$ ;  $p=0.02$ ). Although W20-T had a higher average score on the post-test than S20, the difference was not significant ( $p=0.13$ ). CONCLUSIONS. Students who learn gross anatomy remotely are able to translate their knowledge to prosections, and an intensive hands-on cadaver-based training program may help them catch up to those with hands-on anatomy education. Study replication with a larger n is needed.

\*YAMASHITA, Akihiro<sup>1,2</sup>, Kousuke TABUCHI<sup>2</sup>, Shotaro KINOUCHI<sup>2</sup>, Keishirou KIKUCHI<sup>2</sup>, Takashi SOEJIMA<sup>2</sup>, Akira MAEDA<sup>2</sup>, Yoko TABIRA<sup>1</sup>, Joe IWANAGA<sup>1</sup>, Aya HAN<sup>1</sup>, Shuji HORIBE<sup>3</sup>, Naoto SHIBA<sup>2</sup>, Takahiro OKAWA<sup>2</sup>, and Koichi WATANABE<sup>1</sup>. <sup>1</sup>Department of Anatomy, Kurume University School of Medicine, Kurume, Fukuoka, 830-0011, Japan; <sup>2</sup>Department of Orthopedic Surgery and Sports Medicine, Kurume University, Kurume, Fukuoka, 830-0011, Japan; <sup>3</sup>Osaka Prefecture University, Graduate School of Comprehensive Rehabilitation, Sakai, Osaka, 599-8531, Japan.

### Histological Evaluation of the Tibial Attachment of the Posterior Cruciate Ligament.

INTRODUCTION. Many studies have focused on the anterior cruciate ligament (ACL) attachments, including some recent histological studies. To the best of our knowledge, however, few reports have histologically described the tibial attachment of the posterior cruciate ligament (PCL). To clarify the PCL tibial attachments, we conducted a histological study of the PCL attachments in the posterior intercondylar area (PIA) of the tibia. METHODS. Eleven embalmed cadaveric knees (7 male, 4 female; mean age,  $75.9 \pm 9.1$  years) were used in this study. The PCL tibial attachment was divided into four sections in the sagittal plane perpendicular to the champagne-glass drop-off at the posterior margin of the tibia. Hematoxylin–eosin staining and Masson's trichrome staining were performed on the tissue sections, and the extent and location of the PCL attachment were measured on the lateral, central, and medial sections. SUMMARY. The mean distance between the anterior and posterior margins of the PCL in the sagittal plane was  $8.7 \pm 1.4$ ,  $9.7 \pm 1.1$ , and  $7.3 \pm 1.0$  mm on the lateral, central, and medial sections, respectively. The mean distance from the PCL anterior margin to the tibial posterior margin was  $10.1 \pm 1.6$ ,  $10.8 \pm 1.2$ , and  $8.4 \pm 0.9$  mm, respectively. In the central and medial sections, the posterior root of the medial meniscus was adjacent to the anterior PCL attachment. In the medial section, the PCL was present posteriorly and the medial meniscus was present anteriorly, as if to bisect the posterior intercondylar area (PIA). A bony change point existed between the PCL and medial meniscus. The bony trabeculae under the PCL were arranged along the ligament direction. CONCLUSIONS. The bone tunnel for anatomic reconstruction should be created within the PCL attachment area. However, the direct insertion area is not easy to discern by macroscopy. Therefore, the results of our histological evaluation may be useful in anatomic PCL reconstruction.

\*ZUIM DANTAS DE SOUZA, Raissa, Dustin C. LIN, Anastasia K. FILIMONOV, Ann C. ZUMWALT, Jonathan J. WISCO. <sup>1</sup>Boston University School of Medicine, Boston, MA, 02118, USA.

### Exploratory Axillary Dissection of a Transhumeral Amputation: A Cadaveric Study.

INTRODUCTION. In this case report, we had a unique opportunity to investigate a right transhumeral amputation of a 79-year-old male cadaver. In a typical dissection course, students rarely study the results of an amputation of which there is little to no literature available with that description. RESOURCES. We performed an axillary and humeral dissection on both sides, measuring and describing the full lengths of the axillary artery, brachial artery, and terminal branches of the brachial plexus on both non-amputated and amputated arms of the cadaver. We created drawings of the anatomical organization of the neurovasculature indicating the anatomical organization of the vessels after amputation. DESCRIPTION. The axillary anatomy was normal on both sides. The right humerus was amputated below the deltoid tuberosity of the humerus. All brachial plexus terminal branches were present. The musculocutaneous nerve can be seen piercing the coracobrachialis. The radial nerve ran posteriorly to innervate the triceps brachii. The median and the ulnar nerves terminated into stumps at the level of the deltoid tuberosity, which presented as a lump of scar tissue around each nerve ending, possibly indicating the presence of a neuroma. The most distal branches of the axillary artery corresponded to its third part, and the most distal venous drainage was composed of both ends of the cephalic and brachial veins, which terminated at the level of insertion of the deltoid muscle. SIGNIFICANCE. Based on the single case, we discovered the effects of a transhumeral amputation on its associated musculature and neurovasculature. Our documentation will aid in teaching about the anatomical consequences of standard transhumeral amputation procedures.

*continued on next page*