American Association of Clinical Anatomists

36th ANNUAL MEETING

Hosted by The University of Tulsa

THE UNIVERSITY of TULSA











TULSA, OK
JUNE 11-15, 2019



www.clinical-anatomy.org

VISIBLE BODY®

Courseware

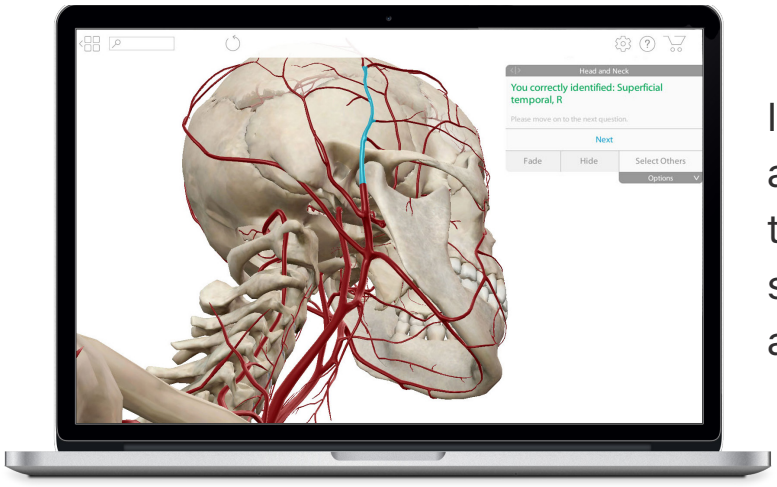

Interactive assignments and dissection quizzes that **engage** your students' passion for anatomy and physiology

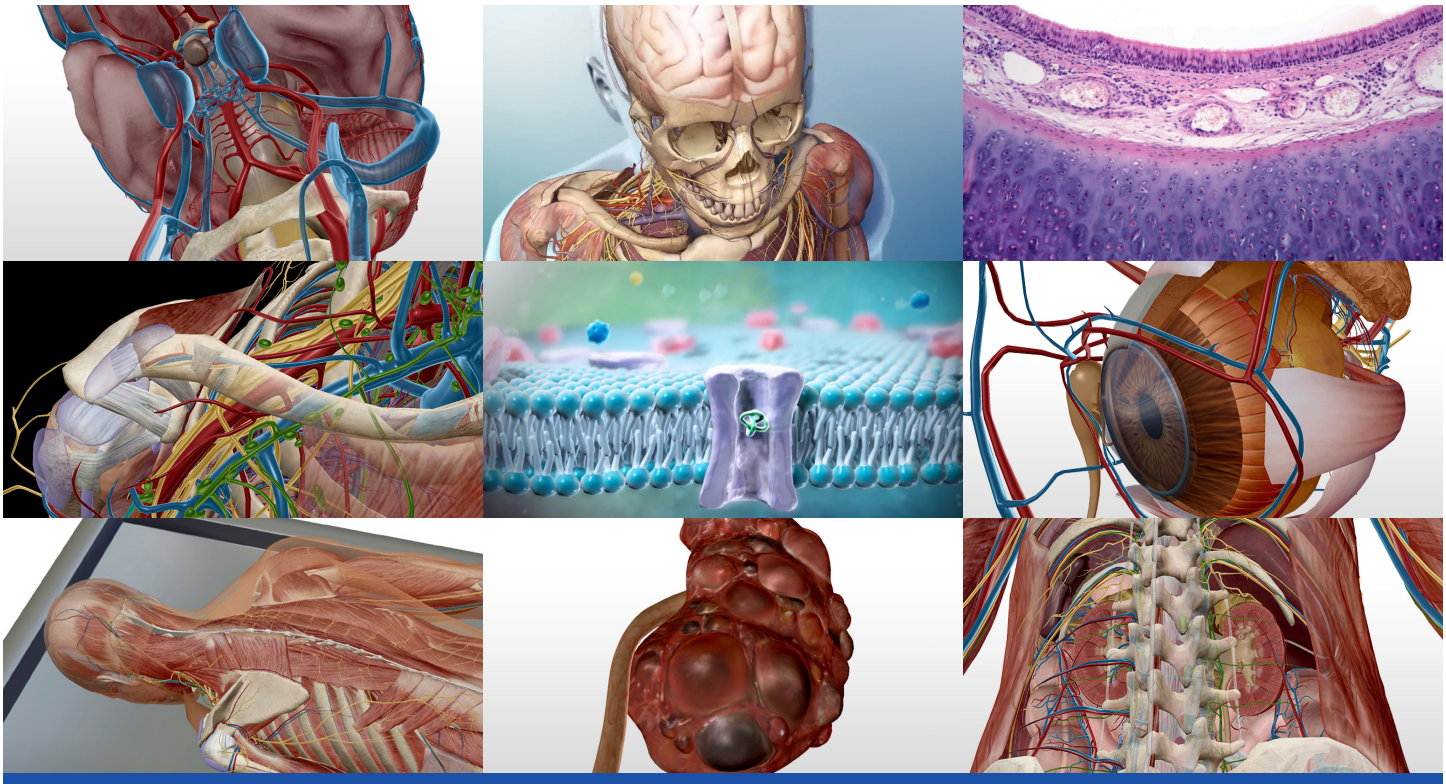

Sign up for a free Courseware instructor trial

visiblebody.com/mycourse

Dear Fellow AACA Members,

The University of Tulsa is proud to host the 36th annual meeting of the American Association of Clinical Anatomists, June 11 – 15, 2019. We look forward to welcoming you to Tulsa. The meeting sessions will take place in the Hyatt Regency in the historic Deco District of downtown Tulsa, which is surrounded by dozens of restaurants, bars, and art and entertainment attractions. For those of you who wish to partake in some sightseeing while you are here, the following information plus the AACA meeting website will help you plan. You should also feel free to contact me with your questions.

Weather – June can be hot and humid. Average highs are 87F (31C), lows are 68F (20C). Average June rainfall is 4.7 inches.

Transportation – Tulsa International Airport (TUL) is located 8 miles northeast of downtown Tulsa. The Hyatt Regency Tulsa offers 24-hour complimentary airport transportation (call the hotel operator at 918-582-9000 when you arrive). Taxis (~$25), Uber, and Lyft (~$15) are the fastest options. Renting a car is very convenient and driving is easy in Tulsa. The airport supports all the usual rental car companies. The hotel provides self-parking or valet parking at reasonable rates.

If you arrive by car, Tulsa is on historic Route 66, which mostly parallels I-44, connecting from Oklahoma City, 110 miles Southwest, or Saint Louis 400 miles Northeast. Dallas is 260 miles South on US Highway 75. Most of the local attractions are easily accessible by car, bus, walking, scooters, or biking. Tulsa has a bike-sharing program with many relay bike stands throughout downtown and surrounding areas. Tulsa Transit is the local public transit system, which provides convenient and inexpensive transportation to some, but not all, venues in Tulsa. 1- and 7-day passes are available at reasonable rates.

Points of Interest – Come early and stay after to enjoy the history, art and architecture of Tulsa and surrounding areas. For example, the annual Tulsa Tough bike races, June 7-9, provide great fun for both bikers and spectators. Check the "Things to do" link on the AACA Meeting website before you arrive and while you are here for useful tips and suggestions. Here are some examples.

- Downtown Tulsa features numerous restaurants, bars, brewpubs, an art museum and galleries, interesting architecture, entertainment venues, and shopping. All of these are within easy walking distance of the hotel. Be sure and take a selfie at the Center of the Universe—it's only 2 blocks from the Hyatt.
- Enjoy dining and shopping downtown, or go by bus or car to "Cherry Street", Brookside, or Utica Square.
- Gathering Place, Tulsa's new 80-acre park, was named the best new attraction in the country this year by USA TODAY.
- Tulsa Museums include The Philbrook Museum of Art, Philbrook Downtown, Woody Guthrie Center, Gilcrease Museum, Tulsa Children's Museum, Greenwood Cultural Center, the Oklahoma Aquarium, and others.
- Visit the beautiful Linnaeus Teaching Garden at Woodward Park and the gardens at the Philbrook Museum of Art.
- Walk/hike along the River Parks trails and Turkey Mountain Urban Wilderness, which encompasses over 300 acres of rugged park land and miles of scenic hiking trails within Tulsa along the Arkansas River.
- Entertainment scheduled during the week at the Brady Theater (near the hotel) include Brit Floyd, a Pink Floyd tribute band, on June 9th, and comedian Eddie Izzard on June 15th. Check them out on YouTube.
- Historic Route 66 runs through Tulsa, not far from the hotel. There are numerous historic attractions along the route. Why not grab a burger at Talley's Diner or lunch at the Mother Road Market?
- Rent a car and take in a double feature at the Admiral Twin Drive in Theater (in business since 1953) or go to the Circle Cinema, a non-profit arthouse theater, for a silent film with musical accompaniment from a restored 1928 pipe organ.
- Brewpubs and tours are numerous. Pearl Brewery Tours will put you on a bus and take you to several breweries.
- For longer trips, in Oklahoma City you will find the Oklahoma City Bombing Memorial and the National Cowboy and Western Heritage Museum. A short trip up Route 66 is Claremore, home of Will Rogers and the Will Rogers Museum. The Pioneer Woman's (Food Network fame) Mercantile and Ranch are a 65-minute drive to Pawhuska.
- For spouses/companions, Elaine has some outings planned. Meet her Wednesday morning (top of the escalators).

Welcome to Tulsa,

Elmus and Elaine Beale
The University of Tulsa, Oxley College of Health Sciences
AACA 36th Annual Meeting local hosts

American Association of Clinical Anatomists

President's Report

June 11-15, 2019

Hyatt Regency Tulsa
Tulsa, OK

PO Box 2945
LaGrange, Ga 30241
Ph: 706-298-0287
www.clinical-anatomy.org

Dear Colleagues and Friends,

It is an honor and pleasure to welcome each of you to the AACA's 36th Annual Scientific Meeting in Tulsa! We are very lucky and privileged to have Elmus Beale from the University of Tulsa as our local host. The Meeting Oversight Planning Committee has given countless hours of their time to organizing the meeting. Also, no welcome to the meeting would be complete without expressing our gratitude to our Program Secretary, Jennifer Burgoon. She has worked tirelessly to make this an outstanding meeting. As always, the AACA Committees alongside the Special Interests Groups have created a spectacular scientific program that I believe everyone will enjoy. I cannot overstress our gratitude to our Executive Director, Caitlin Hyatt, for her contributions to all aspects of preparation and implementation of the Annual Meeting, as well as the running of the Association. Please make an effort to thank each of these members personally for their dedication and efforts for putting together an enjoyable and memorable meeting.

The 2018 AACA regional meeting took place at Georgetown University in October 6th in Washington, DC. The local hosts were Carlos A. Suarez-Quian, Ph.D, Kirsten Brown, Ph.D., Shiloh Jones, Ph.D., D.D Rigamonti, PhD., EC and Stephen Rothwell, Ph.D. There were 38 participants and the speakers were selected to address the role of the foundational science of medicine, anatomy, in the present drive to integrate the various basic science disciplines. In addition, the role of how to assess medical students in the formation of ideal professionals was presented. Finally, attendees heard the unique perspective of training physicians to serve our armed forces from a faculty member from the only medical school to serve this purpose, The University Services University of the Health Sciences (USUHS) in the D.C. area.

The 2019 Presidential speaker will be Dr. Robert G. Louis, Jr., the Program Director of the Skull Base and Pituitary Tumor program at the Hoag Memorial Hospital in Newport Beach, CA. His talk will be on virtual reality anatomy and its applications in neurosurgery. Dr. Louis has been a pioneer on virtual reality applications, and this largely stems from his early exposure to clinical anatomy research. As a medical student, he was presented the AACA's best oral presentation award in 2004 in Moraga, CA and the Sandy Marks Award in 2005 in New York, NY.

Our highest AACA honor this year has been awarded to an outstanding friend and colleague. The recipient of this year's Honored Member Award is Dr. Robert H. Anderson. I have personally known "Bob" for the past 25 years when I was a first-year medical student. Dr. Anderson is recognized as the foremost expert researching the structure and development of the normal and the congenitally malformed heart, with special emphasis on the disposition of the cardiac conduction tissues. He has published over 1,200 papers in peer reviewed journals and has made significant contributions to our journal, Clinical Anatomy. Dr. Anderson is the epitome of the scholar/scientist/research/anatomist/clinician that the AACA strives to have join its long list of Honored Members. Please join us and congratulate Bob Anderson during the meeting for such great achievements.

This year AACA will be awarding the R. Benton Adkins, Jr. Distinguished Service Award to Brian MacPherson, Ph.D. Between 1999-2017, Brian served as an officer in the AACA– 18 years! To put this into perspective, when he finished his term as Past President in 2017, the AACA had just celebrated their 34th year. Thus, up to that point in time, for over 50% of the AACA's existence, Brian was involved. In 1999, Brian was elected to the first of two terms as the Program Secretary. At that time, the Program Secretary did not have all of the help to run a meeting that exists today. For example, there was neither a MOPP Committee nor an Association Management company to assist. Brian handled ALL of the abstracts by himself! For those of us who have been around the AACA for a period of time – how he did that amount of work for six years is amazing. From 2011-2017 Brian served the Presidential cycle and from 2013-2015 he was the 16th President of the AACA. Please take some time to congratulate Brian during the meeting in Tulsa.

One of my objectives has been to promote new members and younger anatomists and we are already realizing this goal. Thanks to Dr. Kazzara Raeburn and the members of the Nominating Committee for presenting an excellent slate of eight candidates for our 2019 ballot. We congratulate all who were on the ballot for their commitment to the AACA, and we welcome the newly elected members of Council. I would also like to thank the outgoing Council Members for their contributions to the Council and the AACA. A special thanks to my close friend, colleague and outgoing Past President Dr. Neil Norton. Neil has contributed tremendously to the Association for the past 10 years as Treasurer and President. We are very lucky and honored to have members like Neil in our Association.

Dr. Shane Tubbs, the editor-in-chief of Clinical Anatomy, continues to enhance the quality and prestige of our Journal, the editorial office and editorial board. A testament of his dedicated work was last year's record high Impact Factor of Clinical Anatomy of 1.908. The total full text downloads for 2018 were the 2nd highest on record with almost 200,000. In 2018, Clinical Anatomy received an all-time record high submission of almost 600 manuscripts. Congratulations to Shane and his team of co-editors and reviewers from their tremendous work.

In December of 2018, as AACA President, I had the privilege of attending the BACA winter meeting. The 2018 BACA winter meeting was co-organized by Dr. James Coey who is a newly elected member to the AACA Council from Newcastle Upon Tyne. Attendance at the BACA Meeting enabled discussion of our mutual concerns and was a reaffirmation of our sister Association's long collegial history. Such representation strengthens our relationships with our sister organization, and we discussed several initiatives that will benefit our members in the future.

AACA finances are the best in the Association's history. Much of this is due to Wiley's renewal contract for the Journal in 2017 and Neil Norton's ability to reshape the finances of the Association as Treasurer and President. We are already reaping the benefits of such solid financial growth and I am excited to provide you with information regarding the management of the endowment funds at our upcoming State of the Association presentation in Tulsa.

Several exciting developments have taken place since our last meeting in Atlanta. We have developed a series of online lectures from our esteemed AACA members. The first one is by Professor Peter Abrahams on "An Anatomical Whodunnit - Michelangelo Sculpture in Bronze."

Similarly, several of our Annual meeting presentations will be recorded and available online for our members. To add to the excitement, we are introducing several research awards for our members at the upcoming meeting in Tulsa namely the best oral and best poster presentation for Clinical Anatomy Educational Research, Clinical Anatomy Translational Research, Senior Faculty and Junior Faculty Research Awards. We are also, for the first time, introducing a Membership Research Award for the best oral and poster presentations voted on by all the participants at the Annual meeting. These awards, totalling $10,000, will recognize the significant efforts of our members toward Clinical Anatomy Research and provide an avenue to promote the high standards of our Association.

We also are launching a biannual Clinical Anatomy Newsletter that will provide valuable information to our members of all current events of Clinical Anatomy Association and its members. Similarly, we will initiate a history of the AACA and its Honored Members on the AACA web page.

In closing, I would like to thank all members of the AACA for their continued support and hard work toward enhancing our field of Clinical Anatomy. As my Presidential term is ending, I am happy to report that we have great momentum because of our strong teamwork. I have been privileged to work with a team of highly skilled individuals and friends who truly care about the AACA and its future. It has been an honor to serve as President of the AACA and I am glad to pass on the "torch" to our next President. Please provide support to our new President as you did so willingly to me. I will continue to humbly support the Association as a Past President with the same passion and enthusiasm.

I look forward to seeing you.

Marios Loukas, M.D. Ph.D.

The AACA believes that each conference attendee should be treated with respect and dignity and that any form of sexual harassment is a violation of human dignity. The AACA condemns sexual harassment and maintains a "zero - tolerance" for sexual harassment. All conference attendees have the right to participate and learn free of sexual harassment. The AACA will take all reasonable efforts to prevent and promptly correct instances of sexual harassment. Any conference attendee who believes himself or herself to be a victim of sexual harassment is encouraged to report the information to the Program Secretary.

AACA on Social Media

Like Us on Facebook!

News | Events | Connect

Like AACA on Facebook to stay up-to-date on all the latest news and events and to connect with other members.

American Association of Clinical Anatomists

Visit https://www.facebook.com/aacapage/ or scan the code with your phone!

Follow us at the AACA Linkedin Page

To stay up to date with the news

Discover new job opportunities

Connect to other members

Go to https://www.linkedin.com/company/american-association-of-clinical-anatomists

Or scan with your phone using any QR code reader

Tweet with Us! @AACAnatomy

American Association of Clinical Anatomists

@AACAnatomy is the Association's official Twitter account

We use Twitter to increase engagement with our Membership, professionals, and the public.

Join us on Twitter!

New to Twitter?

Use these steps to make an account!

1. Go to www.twitter.com
2. Click Log-in
3. Select Sign Up under "New to Twitter?"
4. Create username and password
5. Sign Up!
6. Find our account @AACAnatomy and follow
7. Tweet away! Share tweets all meeting long using the conference hashtag **#ClinAnat19**

Already on Twitter?

Follow @AACAnatomy and share conference tweets using the hashtag **#ClinAnat19**! Feel free to tweet anything that interests you during the conference – sessions, events, what you learn, posters, social gatherings, meetings, photos, etc. You can also tweet anytime using the hashtag #ClinAnat.

Ask your colleagues if they have a Twitter account. Follow AACA members and colleagues to make our Twitter community even stronger!

Pick up your "*I Tweet*" ribbon at the registration desk!

Hyatt Regency Hotel Meeting Space WiFi Code: AACAnatomy19

Save the Dates!







Mark your calendar for these upcoming events!

Table of Contents

Floorplan of Hotel Meeting Space 1

Block Schedule of Events 2

Acknowledgement and Thanks to our Sponsors and Exhibitors 3

Information on Food/Beverage around Hyatt Regency Tulsa 6

Pre-Meeting Events 7

Scientific Program 7

Presidential Speaker – Robert G Louis, MD, FAANS
"From Formalin to Fighter Jets: Anatomical Considerations"
Sponsored by Wiley 13

Honored Member – Robert H. Anderson, BSc, MD, FRCPath 14

Distinguished Service Award – Brian R. MacPherson, Ph.D. 15

Career Development Committee Symposium – *"Facing the Imposter"* 16

Invited Speaker #1 – *"Neural Highways and Peripheral Nerve Tumors."* Robert Spinner, MD 19

Invited Speaker #2 – *"The Impact of Clinical Anatomy on Translational and Reverse Translational Research"* Marios Loukas, MD 20

Clinical Anatomical Terminology Committee Symposium-
The Clinical Anatomical Terminology Conundrum 21

Poster Listing

- Poster Session 1 22
- Poster Session 2 24
- Poster Session 3 26

Annual Business Meeting Agenda 29

Annual Business Meeting Minutes – Atlanta, GA 30

Officers of the AACA Council 33

Clinical Anatomy – The Official Journal of AACA 34

Committee Reports 35

- Anatomical Services Committee
- Brand Promotion and Outreach Committee
- Career Development Committee
- Clinical Anatomical Terminology Committee
- Educational Affairs Committee
- Journal Committee
- Listserv Report
- Membership Committee
- Meeting Organization and Program Planning Committee
- Nominating Committee

Abstract Listing by Author

- Platform Presentations 44
- Poster Presentations 52

Floor Plan of the Hotel



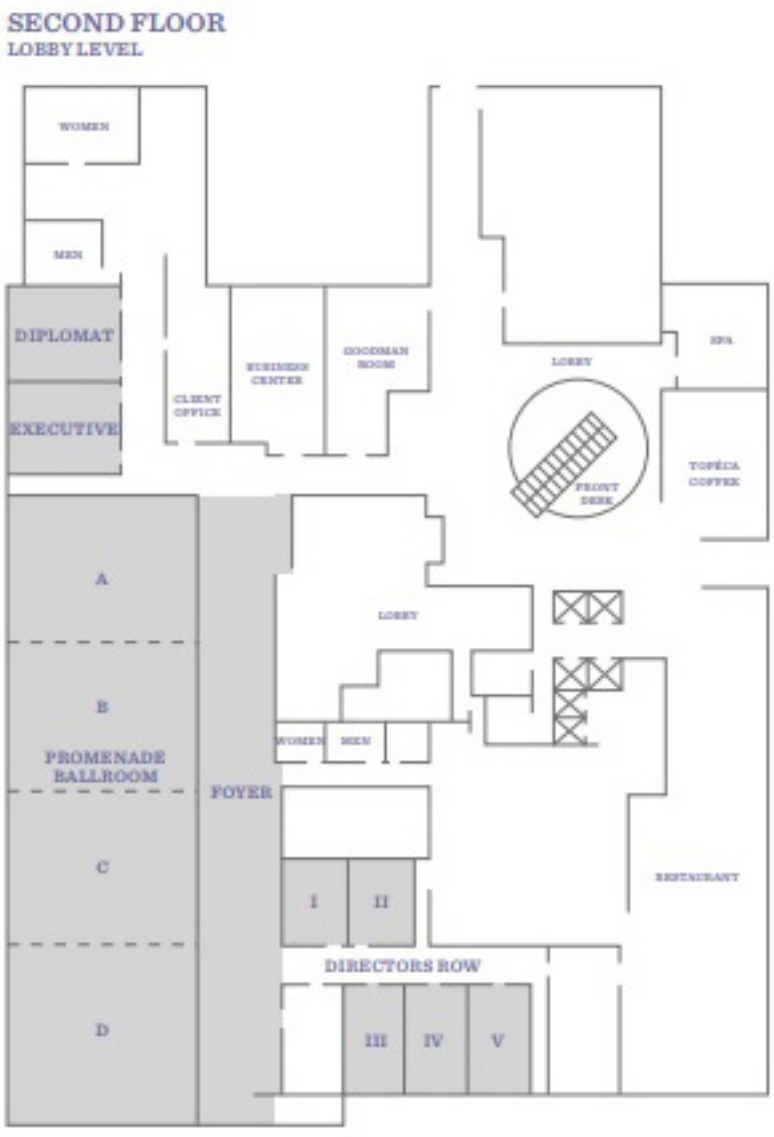

Block Schedule

As of 05/16/19

	Tuesday, June 11th	Wednesday, June 12th	Thursday, June 13th	Friday, June 14th
7:30	Registation OPEN 12:00 pm - 5:45 pm (Tulsa Central Foyer)	**Clin Anatomical Term Comm** Evan Goldman/Chelsea Lohman Bonfigilio (Promenade C) 7:30 - 9:00 am	**Career Development Comm** Sarah Greene (Promenade C) 7:30 - 9:00 am	**Educational Affairs Comm** Lela Giannaris (Promenade C) 7:30 - 9:00 am
7:45				
8:00				
8:15				
8:30		Breakfast/Poster/Exhibitors (Tulsa North & Central)	Breakfast/Poster/Exhibitors (Tulsa North & Central)	Breakfast/Poster/Exhibitors (Tulsa North & Central)
8:45				
9:00	**AACA Council Meeting** (Executive Room) 9:00 am - 5:00 pm	Welcome & State of the Assn by Marios Loukas (Tulsa South) 9:00 - 9:45 am	Opening Announcements	Opening Announcements
9:15			**Invited Speakers - Robert Spinner & Marios Loukas** (Tulsa South) 9:15- 10:30 am	**Poster Session 3** **Education & Anatomical Svcs** (Tulsa North & Central) 9:15 - 10:30 am
9:30				
9:45		**Presidential Speaker** **Robert Louis** (Tulsa South) 9:45 - 10:45 am		
10:00				
10:15				
10:30			**Poster Session 2** **Head, Neck & Upper Limb** (Tulsa North & Central) 10:30 - 11:45 am	**Anatomical Svcs Comm** David Conley & Bobbi Morgan (Promenade C) 10:30 am - 12:00 pm
10:45		BREAK		
11:00		**Platform Session 1** **Head and Neck** (Tulsa South) 11:00 - 11:30 am		
11:15				
11:30		**Lunch Break On Your Own** (See Page 6) 11:30 am - 1:00 pm [*Clinical Anatomy* Editorial Board Lunch Mtg (Invitation Only) (Promenade A]		
11:45			**Lunch Break On Your Own** (See Page 6) 11:45 am - 1:00 pm	
12:00				**Lunch Break On Your Own** (See Page 6) 12:00 - 1:30 pm [Award Committee Lunch Mtg (Invitation Only)]
12:15				
12:30				
12:45				
1:00		**CDC Symposium** Facing the Imposter (Tulsa South) 1:00 - 2:30 pm	**CAT Symposium** The Clinical Anatomy Terminology Conundrum (Tulsa South) 1:00 - 2:30 pm	**Business Mtg** **Everyone is encouraged to attend!** (Tulsa South) 1:30 - 3:00 pm
1:15				
1:30				
1:45				
2:00				
2:15				
2:30		BREAK	BREAK	BREAK
2:45		**Poster Session I** **Torso & Lower Limb** (Tulsa North & Central) 2:45 - 4:00 pm	**Platform Session 3** **Torso** (Tulsa South) 2:45 - 3:45 pm	**Mtg of the New Council** (Executive Room) 3:15 - 4:15 pm
3:00				
3:15				
3:30				
3:45			BREAK	
4:00		**Platform Session 2** **Upper and Lower Limbs** (Tulsa South) 4:00 - 5:45 pm	**Platform Session 4** **Education** (Tulsa South) 4:00 - 5:45 pm	BREAK
4:15				
4:30				
4:45				
5:00	**Judges Meeting** (Promenade C) 5:00 - 6:00 pm			**Reception** (Promenade Foyer) 5:00 - 6:00 pm
5:15				
5:30				
5:45		BREAK	BREAK	
6:00		**Mentor Reception** (Promenade D) 6:00 - 7:00 pm		**Awards & Banquet** Honored Member Talk 6:00 - 8:00 pm (Promenade ABC)
6:15				
6:30	**Welcome Reception** (Promenade A&B) 6:30 - 8:30 pm		**Social at Gilcrease Museum** 7:00 pm - 9:00 pm (First bus leaves at 6:30PM)	
6:45				
7:00				
>7 pm				

Sponsors/Commercial Exhibitors

Generous donations and/or commercial exhibitor fees paid by the following companies and organizations have substantially reduced the Association's expenses in presenting this meeting.

You are encouraged to visit the exhibits available for viewing in Tulsa North and Central Ballrooms.

Exhibit hours:

11:00 am - 5:00 pm Tuesday (set up)
8:00 am – 12:00 pm and 1:00 pm – 5:00 pm Wednesday
8:00 am – 12:00 pm and 1:00 pm – 5:00 pm Thursday
8:00 am – 11:00 am Friday

TEAR DOWN is from 11:00 am – 4:00 pm on Friday (all exhibitors must be vacated from the hall at 4:00 pm)

The hall will be closed for lunch for one hour each day (12:00 – 1:00 PM).

LIST OF EXHIBITORS *as of 5-1-19*

Booth 1.
Elsevier

1600 JFK Blvd., Ste. 1600
Philadelphia, PA 19103
www.elsevierhealth.com

Elsevier is a world-leading provider of information solutions that enhance the performance of science, health and technology professionals via web, published journals and more.

Booth 2.
Primal Pictures (AKA Informa)

605 3rd Ave, Floor 20
New York, NY 10158
www.primalpictures.com

The world's most medically accurate and detailed 3D digital human anatomy resources and solutions.

Booth 3.
Bone Clones

9200 Eton Avenue
Chatsworth, CA 91311
www.boneclones.com

Bone Clones, Inc. manufactures detailed, high-quality osteological reproductions of skeletal elements. In addition to producing specimens exhibiting trauma and pathology, we have an extensive range of skulls and skeletons providing age, sex, and ancestry differences. Our durable replicas obviate the need for a dedicated teaching collection of real human remains.

Booths 4&5.
Toltech

12635 E. Montview Blvd, Ste. 350
Aurora, CO 80045
www.toltech.net

Come to experience our highly interactive solutions for anatomy, clinical imaging and pathology based on Visible Human Project® data and patient scans. From the Sectra Table to the VH Dissector software we have solutions for small group and self study along with features for full curriculum integration and development.

continued on next page

Tulsa Central and North Ballrooms

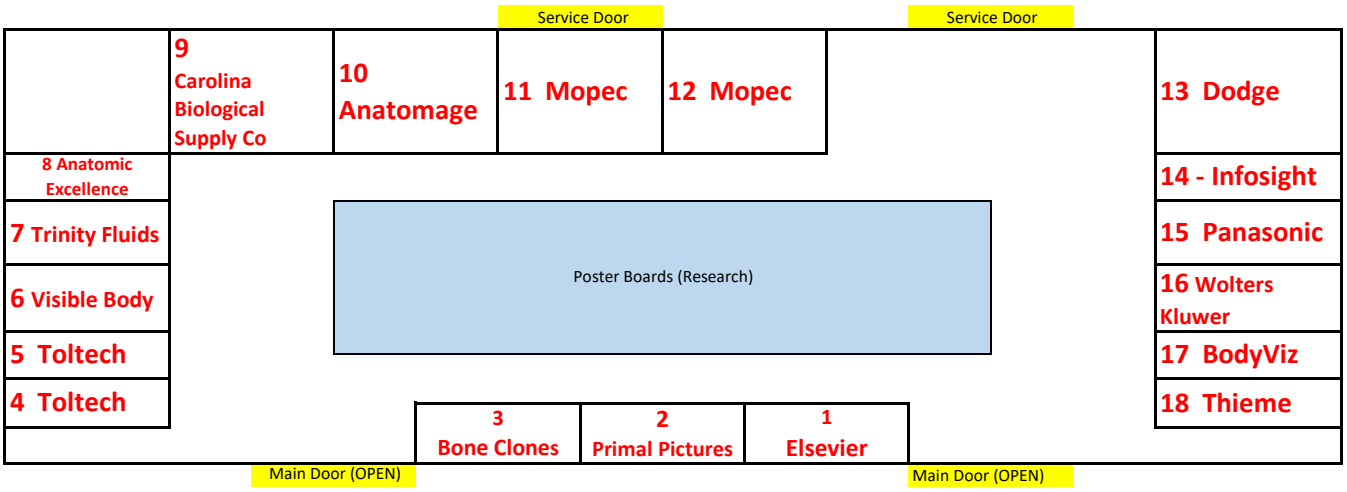

Booth 6.
Visible Body

109 Oak Street, Suite 203
Brookfield, MA 01506
www.visiblebody.com

3D Anatomy & Physiology resources for students and professionals.

Booth 7.
Trinity Fluids

PO Box 832
Lapeer, MI 48446
www.trinityfluids.com

Anatomical Chemicals, Supplies, & Equipment.

Booth 8.
Anatomic Excellence

1013 Ashley Road
Savannah, GA 31410
http://anatomicexcellence.com/

Anatomic Excellence, LLC is the exclusive FULL RANGE sales agent for Dr. Gunther von Hagens Plastinated Human Tissue Specimens in the USA, Canada, and Caribbean. We are committed to working with our customers to help them establish a collection of specimens that meets the educational needs of their program; and allows them to enhance the anatomical education process at both the artistic and scientific level.

Booth 9.
Carolina Biological Supply Co.

2700 York Road
Burlington, NC 27215
www.carolina.com

Effective anatomy and physiology starts with the right tools. Carolina delivers high quality models, skeletons, preserved specimens, and other lab marterials needed for success. Formalin-free Carolina Perfect SolutionTM dissection specimens are lifelike and safe for students and the environment with no dangerous off-gassing.

Booth 10.
Anatomage

303 Almaden Blvd
San Jose, CA 95110
www.anatomage.com

Anatomage is a medical company driving innovation through advanced solutions in hospitals and educational institutions. Our products include medical tables, surgical devices, and radiology software.

Booths 11&12.
Mopec

21750 Coolidge Hwy
Oak Park, MI 48237
www.mopec.com

Mopec provides American-made equipment and supplies to anatomy laboratories, pathology labs, animal research facilities and medical examiner facilities. Founded in 1992, Mopec solutions are among the very best as demonstrated by the vast number of installations in America's top healthcare institutions and universities. Our reputation is built on decades of superior customer service specializing in consultation and customization. Mopec is committed to designing and manufacturing ergonomic equipment to enhance your lab's safety, flexibility and productivity.

Booth 13.
Dodge

9 Progress Road
Billerica, MA 01821
www.dodgeco.com

Embalming chemicals, cosmetics, urns, instruments.

Booth 14.
Infosight

PO Box 5000, 20700 US Hwy 23
Choollicothe, OH 45601
www.infosight.com

InfoSight is a manufacturer of industrial marking machines, metal tags, metal tag printers, barcode readers and custom machinery for manual and automatic identification and traceability applications worldwide.

Booth 15.
Panasonic

2 Riverfront Plaza
Newwark, NJ 07102
https://na.panasonic.com/us

Medical cameras.

Booth 16.
Wolters Kluwer

2001 Market Street
Philadelphia, PA 19103
www.lww.com

Wolters Kluwer Health is a leading global provider of information and point of care solutions for the healthcare industry. Our solutions are designed to help professionals build clinical competency and improve practice so they can make important decisions on patient care. Our leading product brands include Audio-Digest, Lippincott, Ovid®, UpToDate®, and others.

Booth 17.
BodyViz

88058 Chambery Blvd., Ste. 300-242
Johnston, IA 50131
www.bodyviz.com

3D Anatomy Visualization Software.

Booth 18.
Thieme

333 7th Avenue
New York, NY 10001
www.thieme.com

Medical book for students and professionals.

2019 AACA Corporate Sponsors *as of 5-1-19*

Gold

ELSEVIER

Silver

Anatomic Excellence

Bronze

WILEY

2019 Member Sponsorship Donors *as of 5-1-19*

Interested in becoming a member sponsor donor?
Visit ***https://clinical-anatomy.org/Member_Sponsorship*** *for more details.*

Ruby Level ($250)

Lawrence Wineski, Ph.D.

Dining Options

Inside the Hotel

Daily Grill
Open for Breakfast, Lunch and Dinner
6:30 a.m.–1:00 a.m.

Daily Grill Lounge
Sunday–Saturday 11:00 a.m.–1:00 a.m.
Monday–Friday 4:00 p.m.–7:00 p.m.

Outside of the Hotel

0.4 Miles
Tavolo: an Italian Bistro
Monday–Friday 11:00 a.m.–10:00 p.m.
Saturday: 4:00 p.m.–10:00 p.m.
(918) 949-4498

0.5 Miles
Lassalle's New Orleans Deli
Monday–Thursday 11:00 a.m.–4:00 p.m.
Friday 11:00 a.m.–9:00 p.m.
(918) 582-6652

0.5 Miles
The Sushi Place
Monday 10:00 a.m.–2:00 p.m.
Tuesday–Friday 10:00 a.m.–2:00 p.m.,
5:00–8:30 p.m.
Saturday 4:30 p.m.–8:30 p.m.
(918) 574-8518

0.7 Miles
Caz's Cowhouse
Tuesday–Thursday 11:00 a.m.–9:00 p.m.
Friday–Saturday 11:00 a.m.–11:00 p.m.
Sunday 11:00 a.m.–9:00 p.m.
(918) 588-2469

0.6 Miles
Amelia's
Monday 4:00 p.m.–10:00 p.m.
Tuesday–Thursday 11:00 a.m.– 10:00 p.m.
Friday 11:00 a.m.–11:00 p.m.
Saturday 4:00 p.m.–11:00 p.m.
(918) 728-2435

0.3 Miles
El Guapo's
Monday–Thursday 11:00 a.m.–10:00 p.m.
Friday–Saturday 11"00 a.m.–11:00 p.m.
Sunday 11:00 a.m.–10:00 p.m.
(918) 382-7482

For more information on Restaurant Options and Things To Do in Tulsa, please visit the AACA website!
https://clinical-anatomy.org/content.php?page=Things_To_Do

Depend on Elsevier for the best Anatomy resources

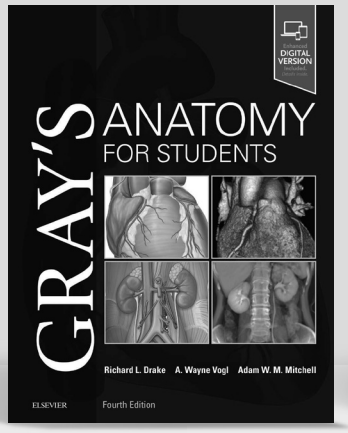



ELSEVIER Learn more at elsevierhealth.com

Pre Meeting Events

Tuesday, June 11th

9:00 AM - 11:00 AM	Exhibitor Freight Delivery	Tulsa North and Central
9:00 AM – 5:00 PM	AACA Council Meeting	Executive Room
11:00 AM – 5:00 PM	Exhibitor Set-Up	Tulsa North and Central
12:00 PM – 5:00 PM	Poster Presenter Set-Up	Tulsa North and Central
12:00 PM – 5:45 PM	Registration	Tulsa Ballroom Foyer
5:00 PM – 6:00 PM	Judges' Meeting	Promenade C
6:30 PM – 8:30 PM	Welcome Reception	Promenade A&B

Scientific Program

Wednesday, June 12th

7:30 AM – 9:00 AM	Clinical Anatomical Terminology Committee Meeting – Open to all *Sponsored by Anatomic Excellence*	Promenade C
7:30 AM – 9:00 AM	Breakfast with Exhibits/Posters *Sponsored by Elsevier*	Tulsa North and Central
7:30 AM - 5:00 PM	Bidding on Silent Auction Open	Oklahoma South
8:00 AM – 5:00 PM	Registration	Tulsa Ballroom Foyer
8:00 AM – 11:30 AM	Poster Presenter Set-Up	Tulsa North and Central
8:00 AM – 5:00 PM	Exhibit Hall Open *Closed from 12:00 PM – 1:00 PM*	Tulsa North and Central
9:00 AM – 9:45 AM	Opening of Scientific Session - Welcome Marios Loukas, M.D. President, American Association of Clinical Anatomists Robin Ploeger, EdD Thomas E. Oxley Dean of the Oxley College of Health Sciences, The University of Tulsa	Tulsa South
9:45 AM – 10:45 AM	Presidential Speaker: Robert G Louis, MD, FAANS *"From Formalin to Fighter Jets: Anatomical Considerations"* *Sponsored by Wiley*	Tulsa South
10:45 AM – 11:00 AM	Break with Exhibits/Posters	Tulsa North and Central
11:00 AM	Deadline to drop off Silent Auction Items	Oklahoma South

continued on next page

Wednesday, June 12th continued

11:00 AM – 11:30 AM — Platform Session I: Head and Neck ..... Tulsa South
Moderator: Jennifer Burgoon

11:00 AM — Branching Patterns of the Mental Nerve. **KING**, Sarah D., Russell ARELLANES, Victoria GORDON and Anthony OLINGER. Department of Anatomy, Kansas City University of Medicine and Biosciences, Kansas City, MO, 64106, USA. **GER**

11:15 AM — Immunohistochemical Analysis of Adrenergic Receptor Density in Cadaveric Cerebrovasculature. **SHAFFER**, Harry G.[1], Stanley BENKOVIC[2], Divine NWAFOR [2], and Ashley B. PETRONE [1,3]. [1]Department of Pathology, Anatomy and Laboratory Medicine, West Virginia University, Morgantown WV, 26506, USA. [2]Department of Physiology and Pharmacology, West Virginia University, Morgantown WV, 26506, USA. [3]Department of Neurology, West Virginia University, Morgantown WV, 26506, USA.

11:30 AM – 1:00 PM — Lunch on your Own – See page 6 for options

11:30 AM – 1:00 PM — *Clinical Anatomy* Editorial Board Lunch (Invitation Only) ..... Promenade A

1:00 PM – 2:30 PM — Career Development Committee Symposium ..... Tulsa South
"Facing the Imposter"

2:30 PM – 4:00 PM — Break with Exhibits/Posters ..... Tulsa North and Central

2:45 PM – 4:00 PM — Poster Session 1: Torso & Lower Limb ..... Tulsa North and Central

4:00 PM – 5:45 PM — Platform Session 2: Upper Limb ..... Tulsa South
Moderator: Melissa Quinn

4:00 PM — Variation: The Rule Not the Exception. **THIELE**, Cameron M.[1], Sonya E. VAN NULAND[2], and Natalie R. LANGLEY[2]. [1]Mayo Clinic Alix School of Medicine, Scottsdale, AZ 85259, USA. [2]Department of Anatomy, Mayo Clinic College of Medicine and Science, Scottsdale, AZ 85259, USA. **GER**

4:15 PM — Novel Investigation of the Deep Band of the Lateral Plantar Aponeurosis and Lateral Plantar Nerve. **BECK**, Cameron M.[1], Austin DICKERSON[1], Kevin KADADO[1], Zach COHEN[2], Somer BLAIR[2], Jenna HOLCOMB[1], and Cara FISHER[1]. [1]Center for Anatomical Sciences, University of North Texas Health Science Center, Fort Worth, TX, 76107, USA; [2]John Peter Smith Hospital, Fort Worth, TX, 76104, USA. **GER**

4:30 PM — Trapezius Architecture in Infancy and Adulthood: Preliminary Developmental Insights. **STIVER**, Mikaela L.[1,2,] Luke R. BRADSHAW[3], Ethan M. BREINHORST[3], Anne M.R. AGUR[1,2], and S. Ali MIRJALILI[3]. [1]Division of Anatomy, Department of Surgery, University of Toronto, Toronto, ON, M5S 1A8, Canada; [2]Rehabilitation Sciences Institute, University of Toronto, Toronto, ON, M5G 1V7, Canada; [3]Department of Anatomy with Medical Imaging, Faculty of Medical and Health Sciences, University of Auckland, Auckland, 1142, New Zealand. **GER**

4:45 PM — Anatomical Study of Innervation of Ankle Joint Capsule: Implications for Image-Guided Intervention. **HAN**, John R.[1], John TRAN[1], Philip W.H. PENG[2], and Anne M.R. AGUR[1].[1]Division of Anatomy, Department of Surgery and [2]Department of Anesthesia, University of Toronto, Toronto, ON, M5S 1A8, Canada. **GER**

5:00 PM — Comprehensive Visualisation and Quantification of the Radiocarpal and Intercarpal Ligaments. **FOGG**, Quentin A. Department of Anatomy and Neuroscience, The University of Melbourne, Melbourne, VIC, 3010, Australia. **GER**

5:15 PM — Can a Telementor Improve Incision Placement and Vessel Identification in Exposure of Femoral Artery? **AGANDI**, Lorreen A., Kristy R. PUGH, Samuel A. TISHERMAN, and Adam C. PUCHE. School of Medicine, University of Maryland, Baltimore, MD, 21201, USA.

continued on next page

5:30 PM — Superior, Middle, and Inferior Parts of Infraspinatus: Do They Have Differing Functional Roles? **VILDE**, Tomas A.[1], Allen DUONG[1], Valera CASTANOV[1], Jason HERMENEGILDO[1], Soo Y KIM[2], and Anne M.R AGUR[1]. [1]Division of Anatomy, Department of Surgery, University of Toronto, Toronto, ON M5S 1A8, Canada; [2]School of Rehabilitation Science, College of Medicine, University of Saskatchewan, Saskatoon, SK S7N 2Z4, Canada. **GER**

6:00 PM – 7:00 PM — Mentor Reception ..... Promenade D

Scientific Program

Thursday, June 13th

7:30 AM – 9:00 AM — Career Development Committee Breakfast Meeting – Open to all ..... Promenade C

7:30 AM – 9:00 AM — Breakfast with Exhibitors ..... Tulsa North and Central

7:30 AM - 5:00 PM — Bidding on Silent Auction Open ..... Oklahoma South

8:00 AM – 5:00 PM — Registration ..... Tulsa Ballroom Foyer

8:00 AM – 5:00 PM — Exhibit Hall Open ..... Tulsa North and Central
Closed from 12:00 PM – 1:00 PM

9:00 AM – 9:15 AM — Opening Announcements ..... Tulsa South

9:15 AM – 10:30 AM — Invited Speakers - Dr. Robert Spinner and Dr. Marios Loukas ..... Tulsa South

10:30 AM – 11:45 AM — Break with Exhibits/Posters ..... Tulsa North and Central

10:30 AM – 11:45 AM — Poster Session 2: Head, Neck & Upper Limb ..... Tulsa North and Central

11:45 AM – 1:00 PM — Lunch break on your own – see page 6 for information

1:00 PM – 2:30 PM — Clinical Anatomical Terminology Committee Symposium
The Clinical Anatomical Terminology Conundrum ..... Tulsa South

2:30 PM – 2:45 PM — Break with Exhibits/Posters ..... Tulsa North and Central

2:45 PM – 3:45 PM — Platform Session 3: Torso ..... Tulsa South
Moderator: Sarah Greene

2:45 PM — Wolff Parkinson White and Other Matters of the Heart – A Description of a Morphological Anomaly. **SCHREINER,** Gabriella and Darren SALMI. Division of Clinical Anatomy, Department of Surgery, School of Medicine, Stanford University, Stanford, CA 94305, USA. **GER**

3:00 PM — Photographic Demonstration of Actual Dissection of Lymphatic Relationships: Esophagus and Stomach. **SATO,** Tatsuo. Tokyo Medical and Dental University, Tokyo, 113-0023, Japan.

3:15 PM — Relationship Between Wrist Circumference and Left Ventricular Structure in Adult Cadavers. **ISMAILOV**, Eugene L., Derek SCHIRMER, Russell ARELLANES, Andrew DANG, Karen TONG, Angela WANG-SELFRIDGE, Zakary ROSE-RENEAU, Tatum B. COLBURN, and Anthony B. OLINGER. Department of Anatomy, College of Medicine, Kansas City University, Kansas City, MO, 64106, USA. **GER**

3:30 PM — Relevant Morphological Pelvic Variation in Mid-Urethral Sling Surgeries. **DIETZ**, Bernhard E., Megan L. BRUINIUS, Evan D. CRAWFORD, and Adam KOLATOROWICZ. Department of Anatomy, Lincoln Memorial University-Debusk College of Osteopathic Medicine, Harrogate, TN, 37752, USA. **GER**

4:00 PM – 4:15 PM — Break with Exhibits/Posters ..... Tulsa North and Central

4:00 PM – 5:45 PM — Platform Session 4: Education ..... Tulsa South
Moderator: Greg Smith

continued on next page

Thursday, June 13th continued

4:00 PM — Augmented Reality for Regional Anesthesia (AR4RA): A 3D Education Tool for Image-Guided Procedures. **TRAN,** John[1], Philip W.H. PENG[2], and Anne M.R. AGUR[1]. [1]Division of Anatomy, Department of Surgery, Faculty of Medicine, University of Toronto, Toronto, ON M5S 1A8, Canada; [2]Department of Anesthesia, Faculty of Medicine, University of Toronto, Toronto, ON M5T 2S8, Canada. **GER**

4:15 PM — Segmentation and Identification of Massive, Three Dimensional Image Data (Visible Human Style). **SPITZER,** Victor M. Center for Human Simulation, University of Colorado School of Medicine, Aurora, CO 80045, USA

4:30 PM — Is there a Shortage of Anatomy Educators? An International Study. **WILSON**, Adam B.[1], Andrew NOTEBAERT[2], Audra F. SCHAEFER[2], Bernard MOXHAM[3], Shiby STEPHENS[3], Caroline MUELLER[2], Michelle D. LAZARUS[4], Aaron KATRIKH[1], and Williams S. BROOKS[5]. [1]Department of Cell and Molecular Medicine, Rush University, Chicago, IL 60612, USA; [2]Department of Neurobiology and Anatomical Sciences, University of Mississippi Medical Center, Jackson, MS 39216, USA; [3]School of Biosciences, Cardiff University, Cardiff, Wales CF10 3AX, UK; [4]Department of Anatomy and Developmental Biology, Monash University, Clayton, Victoria 3800, AU; [5]Department of Cell, Developmental, and Integrative Biology, University of Alabama at Birmingham, Birmingham, AL 35233, USA.

4:45 PM — Getting the Most Out of Limited Anatomy Time in an Integrated Curriculum**. PETTIT**, L. Diana, Heather A. BALSIGER, Ricardo BELMARES, Thomas GEST, and Dolgor BAATAR. Department of Medical Education, Paul L. Foster School of Medicine, Texas Tech University Health Sciences Center El Paso, El Paso, TX, 79905, USA.

5:00 PM — Longitudinal Integration of Anatomy: Advanced Anatomy Competencies in Medical Education. **KALMAR,** Eileen L., Melissa M. QUINN, and Kirk M. MCHUGH. Department of Biomedical Education and Anatomy, College of Medicine, The Ohio State University, Columbus, OH, 43210, USA.

5:15 PM — Influence of a Brief Ultrasound Exposure in Anatomy on Students' Spatial Ability. **RICHTER**, Saskia D., Cailee E. WELCH BACON, and Kellie C. HUXEL BLIVEN. A. T. Still University, Mesa, AZ, 85206, USA. **GER**

5:30 PM — The Donor Rose Ceremony – Providing Closure and Promoting Humanism in the Anatomy Lab. **GIANNARIS,** Eustathia Lela, Amanda J. COLLINS, and Yasmin CARTER. Division of Translational Anatomy, Department of Radiology, University of Massachusetts Medical School, Worcester, MA, 01655, USA.

7:00 PM – 9:00 PM — Reception at Gilcrease Museum – Pre Registration Required
Buses will load in front of the Hyatt on 2nd Street from 6:00 PM – 6:30 PM

continued on next page

Scientific Program

Friday, June 14th

7:30 AM – 9:00 AM	Educational Affairs Committee Breakfast Meeting - open to all	Promenade C
7:30 AM – 9:00 AM	Breakfast with Exhibitors	Tulsa North and Central
7:30 AM - 10:30 AM	Bidding on Silent Auction Open	Oklahoma South
8:00 AM – 5:00 PM	Registration	Tulsa Ballroom Foyer
8:00 AM – 11:00 AM	Exhibit Hall Open	Tulsa North and Central
9:00 AM – 9:15 AM	Opening Announcements	Tulsa South
9:15 AM – 10:30 AM	Break with Exhibits/Posters	Tulsa North and Central
9:15 AM – 10:30 AM	Poster Session 3: Education and Anatomical Services	Tulsa North and Central
10:30 AM– 12:00 PM	Anatomical Services Committee Meeting – All Invited	Promenade C
10:30 AM	Silent Auction Closes (pick up items starting at 1:00 PM at Registration)	Oklahoma South
10:45 AM	All Posters must be removed (pick up at Registration if left unclaimed)	Tulsa South
11:00 AM – 4:00 PM	Exhibitor Tear Down	Tulsa North and Central
12:00 PM - 1:30 PM	Award Committee Lunch Meeting (Invitation Only)	Directors Row 3
12:00 PM – 1:30 PM	Lunch Break on your own – See page 6 for information	
1:00 PM – 3:45 PM	Claim Silent Auction Items	Registration
1:30 PM – 3:00 PM	Business Meeting – Everyone is encouraged to attend!	Tulsa South
3:15 PM – 4:15 PM	New AACA Council Meeting	Executive
5:00 PM – 6:00 PM	Reception	Promenade Foyer
6:00 PM – 8:00 PM	Banquet	Promenade A,B,C

Assistant/Associate/Full Professor of Preclinical Sciences (Anatomy)

William Carey University COM is looking for anatomists interested in combining and leveraging their knowledge and experience of anatomy with the development of innovative methods for anatomical teaching and curricular design towards supporting comprehensive anatomical support primarily for the first-year (OMS1) but including supporting services for OMS2 through OMS4. Active interaction with both the basic sciences and clinical faculty will be expected.

Under the respective course director(s) and the Associate Dean, Preclinical Sciences, the successful candidate will provide instruction in one or more of the anatomical sub-disciplines, including embryology, histology, gross anatomy, neuroanatomy and medical imaging. The ultimate goal is to form a solid foundation in this critical science, and create testable inter-dependencies with other disciplines, such as biochemistry, physiology, pathology and clinical skills, including osteopathy using the curricular model database. In particular, we are interested in the thorough inclusion of medical imaging (i.e.: x-ray, CT, MRI, US) into both lecture and laboratory sessions of our anatomy program. The radiology software application OSIRIX currently plays an active role in this in the dissection laboratory. Live ultrasound demonstrations will have significant representation in our courses based on the application of our kiosk machines. Additionally, ultrasound student simulators will expand the direct experience with standard US cases. The Radiology SIG will have a role in tutoring basic imaging concepts and cases to all interested students across all four years with their website which will accumulate cases and RSNA journal concept papers relevant to each anatomical region and system.

WILLIAM CAREY
UNIVERSITY

Please visit https://www.wmcarey.edu/Office/human-resources or contact Dr. Kamal Abouzaid MD, PhD, Assistant Professor, Preclinical Sciences at Kabouzaid@wmcarey.edu for more information.

Anatomic Excellence
anatomicexcellence.com

Visit us at
Booth #8
for the Finest
Plastinated
Tissue Specimens
from Dr. Gunther
von Hagens.

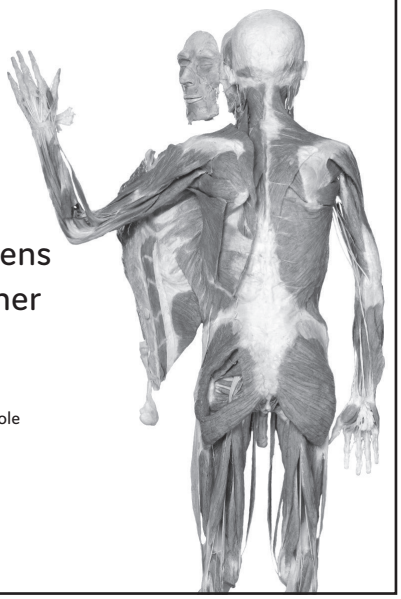

Anatomic Excellence is the sole source full range agent for:

von Hagens Plastination
REAL ANATOMY FOR TEACHING

The 2019 Presidential Speaker

Wednesday, June 12th at 9:45 AM

Robert G. Louis, MD, FAANS



"From Formalin to Fighter Jets: Anatomical Considerations"

I will be speaking about my beginnings as an anatomist and AACA member in medical school. I will discuss how my love of anatomy propelled me to publish numerous papers with Dr Loukas while in school. This was the key factor in supporting my application to neurosurgery residency. Throughout residency, I continued to study and teach anatomy, both in our Anatomical Dissection Laboratory and at medical schools. Since completing residency, I have turned to the development of Virtual Reality and Augmented Reality Technologies in order to help both surgeons and patients gain a better understanding of their anatomy and allow surgeons to rehearse for surgery. This has led to improvements in patient outcomes and satisfaction. The presentation will involve a brief personal history, and will combine photos and videos from current use of anatomy in my practice as a surgeon. I hope this will serve as an inspiration to both those who have mentored me and the next generation of young anatomists.

Dr Louis is the Director of the Skull Base and Pituitary Tumor Program at Hoag Neurosciences Institute in Orange County, California. His expertise includes endoscopic and minimally invasive treatment of benign and malignant brain tumors, sellar and parasellar tumors and skull base tumors. Through the use of cutting-edge neuroimaging and neuro-navigational equipment, he utilizes the concept of keyhole neurosurgery, minimizing the damage to surrounding brain, vascular and soft tissue structures. This approach has been demonstrated to decrease post-operative pain, minimize neurologic complications and shorten the length of hospitalization, resulting in better outcomes for his patients.

Since 2015, Dr Louis has been involved with the development and implementation of Virtual and Augmented Reality technologies for pre-operative simulation and rehearsal and intraoperative navigation. The 3-D VR/AR platform is provided by Surgical Theater and was developed based on flight simulator technology from F-16 fighter jets. This technology allows the surgeons to literally rehearse complicated operations in virtual reality; affording them the opportunity to visualize critical anatomy and navigate potential pitfalls. The results are making the operations safer and more effective for patients. Under his guidance, Hoag Neuroscience Institute has become the highest volume center for Augmented Reality in Neurosurgery in the United States.

Dr Louis heads several projects to expand the applications of Mediated Reality Technology in Neurosciences. These include: virtual reality based meditation to help nurses with workplace related stress and compassion fatigue, virtual reality applications for neuro rehab and VR based therapies for decreasing opiate consumption and addiction. He is also part of the DSR-30, which is working with NASA on preparing the astronauts for the Mars Mission, scheduled in 2030. He has recently spoken as an invited guest lecturer at numerous national and international conferences including Becker's, HIMSS, Congress of Neurological Surgeons and Mount Sinai School of Medicine's symposium on Digital Neurosurgery. His specialty is in coordinating uses of advanced technologies in neurosciences across the patient care continuum. Currently, he is overseeing the widespread implementation of VR and AR across several institutes at Hoag including Neurosciences, Heart and Vascular, Cancer and Women's Health.

Honored Member 2019



The American Association of Clinical Anatomists

Recognizes and Awards Honored Membership to

Robert Anderson, MD, PhD, FRCPath

Robert H. Anderson, known to his friends and colleagues as Bob, was born in the English county of Shropshire, where he received his initial education. Having been accepted to study medicine at the University of Manchester, his initial encounter with anatomy, subsequent to the study as part of the medical curriculum, came when he was offered the opportunity to undertake an intercalated degree. He was fortunate to be allocated the topic of the intrinsic innervation of the heart for his initial research. Having completed his degree in anatomy, he returned to the study of clinical medicine, and qualified in 1966. He then returned to the Department of Anatomy, having completed his clinical residency appointments, ostensibly with the intention of becoming an ophthalmologist. Serendipity then intervened, and he was offered the chance to continue his researches on cardiac innervation, concentrating on the conduction tissues. This led to the award of a Doctorate in Medicine, but more importantly to the chance to collaborate with surgical colleagues in Liverpool, and with electrophysiologists and pathologists in Amsterdam. Having spent a year in Amsterdam, he was then fortunate to be offered the chance to work as clinical anatomist at the Royal Brompton Hospital in London. This appointment was supported by the Joseph Levy Foundation, in collaboration with the British Heart Foundation. The support from both Foundations then continued throughout the remainder of his active career. This was undertaken from 1974 until 1999 at the Royal Brompton, and subsequently, until 2007, at Great Ormond Street Children's Hospital. Throughout these periods, all his studies had been directed towards clinicians, with the aim of stimulating surgical techniques, improving the management of children born with congenital heart defects, and contributing to the understanding of the various fields of diagnosis. On his retirement in 2007, he was made Emeritus Professor at University College, London. Despite the alleged "retirement", he has been fortunate to remain deeply involved in collaborative research ventures. Using episcopic microscopy and molecular biological techniques, he has been able to follow the fate of tissues, and thus to trace the development of the normal, and the maldevelopment of the abnormal, heart. To this end, he has received Professorial Fellowships at the Institute of Genetic Medicine, Newcastle University; and at St George's Medical University in London. He has also been appointed Emeritus Visiting Professor at Manchester University, where he has been able to return to the studies of the conduction tissues in animal hearts. Throughout his active career, he was also deeply involved in educational activities. These have continued subsequent to his alleged retirement, particularly in the United States of America, where he has worked with colleagues at Lurie Children's Hospital in Chicago to produce video teaching programmes. He also participated in teaching sessions organised by his colleague, Andrew Redington, for the Canadian fellows in pediatric cardiology. Andrew, who was initially at the Hospital for Sick Children in Toronto, has now moved to Cincinnati in the United States of America. He is spearheading another programme for fellows in pediatric cardiology. This now results in regular teaching commitments for Bob in Cincinnati, along with similar commitments in Milwaukee, Houston, and Denver. Bob also organises regular Masterclasses in cardiac anatomy in Pittsburgh. Even more recently, he has accepted additional honorary positions in the United Kingdom, specifically at the Wessex Cardiac Center in Southampton, and Birmingham Children's Hospital. He was particularly thrilled, in 2017, to be elected an honorary fellow of the European Congenital Heart Surgeon's Association, and in 2018 to be granted an Honorary Doctorate of Philosophy by the Nova University of Lisbon, Portugal. He is now gratified to be the Honored Member of the American Association of Clinical Anatomists for 2019.

Previous Honored Members of the AACA

*W. Henry Hollinshead, 1984
*Chester B. McVay, 1985
*Donald James Gray, 1986
*Russell T. Woodburne, 1987
*Oliver Beahrs, 1988
*N. Alan Green, 1989
*Frank H. Netter, 1990
*Ralph Ger, 1991
M. Roy Schwartz, 1992
*Carmine D. Clemente, 1993
Keith L. Moore, 1994
*Ray J. Scothorne, 1995
Robert A. Chase, 1996
Tatsuo Sato, 1997
*John E. Skandalakis, 1998
*Donald R. Cahill, 1999
*Sandy C. Marks, Jr., 2000
* David G. Whitlock, 2001
*Robert D. Acland, 2002
Arthur F. Dalley, II, 2003
*John V. Basmajian, 2004
Ian Whitmore, 2005
Peter H. Abrahams, 2006
Gary G. Wind, 2007
Vid Persaud, 2008
Richard S. Snell, 2009
Ray Gasser, 2010
Harold Ellis, 2011
Ronald A. Bergman, 2012
John T. Hansen, 2013
Victor M. Spitzer 2014
Carol E. Scott-Connor 2015
Carlos A. G. Machado 2016
* James D. Collins 2017
Anne Agur 2018

** deceased*

R. Benton Adkins Jr. Distinguished Service Award, 2019



The American Association of Clinical Anatomists

Recognizes and awards the

R. Benton Adkins Jr. Distinguished Service Award to

Brian R. MacPherson, Ph.D

Brian R. MacPherson, Ph.D., is the James and Barbara Holsinger Endowed Professor of Anatomy and Vice-Chair for Educational Programs in the Department of Neuroscience at the University of Kentucky (UK) College of Medicine in Lexington, Kentucky. He has been on faculty at UK since 1991. Brian was educated at the University of Prince Edward Island (1968-71, BS in Biology); and Memorial University of Newfoundland (1971-74; M.Sc. - Biology; 1974-78; Ph.D. - Gastrointestinal Pathophysiology). His first 15 years in academia were spent in the Department of Anatomy and Cell Biology at the University of Alberta, in Edmonton, Alberta (1977-1991). In 1991 he moved to the University of Kentucky as a Special Titles (Teaching) faculty member at the Associate Professor level and was promoted to Professor in 2000. Over his time at UK he has directed histology and anatomy courses for almost every professional student taught by the department. His fields of expertise are histology, oral histology, clinical gross anatomy and embryology. He has been the recipient of numerous teaching awards at many institutional levels. In 2008 he co-authored the Thieme Atlas of Anatomy.

Dr. MacPherson has been a member of the AACA since 1992. He became Program Secretary in 1999, and served in this position until 2005. In 2005 he became Association Secretary, and served in this position until 2011. In 2011 he became President-elect of the Association. He served as President and past president until 2017. He has served on the Council for over 19 years in these various positions and chaired many AACA committees including: Financial Affairs, Program Committee, Nominating, Membership, and the Journal Committee. Over this extended period on Council he worked closely with, among many others, Benton Adkins.

Previous R. Benton Adkins Jr. Distinguished Service Award Recipients

2004 – Robert J. Leonard
2006 – Daniel O. Graney
*2007 – Ralph Ger
2009 – Arthur F. Dalley
2011 – Carol Scott-Conner
2012 – Keith L. Moore
2013 – Stephen W. Carmichael
*2015 - Lawrence M. Ross
2016 – Thomas Quinn
2017 – Ronald S. Wade

** deceased*

Career Development Committee Symposium

Wednesday, June 12th
1:00 PM – 2:30 PM

"Facing the Imposter"

Do you...

- Tend to attribute your accomplishments to "good fortune", "coincidence", or "luck"?
- Worry that other people will find out the "truth" about your abilities?
- Miss out on opportunities because of self-doubt?
- Over-react to minor setbacks?

If you answered yes to any of these questions, please join us at the CDC symposium at AACA!

Since described by Clance and Imes in 1978, "imposter syndrome" has been increasingly diagnosed among undergraduate and newly graduated students, clinical professionals and business managers. The imposter phenomenon is characterized by persistent self-doubt regarding intelligence and ability, fear of failure, and a feeling of guilt about success. Individuals suffering from imposter syndrome may fail to internalize success (despite external recognition), crave perfection, discount praise, and have fraudulent feelings. Academics are particularly vulnerable to imposter tendencies because they are under scrutiny from students, parents, colleagues, administration and accrediting bodies.

Academics experiencing imposter tendencies can suffer from increased level of stress, anxiety and burnout with adverse implications of job satisfaction, belonging and retention. A better understanding of the imposter phenomenon in individuals working in higher education can be helpful in reducing the number of diagnoses.

Dr. Rebecca Pratt, Dr. Sara Sulaiman, and Dr. Peter Ward will explore "imposter syndrome" within academia by drawing from their experiences. The symposium will explore possible triggers that enhance imposter tendencies and suggest coping approaches for both the individual and their institution.

Peter J. Ward, Ph.D.

West Virginia School of Osteopathic Medicine



Bio: Dr. Peter Ward grew up in Casper, Wyoming before moving to Pittsburgh, PA to attend Carnegie Mellon University, graduating in 1996. During graduate school at Purdue University, Dr. Ward served as a teaching assistant in human and veterinary anatomy and embryology, histology, and neuroscience. He was recognized as the department's outstanding teaching assistant, received the Purdue University distinguished teaching assistant award, the Purdue graduate school excellence in teaching award, and was inducted into the Purdue Teaching Academy as an associate fellow. His graduate research focused on how professional students study and how to promote long-term recall of anatomic knowledge.

In 2005, Dr. Ward earned a Ph.D. from Purdue and accepted a position at the West Virginia School of Osteopathic Medicine in Lewisburg, West Virginia. At WVSOM, He has taught gross anatomy, histology, embryology, neuroscience, as well as the history of medicine. Dr. Ward has been the course director for several courses in a traditional and longitudinal medical curriculum. As the chair of the curriculum committee, he was involved in implementing a longitudinal curriculum at WVSOM. He developed a 4th year anatomy elective that allows students to return to the anatomy laboratory and conduct a focused research project. At WVSOM he has received: the Atlas Club Golden Key Award, the Osteopathic Principles and Practices Integration Faculty Teaching Award, and the President's Award of Faculty Excellence. Dr. Ward was also selected as the University of Charleston PA program's adjunct faculty member of the year four times. In 2016, Dr. Ward received the Basmajian award from our sister society, the American Association of Anatomists. In 2017, Dr. Ward had the honor of being selected as one of the five finalists for the West Virginia Professor of the Year.

continued on next page

In addition to service on institutional committees at WVSOM, Dr. Ward has coordinated dissection-based anatomy retreats for faculty and students from Japanese Osteopathic schools, and serves as the director of the WVSOM plastination laboratory. In the AACA, he has served as Association Secretary, at-large council member, committee chair, session moderator, and poster/presentation judge.

Dr. Ward's educational research program uses qualitative and quantitative methods to characterize how student approaches to study affect their achievement and recall of basic science course material. He has been an invited speaker on qualitative research methods in anatomy education research as well as the history of medicine. Dr. Ward has contributed to several texts, including revising the anatomy, histology, embryology, and neuroanatomy content to the 2nd editions of The Netter Collection: The Digestive System, 2nd Ed. He recently began working on a musculoskeletal textbook for use in longitudinally-organized curricula.

Outside of work, Peter enjoys exercise, jujutsu, and reading (mostly non-fiction but a smattering of novels occasionally). He is extremely lucky to be married to Sarah Koressel, D.V.M. and is the father of two amazing twin, (nearly) 6-year-old sons.

Rebecca Lynn Pratt, Ph.D.

Oakland University William Beaumont School of Medicine



Biography: Dr. Rebecca Pratt is currently a Professor of Anatomy at Oakland University William Beaumont School of Medicine (OUWB). She completed her PhD in Cancer Cell Biology from Purdue University in West Lafayette, IN. After a short postdoc, Dr. Pratt accepted the appointment at Grand Valley State University in Allendale, Michigan as the Director for the undergraduate Anatomy and Histology courses and as the Director of the Human Cadaver Laboratories. Dr. Pratt also team-taught Anatomy of Joints, Anatomy for Physical Therapy and Physician Assistants, and Regional Dissection. In the summer of 2006, she accepted a position at the West Virginia School of Osteopathic Medicine (WVSOM). For four years Dr. Pratt held the position of Course Director for Medical Histology and taught as a member of the Medical Gross Anatomy faculty team. Her translational histology research (from coursework to clinical practice) was recognized in 2008 by the American Association of Anatomists (AAA) when she was presented with the Young Faculty Research Award and the Keith Moore Young Anatomist's Publication Award. Later that year Dr. Pratt was acknowledged with the WVSOM Basic Science Osteopathic Integration Teaching Award. In 2010 she was recruited by Michigan State University College of Osteopathic Medicine (MSUCOM) to be the Director of Medical Anatomy Labs for five courses including co-director for the first year COM clinical anatomy course. In 2014 Dr. Pratt was nationally recognized when she was awarded the AAA Basmajian Award for excellence in teaching, scholarly activity and service to the discipline. During her tenure at MSUCOM Dr. Pratt's accepted five Golden Apple Teaching Awards. In January 2018 Dr. Pratt joined the Department of Foundational Studies at OUWB. Her current adventure has her teaching in the medical gross anatomy course and histology labs. She is also the course director for the year two Musculoskeletal System. In her free time, she serves OUWB as the Chair of Promotion and Tenure, the Faculty Liaison to Academic Services, a member of the Admissions Committee and as a member of a multitude of curricular task forces. Last year the NBOME recognized Dr. Pratt for her outstanding contributions to the national osteopathic board examination item writing team. Dr. Pratt's expertise in connective tissue was recently highlighted in an eight-page article on fascia in the December 2018 issue of Women's Health Magazine.

Since 2006, Dr. Pratt as served AACA as a member and Chair of the CDC, EAC and CAT Committees as well as a session moderator, abstract reviewer and presentation judge. She has also held a Councilor-At-Large position on the AACA Board of Directors. Dr. Pratt states that attending the annual AACA conference always feels like a fabulous family reunion with inspirational colleagues.

For fun Dr. Pratt teaches as a visiting professor and performs with the Oakland Symphony Orchestra Chorale.

continued on next page

Sara Sulaiman, Ph.D., MSc, BSc

University of Bristol



Bio: Dr Sara Sulaiman is a Teaching Fellow of Anatomy at the Centre for Applied Anatomy, University of Bristol, UK. Sara is involved in various teaching and training activities running at both the Centre of Applied Anatomy and the Vesalius Clinical Training Unit. She is also the involved in the personal tutor scheme for the BSc Applied Anatomy students and is the Careers Contact for the Centre, supporting the personal and professional development of students enrolled at the Applied Anatomy degree. She is also involved in the Centre's outreach activities which aim to stimulate interest in science and deliver an exceptional anatomy experience to the general public.

After obtaining a degree in Biomedical Sciences from the University of Qatar in 2006, Sara took a position as a Lecturer for the College of Health Sciences, Kingdom of Bahrain. Alongside her colleagues, she was involved in the delivery, design and modifications of various courses at the Biomedical Sciences Department including Human Anatomy and Physiology, Human Biology and Histology to Nursing and Allied Health students. Sara also worked as a part-time-counsellor where she was involved in the development, implementation and evaluation of counselling and guidance plans to Allied Health students.

Sara moved to the Scottish city "Dundee" in 2010 to peruse a degree in Human Anatomy. At the same time, as an anatomy demonstrator, she supported the delivery of dissection-based anatomy practical sessions for Medical and Science students. She also assisted in the preparation of anatomical prosections from formalin and Theil embalmed cadavers. After graduating from Dundee University with a PhD degree in Human Anatomy in 2014, Sara took a position as a Lecturer in Anatomy at Northumbria University, UK. She contributed to the teaching and delivery of various modules in the department of Applied Sciences, as well as the Keith B. Taylor Global Scholars Program of St. George's International School of Medicine. Further to her teaching role, Sara was an active member of NUwise group, a network established to support and develop the careers of female staff and PhD students working in science, engineering and technology areas at Northumbria University. She also took the role of Athena Swann Departmental representative where she continued to champion initiatives addressing gender inequality in STEMM. Alongside her colleagues, she designed and led a successful ultrasound research selective that aimed to introduce medical students to the research cycle furthering their anatomical knowledge and ultrasound scanning skills through research.

Sara is generally interested in human anatomical variations and their clinical significance. Her research involved utilizing different methods including physical examination and ultrasound imaging to collect and analyse data. She is also interested in exploring the efficiency of the various teaching tools used in the modern anatomy curricula. Sara is a Fellow of the Higher Education Authority, UK and a member of the British (BACA) and the American (AACA) Associations of Clinical Anatomists and the Anatomical Society (Anat. Soc.), UK.

Notes:

Invited Speaker #1

Thursday, June 13th
9:15 – 9:55 AM

"Neural Highways and Peripheral Nerve Tumors"



Over the past two decades, our group has tried to provide anatomic (neural) explanations to explain curious features of benign and malignant peripheral nerve tumors. Discovering clinical and radiological patterns has led to an understanding of the pathologic process, which has treatment implications. In this talk, I will summarize recent advances related to intraneural ganglion cysts, hamartomas/ choristomas of nerve (and nerve-territory growth) and perineural spread of malignancy.

Robert J. Spinner, M.D., FAANS, FACS is chair of the Department of Neurologic Surgery at Mayo Clinic in Rochester, Minnesota. He is the Burton M. Onofrio, MD Professor of Neurologic Surgery and a Professor of Orthopedics and Anatomy. He is chair of the Academic Appointments and Promotions Committee at Mayo Clinic College of Medicine and Science. He is board certified in both orthopedics and neurosurgery. His clinical practice is limited to peripheral nerve surgery. He completed full residency programs in orthopedics (Duke University) and neurosurgery (Mayo Graduate School of Medicine); a 1 year peripheral nerve fellowship with Dr. David Kline at Louisiana State University Health Sciences Center in New Orleans; and a 6 month traveling fellowship to several international centers as a CNS (Congress of Neurological Surgeons) Cushing Fellow. He has served as President of the American Society for Peripheral Nerve, the Sunderland Society (an international peripheral nerve study group), and the Peripheral Nerve Section of the CNS Joint Sections of Spine/Peripheral Nerve. He has published more than 500 peer reviewed papers and 90 chapters and has given >1000 presentations.

Notes:

Invited Speaker #2

Thursday, June 13th
9:55 – 10:30 AM

"The Impact of Clinical Anatomy on Translational and Reverse Translational Research"



Anatomical sciences and specifically gross anatomy are key components of medical knowledge. Although gross anatomy is important, research in this field has proven difficult to bridge the gap between study findings and actual patient care. As a result, introducing the concept of translational research is important for maintaining the relevance of anatomy in medical curricula and at the same time understanding the best ways of improving patient care. This talk will provide concrete examples of published studies using gross anatomy as the basis for conducting translational research and its impact on patient care. Furthermore, the talk will provide an overview of clinical anatomy research, bridging the gap between medical need and anatomical studies, designing studies related to clinical anatomy and reverse translational research. Finally, it will provide examples of future projects of anatomical feasibility studies and potential directions for new studies.

Marios Loukas, MD, PhD, received his medical degree from Warsaw University School of Medicine, and a PhD from the Institute of Rheumatology at the Department of Pathology in Warsaw, Poland. He held a postdoctoral position at Ulm Uni¬versity Clinic in Germany and studied arteriogenesis. Dr. Loukas began his academic career at Harvard Medical School, where he served as lecturer and laboratory instructor for the Human Body Course. In 2005, he joined St. George's University in Grenada and shortly after became Professor and Chair of the Department of Anatomical Sciences. Under his leadership, the Department of Anatomical Sciences devel¬oped a unique division of Ultrasound in Medical Education that instructs faculty members in how to teach the use and interpretation of ultrasound to medical students and resi¬dents and how to provide effective continuing medical edu-cation (CME) courses. In 2012, Dr. Loukas was appointed Dean of Research for the School of Medicine at St. George's University. One of his main responsibilities is to develop a transdisciplinary research infrastructure to support translational research and to bridge basic science and clinical departments with the aim of enhancing student research.

Dr. Loukas has published several papers in peer-reviewed journals and several books, including *Gray's Anatomy Review, Gray's Clinical Photographic Dissector of the Human Body, McMinn and Abrahams' Clinical Atlas of Human Anatomy, Bergman's Comprehensive Textbook of Human Variation and Essential Ultrasound.* He has authored several chapters in various medical and surgical textbooks, including *Gray's Anatomy.* He is Co-Editor of the journal *Clinical Anatomy* and the Editor-in-Chief of the journal *Translational Research in Anatomy.* With this background, Dr. Loukas has been able to provide his medical knowledge in the anatomical sciences to a larger audience and in 2015 was elected President of the American Association of Clinical Anatomists. His scientific interests include surgical anatomy and techniques and cardiovascu¬lar pathology. In past of couple of years, his focus has been directed toward issues of integrated curriculum and faculty development in medical education with an emphasis on simulation and tech¬nology and effective teaching and assessment. In February of 2015, Dr. Loukas was named Dean of Basic Sciences at St. George's University School of Medicine.

Notes:

Clinical Anatomical Terminology Committee Symposium

Thursday, June 13th
1:00 PM – 2:30 PM

"The Clinical Anatomical Terminology Conundrum"

1. The CAT committee would like to invite AACA members to join our Symposium speaker, Dr Scott. Dr. Scott is an Emergency Medicine physician, best known for founding: Boston Medical Publishing; eMedicine/WebMD, Pearlsreview, and StatPearls!
2. Dr. Scott will be talking about the importance of communication between clinicians and anatomists and the role of a common language. He will also discuss the role of Anatomist Editors in StatPearls.
3. Following Dr. Scott's presentation we will host a workshop where participants will take a critical look at a clinical manuscript to evaluate the anatomical/medical terminologies used.

Bio: **Dr. Scott**

- Summa Cum laude with Honors, Creighton University
- Alpha omega alpha, University of Nebraska Medical Center
- Residency in emergency medicine and board certified by the American Board of Emergency Medicine
- Retired associated professor, University of Louisville.
- Author of over 30 medical textbooks, served as editor-in-chief of over 100 medical textbooks, has written over: 200 textbook chapters and articles
- Founder of: Boston Medical Publishing, which published 68 board review books for physicians and nurse; eMedicine/WebMD, a free medical library containing 8,000 peer reviewed articles used by over 6 million health professionals worldwide; Pearlsreview, a collection of 2,500 continuing education articles used by over 1 million health professionals, and founder of StatPearls, a new free learning education system consisting of Pubmed indexed article and questions.
- Founded and served as Vice President of the American Academy of Emergency Medicine, which is an academy of board certified emergency physicians dedicated to improving the quality of emergency care in the United States.
- Responsible for the Bonono/Plantz Act, now passed in several states, which allows health care reporting of intoxicated drivers.

Notes:

Poster Listings

Poster Session 1 – Wednesday, June 12, 2:45 PM – 4:00 PM

*Denotes publication in *Clinical Anatomy.*

Poster # Abstract Title/Authors

004* Macroscopic and Histological Examination of the Myocardium Architecture in the Human Right Atrium.
ARAKAWA, Takamitsu. Department of Rehabilitation Sciences, Kobe University Graduate School of Health Sciences, Kobe, Hyogo, 654-0142, Japan.

008* Situs Inversus Totalis in a Female Donor Who Died at 55 Years: Case Report and Literature Review.
BAIDYA, Ritwik, Sushil KUMAR, Anthony V. D'ANTONI, Santosh SANGARI, and Estomih P. MTUI[1]. Division of Anatomy, Department of Radiology, Weill Cornell Medicine, New York, NY 10065, USA.

011* Repositioned Common Hepatic Artery with Very Rare Anterior Portal Vein.
CASTELLANOS, Bedia, Naveen Babu KANDAVALLI, Sushama RICH, Ramona BAEZ, and Carlos QUINTEROS. Department of Anatomy, Touro College of Osteopathic Medicine, New York, NY, 10027, USA.

012* Do Functional Pairs of Extraocular Muscles Have Similar Excursion and Force Generating Capabilities?
CASTANOV, Valera, Maxine D. VIENNEAU, and Anne M. R. AGUR. Division of Anatomy, Department of Surgery, University of Toronto, Toronto, ON, M5S 1A8, Canada. **MARKS - CLINICAL ANATOMY**

014 Rare Anatomical Variation of the Psoas Minor Muscle and a Review of Its Variants.
COLBURN, Tatum B., Zakary ROSE-RENEAU, Karen TONG, and Anthony OLINGER. Department of Anatomy, Kansas City University of Medicine and Biosciences, Kansas City, MO, 64106, USA.

017* Anatomical Study of Celiac Trunk Angle and Its Association with Median Arcuate Ligament Syndrome.
DYCHES, Ryan[1] and Heather F. SMITH[2,3]. [1]Department of Osteopathic Manipulative Medicine, Arizona College of Osteopathic Medicine, Midwestern University, Glendale, AZ, 85308, USA; [2]Department of Anatomy, Arizona College of Osteopathic Medicine, Midwestern University, Glendale, AZ, 85308, USA; [3]School of Human Evolution and Social Change, Arizona State University, Tempe, AZ, 85287, USA. **MARKS - CLINICAL ANATOMY**

020* Identification of Tissue Factor as a Potential Biomarker for Early Detection of Ovarian Cancer.
FLANNERY, Meghan M.[1], Emily L. DURHAM[1,2], Kalpana Deepa Priya DORAYAPPAN[3], Eileen L. KALMAR[1], Michelle D.S. LIGHTFOOT[3], Michael F. TWEEDLE[4], and Karuppaiyah SELVENDIRAN[3]. [1]Department of Biomedical Education and Anatomy, College of Medicine, The Ohio State University, Columbus, OH, 43210, USA; [2]Oral Health Sciences, Medical University of South Carolina, Charleston, SC, 29425, USA; [3]Department of Obstetrics and Gynecology, College of Medicine, The Ohio State University, Columbus, OH, 43210, USA; [4]Department of Radiology, College of Medicine, The Ohio State University, Columbus, OH, 43210, USA. **MARKS - BASIC SCIENCE**

023* A Unilateral Pelvic Kidney with Variant Vasculature: A Case Report.
GENCHEVA, Ralitsa, Bryce GIBSON, Anthony FORREST, Shruthi GARUGU, and Sumathilatha SAKTHI-VELAVAN. Department of Biomedical Sciences, Marian University College of Osteopathic Medicine, Indianapolis, IN, 46222, USA. **MARKS - CLINICAL ANATOMY**

026* Anatomic Variation of Short Gastric Artery in Relationship to Splenic Blood Supply.
ISMAILOV, Eugene L., James Y. YANG, Andrew S. LANGILLE, Seth J. LARSEN, and Sarah A. KEIM. Department of Anatomy, College of Medicine, Kansas City University, Kansas City, MO, 64106, USA. **MARKS - CLINICAL ANATOMY**

029* Retro-External Iliac Megaureter with Extrarenal Calyces and Associated Arterial Anomalies.
KARADAGHY, Amin A., Matthew J. BELL, Evan S. QU, Daniel T. DALY and Yun TAN. Center for Anatomical Science and Education, Department of Surgery, School of Medicine, Saint Louis University, St. Louis, MO, 63104, USA.

continued on next page

Poster Session 1

035* The Master Knot of Henry: A Dynamic Role in Heel and Foot Pain?
LOZANO, J. Antonio, and W. Allan BESSELINK. The University of St. Augustine for Health Sciences, Austin, TX, 78739, USA.

038* Role of the Abdominal Musculature in Core Stability: A Novel 3D Anatomical and Biomechanical Study.
PENG, Michael, Kathleen CHENG, Joshua WONG, Erin BOYNTON, and Anne M.R. AGUR. Division of Anatomy, Department of Surgery, University of Toronto, Toronto, ON, M5S 1A8, Canada. **MARKS - BASIC SCIENCE**

041* Incidence of Abnormal Obturator Artery in the Maritime Population.
PULAKUNTA, Thejodhar, Akram JAFFER, and Rob SANDESKI. Department of Medical Neuroscience, Dalhousie University, Halifax, NS, B3H 4R2, Canada.

044* Aberrant Testicular Artery.
QUINTEROS, Carlos I., Steve A. ORELLANA, Haley A. MEGARITY, Varsha VENKAT, Bryan A. LEBRON, Young PARK, Samiyyah TILLMAN, Alessia ZAMBRANO, John CHOI, Bedia CASTELLANOS, and Reine Y. SINTHIA. Touro College of Osteopathic Medicine, New York, NY, 10027. USA.

047* Could a Large Umbilical Hernia Be Associated with a Connective Tissue Disease?
RUTLAND, Marsha D., Chris R. GRAVES, Amanda R. RICHTER, Mary E. SAMMANN, and Aaron W. WALLING. Department of Physical Therapy, Hardin-Simmons University, Abilene, TX, 79698, USA.

050 Description and Comparison of Bilateral Variations of the Soleus Accessorius Muscle in a Cadaver.
SNYDER, Steven G.[1] Mathew WEDEL[2], and Jacqueline B. TRUONG[3]. [1]Department of Physical Therapy, Western University of Health Sciences, Pomona, CA, 91766, USA. [2]College of Osteopathic Medicine of the Pacific, Western University of Health Sciences, Pomona, CA, 91766, USA. [3]College of Podiatric Medicine, Western University of Health Sciences, Pomona, CA, 91766, USA.

053* Thrombotic Events in Pulmonary Artery Conduits.
TORRES, Cristian and Darren SALMI. Division of Clinical Anatomy, Department of Surgery, School of Medicine, Stanford University, Stanford, CA 94305, USA. **MARKS - CLINICAL ANATOMY**

056* The Active Formation of a Cholecystogastric Fistula Secondary to Calculous Cholecystitis.
VAN, Lang[1], Anthony HANG[1], Shireen SACHDEVA[1], and Mark MILLER[2]. [1]Lincoln Memorial University, Harrogate, TN, 37752, USA; [2]Department of Surgery, Methodist University Hospital, Memphis, TN, 38104, USA. **MARKS - CLINICAL ANATOMY**

057* Amyand Hernia Complicated by Appendicitis and Necrotizing Fasciitis.
VAN, Lang[1], Hau LY[1], Suma NADIMPALLI[1], Jessica CANLAS[1], Cassandra ROBERTSON1, and Mark MILLER[2]. [1]Lincoln Memorial University, Harrogate, TN, 37752, USA; [2]Department of Surgery, Methodist University Hospital, Memphis, TN, 38104, USA. **MARKS - CLINICAL ANATOMY**

060* Frequency and Variation of the Iliocapsularis Muscle.
YARNELL, Jocilyn R., Allison L. PICKRON, and Philip A. FABRIZIO. Department of Physical Therapy, Philadelphia College of Osteopathic Medicine-Georgia, Suwanee, GA, 30024, USA. **MARKS - CLINICAL ANATOMY**

continued on next page

Poster Session 2 – Thursday, June 13, 10:30 AM – 11:45 AM

*Denotes publication in *Clinical Anatomy*

002* Anatomical Variations of the Hypoglossal Nerve, the Vagus Nerve, and the C1 and C2 Ventral Rami.
AVILA, Jessica A.[1], Johan S. VALCARCEL[2], and Thomas R. GEST[3]. [1]Paul L. Foster School of Medicine, Texas Tech University Health Sciences Center El Paso, El Paso, TX, 79905, USA; [2]University of Texas at El Paso, El Paso, TX, 79968, USA; [3]College of Medicine, Central Michigan University, Mount Pleasant, MI, 48859, USA. **MARKS - CLINICAL ANATOMY**

005* Unusual Bilateral Accessory Flexor Digiti Minimi Brevis Muscle.
BAEZ, Ramona[1], Bedia CASTELLANOS[1], and Eric BAKER[2]. [1]Department of Anatomy, Touro College of Osteopathic Medicine, New York, NY, 10027, USA. [2]Department of Basic Science and Craniofacial Biology, College of Dentistry, New York University, New York, NY, 10010. USA.

006* Aberrant Formation and Communication to the Median Nerve and Unusual Subscapular Artery Branching.
BAEZ, Ramona, Lizbeth L. ZAMBRANO, and Aura M. AMOROS. Department of Anatomy, Touro College of Osteopathic Medicine, New York, NY, 10027, USA.

015* Triangular Fibrocartilage Complex: An Anatomical, Radiological and Medical Illustration Study.
D'ANTONI, Anthony V.[1], Carlos A. G. MACHADO[2], Jimmy XIA[1], R. Shane TUBBS[3,4], Marios LOUKAS[4], Douglas N. MINTZ[5], Sushil KUMAR[1], Ritwik BAIDYA[1], Santosh K. SANGARI[1], and Estomih P. MTUI[1]. [1]Division of Anatomy, Department of Radiology, Weill Cornell Medicine, New York, NY, 10065, USA; [2]Medical Illustrator, Austin, TX, 78759, USA; [3]Seattle Science Foundation, Seattle, WA, 98122, USA; [4]Department of Anatomical Sciences, St. George's University, Grenada; [5]Department of Radiology and Imaging, Hospital for Special Surgery, New York, NY, 10021, USA.

018* Multiple Bilateral Variations in Lumbricals, FDS and FDP: Could this Affect Hand Function?
DOWNIE, Sherry A.[1,2], Carly R. BASS[1], Sharon J. GALPERIN[1], Samir ZAMAN[1], Fernando S. GONZALEZ[1], and Priti L. MISHALL[1,3]. [1]Department of Anatomy and Structural Biology, Albert Einstein College of Medicine, Bronx, NY, 10461, USA; [2]Department of Physical Medicine and Rehabilitation, Albert Einstein College of Medicine, Bronx, NY, 10461, USA; [3]Department of Ophthalmology and Visual Sciences, Albert Einstein College of Medicine, Bronx, NY, 10461, USA.

021* Diffuse Idiopathic Skeletal Hyperostosis (DISH) in the Cervical Vertebrae Vertebral Bodies (C3-C7).
EZRA, David[1], Lyman JELLEMA[2], Yelena STUKALIN[3], and Viviane SLON[4]. [1]School of Nursing Science, Tel Aviv Jaffo Academic College, 6818211, Israel. [2]Department of Physical Anthropology Natural History Museum, Cleveland, Ohio, 44106, United States. [3]Statistics Education Unit, Tel Aviv Jaffo Academic College, 6818211, Israel. [4]Department of Anatomy and Anthropology, Sackler Faculty of Medicine, Tel-Aviv University, Tel Aviv, 69978, Israel.

024* Case Report: Anatomical Abnormalities seen in the Epiglottis of a Cystic Fibrosis Patient.
HALES, Hannah, Tiffany CHAMBERS, Sara MICHIE, and Darren SALMI. Department of Surgery, School of Medicine, Stanford University, CA, 94305, USA. **MARKS - CLINICAL ANATOMY**

027* Intramuscular Aponeuroses and Fibre Bundle Morphology of Flexor Digitorum Superficialis: A 3D Study.
JOHNSTON, Mai-Lan, Ellis KELLY, Zhi LI, Nancy McKEE, and Anne M.R. AGUR. Division of Anatomy, Department of Surgery, University of Toronto, Toronto, ON, M5S 1A8, Canada. **MARKS - CLINICAL ANATOMY**

030* Variations of Vertebral Artery and Suboccipital Artery of Salmon: Hypothesis-Generated Case Report.
KUMAR, Sushil[1], Ritwik BAIDYA[1], Anthony V. D'ANTONI[1], Santosh K. SANGARI[1], and Estomih P. MTUI[1]. [1]Division of Anatomy, Department of Radiology, Weill Cornell Medicine, New York, NY, 10065, USA.

033* Unusual Accessory Abductor Pollicis Longus Muscle.
LEBRON, Bryan, Steven ORELLANA, Daniel MILLER, Ezra PLEETER, and Ramona BAEZ. Touro College of Osteopathic Medicine, New York, NY, 10027, USA. **MARKS - CLINICAL ANATOMY**

036 The Cranial Nerve Zero (CN0) and Kallmann Syndrome (KS).
LOPEZ-OJEDA, Wilfredo. Department of Foundational Science, Kaiser Permanente School of Medicine, Pasadena, CA, 91101, USA.

continued on next page

Poster Session 2

039* Lipomatosis of Nerve and Nerve-territory Overgrowth.
MAREK, Tomas[1], Mark A. MAHAN[2], Kimberly K. AMRAMI[3], and Robert J. SPINNER[1]. [1]Department of Neurologic Surgery, Mayo Clinic, Rochester, MN, 55905, USA. [2]Department of Neurologic Surgery, University of Utah, Salt Lake City, Utah 84132, USA. [3]Department of Radiology, Mayo Clinic, Rochester, MN 55905, USA.

042 Posterior Auricular Muscle - A Morphometric Analysis.
MILLARD, Jonathan A., Aaron W. BEGER, and Jalen HAMMONDS. Department of Anatomy, DeBusk College of Osteopathic Medicine, Lincoln Memorial University, Harrogate, TN, 37752, USA.

045* Pointing in a Different Direction: A Case of Bilateral Absence of Extensor Indices.
MISHALL, Priti L.[1,2], Anthony MA[1], Carolyn E. MILLER[1], Taylor L. MUSTAPICH[1], Jerryl P. ABRAHAM[1], Jinsung KIM[1] and Sherry A. DOWNIE[1,3]. [1]Department of Anatomy and Structural Biology, Albert Einstein College of Medicine, Bronx, NY, 10461, USA; [2]Department of Ophthalmology and Visual Sciences, Albert Einstein College of Medicine, Bronx, NY, 10461, USA; [3]Department of Physical Medicine and Rehabilitation, Albert Einstein College of Medicine, Bronx, NY, 10461, USA.

048* Landmark Identification & Compartment Decompression in Performance of Upper Extremity Fasciotomy.
PUGH, Kristy R., Lorreen A. AGANDI, Samuel A. TISHERMAN, and Adam C. PUCHE. University of Maryland School of Medicine, Baltimore, MD, 21201, USA.

051* Aberrant Branching of Axillary Artery and Median Nerve, and Accessory Flexor Pollicis Longus Muscle.
REITHERMAN, Danielle E., Jill SCHULDT, Anthony M. IUSO, and Ramona BAEZ. Touro College of Osteopathic Medicine, New York City, NY, 10027, USA. **MARKS - EDUCATIONAL RESEARCH**

054* Anatomic and Histologic Investigations of Brachial Plexus Variations.
ROSENOW, Mica J., and Alla G. BARRY. Department of Biology, Missouri Southern State University, Joplin, MO, 64801, USA. **MARKS - CLINICAL ANATOMY**

058* High-Origin Radial Artery Arising from the Thoracoacromial Artery.
RUTYNA, Jessica, Bedia CASTELLANOS, Naveen Babu KANDAVALLI, Poonit MEHTA, Peter NELSON, Samantha OKUNDIA, Dominique PEAN, Ethan YOUSSEFZADEH, Taylor CHARTER, and Ashley COVATTO. Department of Anatomy, Touro College of Osteopathic Medicine, New York, NY, 10027, USA. **MARKS - BASIC SCIENCE**

061* Spatial Relations of the Lingual, Facial, and Occipital Arteries with the Submandibular Triangle.
SAKAMOTO, Yujiro. Graduate School of Medical and Dental Sciences, Tokyo Medical and Dental University, Tokyo, 113-8549, Japan.

063* Quantitative Measurements of Cadaveric Atlas and Axis Vertebrae as Guidelines for Screw Fixation.
SANGARI, Santosh K.[1], Sven WALDERICH[2], Alexandru BARBULESCU[2], Sushil KUMAR[1], Ritwik BAIDYA[1], Anthony V. D'ANTONI[1], Estomih P. MTUI[1], and Roger HARTL[3]. [1]Division of Anatomy, Department of Radiology, Weill Cornell Medicine, NY 10065, USA; [2]Weill Cornell Medical College, NY 10065, USA; [3]Brain and Spine Center, New York-Presbyterian Hospital, Weill Cornell Medicine, NY 10065, USA.

065* Association of a Specific Genetic Factor with Late-Onset Alzheimer's Disease: A Cadaveric Study.
SHARMA, Pranav, Crystal R. LEMMONS, Narinder SHARMA, and Alla G. BARRY. Missouri Southern State University, Joplin, MO, 64801, USA. **MARKS - CLINICAL ANATOMY**

067* Transverse Carpal Ligament and Carpal Tunnel Morphological Analysis: A Cadaveric Study.
TONG, Karen, Angela WANG-SELFRIDGE, Tatum B. COLBURN, and Anthony OLINGER. Division of Anatomy, Kansas City University of Medicine and Biosciences, Kansas City, MO, 64106, USA. **MARKS - CLINICAL ANATOMY**

069 Internal Morphology of the Odontoid Process: Application to C2 Fractures.
WAHL, Lauren E.[1], Skyler JENKINS[1], Stephen BORDES[1], Islam ALY[1], Shiveindra JEYAMOHAN[1], Basem ISHAK[1], Joe IWANAGA[1], Marios LOUKAS[2], and R. Shane TUBBS[1]. [1]Seattle Science Foundation, Seattle, WA, 98122, United States; [2]Department of Anatomical Sciences, St. George's University, Grenada.

continued on next page

Poster Session 2

071* Anatomical Findings of Retaining Ligaments and Septum in the Deep Fat Compartment of the Cheek.
WATANABE, Koichi[1], Kouji HAYAKAWA[2], Joe IWANAGA[3], Yoko TABIRA[1], Tsuyoshi SAGA[1], and Koh-ichi YAMAKI[1]. [1]Division of Gross and Clinical Anatomy, Department of Anatomy, Kurume University School of Medicine, Kurume, Fukuoka, 815-0034, Japan; [2]Hakusan Clinic, Oita, Oita, 870-0021, Japan; [3]Seattle Science Foundation, Seattle, WA, 98122, USA.

073* A Case of Unilateral Atrophied Right Sternocleidomastoid with Two Separate Bellies.
YAKOOB, Nadha F., Bedia CASTELLANOS, and Naveen Babu KANDAVALLI. Touro College of Osteopathic Medicine, New York, NY, 10027, USA. **MARKS - CLINICAL ANATOMY**

Poster Session 3 – Friday, June 14, 9:15 – 10:30 AM

*Denotes publication in *Clinical Anatomy*

003* Examining the Motivation of Health Profession Students to Study Human Anatomy.
ABDEL MEGUID, Eiman M.[1], Claire F. SMITH[2], and Amanda J. MEYER[3]. [1]Centre for Biomedical Sciences Education, Queen's University Belfast, Belfast, BT9 1BL, UK; [2]Anatomy Department, Brighton and Sussex Medical School, University of Sussex, Brighton, BN1 9PX, UK; [3]School of Human Sciences, The University of Western Australia, 6009, Perth, Australia.

010* Human Cadaver Maintenance Techniques.
BISHOP, Keith N., Caroline POAGE, and Angela HUMPERT. Doctor of Physical Therapy Program, Murphy Deming College of Health Sciences, Mary Baldwin University, Fishersville, VA, 22939, USA.

013* Soft-Embalming Solidification Procedures to Maximize Student Learning Outcomes in Anatomy.
Boaz, Noel T [1,2], Caroline Abercrombie[3], Joy Y. Balta[4,7], Robert Becker[3], Raymond Bernor [2,5], Tony Clary[1], Craig Goodmurphy[6], John Graham[1], Eileen L. Kalmar[7], Thomas Kwasigroch[3], Jon KrimsieR[6], Carrie Robinson[1], Dana Sikon[8], Richard Sikon[9], Breezy Wasko[9], and Michael Wessels[10]. [1]Emory and Henry College School of Health Sciences, Marion, VA 24354, USA; [2]Laboratory of Biological Anthropology and Anatomy, Integrative Centers for Science and Medicine, Martinsville, VA 24112, USA; [3]Department of Biomedical Sciences, Quillen College of Medicine, East Tennessee State University, Johnson City, TN 37614, USA; [4]Department of Anatomy and Neuroscience, University College Cork, Cork T12 K8AF, Ireland; [5]Department of Anatomy, Howard University College of Medicine, Washington, DC 20059, USA; [6]Department of Pathology and Anatomy, Eastern Virginia Medical School, Norfolk, VA 23506, USA; [7]Department of Biomedical Education and Anatomy, The Ohio State University, Columbus, OH 43210, USA; [8]Surgical Skills Training Center, University of Virginia School of Medicine, Charlottesville, VA 22908, USA; [9]Virginia State Anatomical Program, Richmond, VA 23429, USA; [10]Trinity Fluids, Lapeer, MI 48446, USA.

016* Collaboration with Non-Profit to Increase Anatomical Donation within Korean-American Community.
BROOKS, H. Mark, Kristina K. BENSON, and S. Michael DHUY. Willed Body Program, School of Medcine, University of California at Irvine, Irvine, CA, 92697, USA.

019* Gross Anatomy Capstone Projects: Integrating Basic Sciences, Medicine, and Humanities.
CONLEY, David M.[1], and Zachary R. GALLAHER[2]. [1]Department of Medical Education and Clinical Sciences, Elson S. Floyd College of Medicine, Washington State University, Spokane, WA, 99210, USA; [2]Department of Biological Structure, University of Washington School of Medicine, Spokane, WA, 99258, USA.

022 Should the General Public have Access to Cadaveric Dissection Images and Videos on Social Media?
DUPONT, Graham C.[1], Rabjot RAI[1], Matthew PROTAS[1], Katherine BROOKS[1], Joe IWANAGA[1], Marios LOUKAS[2], and R. Shane TUBBS[1]. [1]Seattle Science Foundation, Seattle, WA, 98122, USA; [2]Department of Anatomical Sciences, St. George's University, St. George's, Grenada, West Indies.

025* Creation of Student Self-Assessment Moments (SAMs).
EDWARDS, Emily S. and Kyle E. RAREY. Department of Anatomy and Cell Biology, College of Medicine, University of Florida, Gainesville, FL, 32610, USA. **MARKS - EDUCATIONAL RESEARCH**

continued on next page

Poster Session 3

028* Sharing Personal Information About Anatomical Body Donors: What Do the Students Think?
GREENE, Sarah J. [1], and Lee ROSEN [2], [3]. [1]Department of Pathology and Anatomy, Morehouse School of Medicine, Atlanta, GA, USA; [2]Department of Psychiatry, Larner College of Medicine at the University of Vermont, Burlington, VT, USA; [3]Department of Psychological Science, University of Vermont, Burlington, VT, USA.

031* Comparison of Three Embalming Solutions to Fresh Tissue: Directed at Undergraduate Anatomy Courses.
HAWKINS, Camryn T., Melissa M. QUINN, and Eileen L. KALMAR. Division of Anatomy, Department of Biomedical Education & Anatomy, The Ohio State University, Columbus, OH, 43210, USA. **MARKS - EDUCATIONAL RESEARCH**

034* Tracking and Analyzing Laboratory Dissection Progress Using a Transactional Database System.
HISLEY, Kenneth B.[1], Beddhu MURALI[2], David J. ELIOT[3], Kamal A. ABOUZAID[1], Jennifer L. HOTZMAN[1], Douglas R. TRIGG[1], and Anirudh PULASANI[2]. [1]William Carey University College of Osteopathic Medicine, Hattiesburg, MS, 39401, USA; [2]University of Southern Mississippi, Hattiesburg, MS, 39401, USA; [3]Touro University California, Vallejo, CA, 94592, USA.

037* First-Year Medical Students' Perceptions of a Peer-Directed Simulated Anatomy Lab Practical System.
MCWHORTER, David L., Zachary T. PIERCE, Chris W. FLEMING, Julia R. HAFFNER, Emily L. HUDSPETH, Seth E. BAYIRD, and Jonathan M. HUNTER. Arkansas College of Osteopathic Medicine, Fort Smith, AR, 72916, USA. **MARKS - EDUCATIONAL RESEARCH**

040* Anatomical Donor Luncheon: A Transformational Experience for Medical Students.
HUNTER, Shelley D., Daniel O. DONOGHUE, and Nancy HALLIDAY. Department of Cell Biology, University of Oklahoma Health Sciences Center, Oklahoma City, OK, 73104, USA. **MARKS - EDUCATIONAL RESEARCH**

043* Are Soft-Embalmed Cadavers Better for Histopathological Study?
JACKMAN, Trent D.[1], Sara GRANT[1], Brandon METCALF[1], Stefani ATTARDI[2], Ann MARIE-BLENC[3], and Malli BARREMKALA[2]. [1]1MS2, Oakland University William Beaumont School of Medicine, Rochester, MI, 48309, USA; [2]Department of Foundational Medical Studies, OUWB, Rochester, MI, 48309, USA; [3]Department of Pathology, Beaumont Health System, Royal Oak, MI, 48073, USA. **MARKS - BASIC SCIENCE**

046 Teaching Radiological Anatomy with a Technology-enhanced Workshop and Online Collaborative Learning.
JOHANSEN, Krista S[1], Ellie GLASGOW[2], and Leslie SCHNEIDER[3]. [1]Department of Medical Education, Tufts University School of Medicine, Boston, MA, 02111, USA. [2]Public Health Professional Degree Programs, Tufts University School of Medicine, Boston, MA, 02111, USA. [3]Center for Translational Science Education, Tufts University, Boston, MA, 02111, USA.

049* Etiology of Pseudoconclusion: Phenomenon of Pseudoreplication in Anatomical Research.
JOHNSON, Christopher G., Whitney A. BLODGETT, David A. PENNING, and Alla G. BARRY. Department of Biology and Environmental Health, Missouri Southern State University, Joplin, MO, 64801, USA. **MARKS - EDUCATIONAL RESEARCH**

055* Perception versus Performance: Discrepancies in Students' Perceived and Actual Retention of Anatomy.
MEYER, Edgar R.[1], Amber M. JAMES[1], Allan SINNING[1], Kenneth THOMPSON[2], and Dongmei CUI[1]. [1]Clinical Anatomy Division, University of Mississippi Medical Center, Jackson, MS, 39216, USA. [2]Office of the Registrar and Office of Institutional Research, Millsaps College, Jackson, MS, 39210, USA. **MARKS - EDUCATIONAL RESEARCH**

059* Case-Based Anatomy Review: Comparison of Cadaver versus Computer Based.
MOON, Mary[1],[2], Daniel O'DONOGHUE[2], Kathryn KLUMP[2], and Nancy HALLIDAY[2]. [1]ILAC Department, College of Education, University of Oklahoma, Norman, OK 73019; [2]Department of Cell Biology, University of Oklahoma Health Sciences Center, Oklahoma City, OK, 73104. **MARKS - EDUCATIONAL RESEARCH**

062 Spatial Visualization of Human Anatomy through Art.
NA, Youjin[1], Derek W. CLARY[2], Zakary ROSE-RENEAU[2], Philip BRAUER[1], Barth WRIGHT[2], Andrea HANSON[2], and Sarah KEIM[2]. [1]Kansas City University of Medicine and Biosciences Farber-McIntire Campus, Joplin, MO, 64804, USA; [2]Kansas City University of Medicine and Biosciences, Kansas City, MO, 64106, USA.

continued on next page

Poster Session 3

064* Maintaining an Anatomical Museum: Experiences Choosing Materials for Specimen Containers.
NG, Ricky, Ian BELL, Cindi MORSHEAD, and Anne AGUR. Division of Anatomy, Department of Surgery, University of Toronto, Toronto, ON, M5S 1A8, Canada. **MARKS - EDUCATIONAL RESEARCH**

066* The Effect of an Anatomy Prep Course on OMS-1 Student's Performance During the Fall Semester.
PETERSON, Joanne L., Paulina K. BLANC, Joshua A. GAUNT, and Heather M. GUZIK. Department of Anatomy, Arkansas College of Osteopathic Medicine, Fort Smith, AR, 72916, USA.

068* The Effects of Cadaver Lab Exposure on Physical and Spiritual Wellness.
PLUTINO, Danielle M., and Alla BARRY. Missouri Southern States University, Joplin, MO, 64801, USA. **MARKS - EDUCATIONAL RESEARCH**

070* SOARing to New Heights: Evaluation of a New Interactive Supplement to a Medical Anatomy Course.
ROYER, Danielle[1], Heather CARMICHAEL[2], Kimi L. KONDO[3], Lisa L. LEE[1], and Cory B. GRITTON[1]. [1]Department of Cell & Developmental Biology, University of Colorado School of Medicine, Aurora, CO, 80045, USA; [2]Department of Surgery, University of Colorado School of Medicine, Aurora, CO, 80045, USA; [3]Department of Radiology, Division of Interventional Radiology, University of Colorado School of Medicine, Aurora, CO, 80045, USA.

072* Can Formative Assessments Preemptively Identify "At Risk" Medical Students?
SCHNEIDER[1], Brandt, Gurvinder KAUR[1], Vaughan LEE[2], Simon WILLIAMS[1], and Katie HIGGINS[1]. [1]Department of Medical Education, School of Medicine, Texas Tech University Health Sciences Center, Lubbock, TX, 79430, USA; [2]Department of Medical Education, School of Medicine, University of South Alabama, Mobile, AL, 36688, USA

074 Vertically and Horizontally Integrating Anatomy in a Doctor of Physical Therapy Curriculum.
STEVENS, Karen M., Jeffrey DAMASCHKE, and Patrick WITHROW. Department of Physical Therapy, Rosalind Franklin University of Medicine and Science, North Chicago, IL, 60064, USA.

075* Body Donor Personal Information: A Survey of AACA Members.
SULAIMAN, Sara[1], Brandi SCHMITT[2], David M. CONLEY[2], Bobbi MORGAN[2], and Dianne PERSON[2]. [1]Centre for Applied Anatomy, University of Bristol, Bristol, BS2 8EJ, United Kingdom; [2]Anatomical Services Committee 2017-2018, American Association of Clinical Anatomists, GA 30241, USA.

076 A Study of Factors Influencing Voluntary Whole-body Donation.
TAYLOR, Megan, Shannon SAMPLE, and Alla BARRY. Missouri Southern State University, Joplin, MO, 64801, USA.

077 'Must See' Videos? Why Educators Need Better Video Analytics to Measure Learning.
LANGLEY, Natalie R., and Sonya E. VAN NULAND. Department of Anatomy, Mayo Clinic College of Medicine and Science, Mayo Clinic, Scottsdale, AZ, 85259, USA.

078* A Case of Osteopathia Striata with Cranial Sclerosis in a 75-Year-Old Female, a Cadaveric Approach.
WANG-SELFRIDGE, Angela A., Karen TONG, Youjin NA, and Anthony OLINGER. Department of Anatomy, Kansas City University of Medicine and Biosciences, Kansas City, MO, 64106, USA. **MARKS - EDUCATIONAL RESEARCH**

079* Medical History in the Curricula of American Medical Schools.
WARD, Peter J., and Lindsey KENT. West Virginia School of Osteopathic Medicine, Lewisburg, WV, 24901, USA.

080* Interactive Digital Histology Sessions - A Method to Improve Student Engagement.
WARD, Peter J. West Virginia School of Osteopathic Medicine, Lewisburg, WV, 24901, USA.

081* Fibrous Metaplasia of Smooth Muscle Tissue of the Tunica Media in Tortuous Arteries.
WIELE, Katie M., Jenny S. KAISER, Crystal R. LEMMONS, and Alla G. BARRY. Missouri Southern State University, Joplin, MO, 64801, USA. **MARKS - CLINICAL ANATOMY**

continued on next page

American Association of Clinical Anatomists

Annual Business Meeting

Agenda

Friday, June 14, 2019
Hyatt Regency Tulsa
Tulsa South Ballroom
Tulsa, Oklahoma

PO Box 2945
LaGrange, Ga 30241
Ph: 706-298-0287
www.clinical-anatomy.org

CALL TO ORDER: 2:00 pm

Approval of Minutes of 2018 Annual Business Meeting (ABM) and the 2019 Annual Business Meeting Agenda

1. **President's Report** – *Marios Loukas*
   a. 2019 Election Results
   b. 2020 Election – Positions open to the AACA Membership in 2020
      i Association secretary (1)
      ii Special councilor for allied health (1)
      iii Councilors-at-large (2)
   c. Presidential Committee Appointments
2. **Treasurer's Report** – *Tom Gest*
3. **Membership Committee Report** – *Neil Norton*
   a. Remembrance of Deceased Members – *Peter Ward*
4. **Journal Committee Report** – *Neil Norton*
   a. Report of Editor-in-Chief of *Clinical Anatomy* – *R. Shane Tubbs*
5. **Meeting Organization & Program Planning Committee Report**–*Jennifer Burgoon*
   a. Report of 2019 Annual Meeting Committee
   b. Future Meetings:
      i Oct. 26th - 2019 AACA Regional Meeting at Samuel Merritt University, Oakland, CA. - *Christina Lewis*
      ii 2020 AACA Annual Meeting, New York, NY. – *Anthony D'Antoni*
      iii 2021 AACA Annual Meeting, Seattle, WA. – *R. Shane Tubbs*
6. **Committee Elections**[1] - *Marios Loukas*
   a. Election of Members-at-Large for Bylaws: *2 vacancies*
   b. Financial Affairs Committee: *1 vacancy*
   c. Nominating Committee: *2 vacancies*
7. **Annual AACA Awards** – *Marios Loukas*
   a. Honored Member Award 2019 – *Dr. Robert Anderson*
   b. R. Benton Adkins Service Award – *Dr. Brian MacPherson*
8. **Old Business**
9. **New Business**

ADJOURNMENT: 3:30pm

[1] The membership of Special Interest Group (SIG) Committees (Educational Affairs, Career Development, Clinical Anatomical Terminology, and Anatomical Services) elects members at their committee meetings.

American Association of Clinical Anatomists

Minutes
2018 Annual Business Meeting

PO Box 2945
LaGrange, Ga 30241
Ph: 706-298-0287
www.clinical-anatomy.org

American Association of Clinical Anatomists
Wednesday, July 11, 2018
Grand Hyatt Buckhead
Atlanta, Georgia

Call to Order: 2:00 pm

Approval of Minutes of 2017 Annual Business Meeting (ABM) and the 2018 ABM Agenda. Approved by membership.

1. **President's Report** (Marios Loukas – AACA President)
   a. **2018 Election Results** – Marios announced the winners of the 2018 AACA election to include: Jennifer Burgoon, Program secretary; Joe Iwanaga and Maira du Plessis, councilors at large, James Coey, Anatomical Services Special Councilor. Gilbert (Gib) Willett is completing the term for Health Sciences Special Councilor.
   b. **2019 Election** – The positions open in next year's election are: President-Elect, Treasurer, two (2) councilors-at-large, Special Clinical Councilor.
   c. **Presidential Appointments and Members Elected to AACA Special Interest Groups**

Anatomical Services Committee

Anatomical Services Councilor, *ex officio:* James Coey
Presidential Appointees
2016-2019: David Conley, Academic Co-Chair
2017-2020: Nirusha Lachman (completing term of James Coey)
2018-2021: Bobbi Morgan, Technical Chair
Members Elected at Annual SIG Meeting of Committee
2016-2019: Nicole Herring
2017-2020: Dianne Person
2018-2021: Scott Barton

Career Development Committee

Presidential Appointees
2016-2019: Sarah Greene, Chair
2017-2020: Maira du Plessis
2018-2021: Estomih Mtui
Members Elected at Annual SIG Meeting of Committee
2016-2019: Eileen Kalmar
2017-2020: Natalie Langley
2018-2021: Eiman Abdel Meguid

Educational Affairs Committee

Presidential Appointees
2016-2019: Mohammed Khalil
2017-2020: Vaughan Lee, Chair
2018-2021: Priti Mishall
Members Elected at Annual SIG Meeting of Committee
2016-2019: Lela Giannaris
2017-2020: Dolgar Baatar
2018-2021: Saskia Richter

Clinical Anatomical Terminology Committee

Clinical Councilor, *ex officio*, Vice Chair: Robert J. Spinner

continued on next page

Presidential Appointees
2016-2019: Brad Martin and Ian Whitmore
2017-2020: Richard Tunstall and Anthony Weinhaus
2018-2021: Paul Gobee and Evan Goldman, Co-Chair
Members Elected at Annual SIG Meeting of Committee
2016-2019: Chelsea Lohman, Co-Chair
2017-2020: Sakti Srivastava
2018-2021: Noel Boaz and Amy Mork

d. Presidential Appointments and Committee Elections at Business Meeting

Bylaws committee

Presidential Appointees (2018-2020)
Kathleen Bubb, Chair
Jon Jackson
Nirusha Lachman
Members Elected at Annual Business Meeting
Diana Pettit
Eileen Kalmar

Financial Affairs committee

Treasurer, *ex officio* (non-voting), Chair: Tom Gest
Presidential Appointees (2018-2020)
Lonie Salkowski
Mohammed Khalil
Member Elected at Annual Business Meeting – One year term
Yasmin Carter

Nominating committee

Presidential Appointees (2018-2019)
Kazzara Raeburn, Chair
Anthony DiAntoni
James Foster
Members Elected at Annual Business Meeting – One year term
Priti Mishall
Stephen Carmichael

Journal committee

President-Elect, *ex officio*, Chair: H. Wayne Lambert
Editor-in-Chief, *ex officio:* Shane Tubbs
Presidential Appointees (2018-2020)
Neil S. Norton

Membership Committee

President-Elect, *ex officio*, Chair: H. Wayne Lambert
Past President, *ex officio*: Neil S. Norton
Presidential Appointee: (2018-2020) Quentin Fogg

Brand Promotion and Outreach

This committee is not yet in the bylaws and we cannot elect at this time.

e. State of the Association

We have invested the Clinical Anatomy signing bonus from Wiley and that money is returning ~4% per year. Based on a restructuring of the AACA budget, we anticipate assets to be ~$900,00 by the end of 2019. Our solid finances give us the opportunity to establish new awards to our members and provide short-term translational research awards for study at St. George University or the Seattle Science Foundation. Donation to support the organization is heavily encouraged. To lead by example, Marios is personally donating $40,000 to the association.

In regard to other benefits, our meetings and post-graduate courses can now provide CME credits through the Seattle Science Foundation. We also plan to offer online access to special presentations made for the AACA as well as talks from the annual meeting.

Moving forward, we hope to host future meetings at Colleges and Universities. The 2020 meeting will be a joint meeting between the AACA and BACA in the United States and we are deciding between three venues for this meeting. We will institute a code of conduct and statement of association values as well as promoting diversity within the association and its committees. We are seeking to collaborate with other associations to exchange sessions hosted by each society that would be of interest to members.

The association will expand our outreach over social media. Chats and webinars hosted by our Special Interest Groups are being investigated and we intend to create a quarterly newsletter for AACA members.

Moving forward, the association is looking very strong. The ad hoc Committee on Clinical Anatomy Certification is plans to roll out the first certificate program in 2019. The impact factor of Clinical Anatomy has reached a new high, 1.905.

2. Treasurer's Report (Tom Gest – AACA Treasurer)

The $550,000 *Clinical Anatomy* signing bonus is invested and is currently $540,930 (after investment fees have been paid). We currently have $354,663 in checking, $5,379 in a money market account that will likely be rolled into other investments in the future. We anticipate a net gain this year of approximately $54,000. ~$11,000 of that gain is from this meeting in Atlanta. Membership dues have grown and brought in $86,000 each year. The journal is also doing well and we are bringing in ~$50,000 each year. We also changed our conference-call software and have saved more than $3000. Using modern conferencing methods is something all committees should investigate. Web income has also increased, based on a small adjustment to our fees for job listings. We may also want to investigate accepting online advertisements to generate a little more income. Tom is interested in staying conservative with our funds and building the capitol to the point on having a significant investment that can produce useful amounts of interest.

Catering has been one of our major expenses. Caitlin Hyatt has significantly reduced the cost of catering for the 2019 meeting in Tulsa. Regional meetings are not big money-makers but they do break even and serve to get the word out about our organization. We are fixing a per diem cap on reimbursement for travel on AACA business. Alcohol is not reimbursed.

We adjusted our pre-paid hours to ASG from 1704 to 1800 in order to budget appropriately.

3. Membership Committee Report (H. Wayne Lambert – AACA President-Elect)

This year 637 active members – the highest number of members we have ever had aside from the year we met at the Disney resort. 40% of the membership join for access to our journal.

Remembrance of Deceased Members (Peter Ward – Association Secretary)

Cynthia MacPherson, wife of Brian MacPherson, passed away last year. A moment of silence was observed.

4. Journal Committee Report (H. Wayne Lambert – AACA President-Elect)

Shane Tubbs has done a tremendous job in moving our association forward while keeping costs low and turnaround time for feedback very short. This last year we voted to re-invest $40,000 into the journal to show that the journal can have a larger impact with an increase in funding from the publisher.

Report of Editor-in-Chief of Clinical Anatomy – R. Shane Tubbs

Shane introduced the editorial board and our international editors. He encouraged members to submit their best work to CA. Previously, our impact factor grew from 1.316 to 1.834, and this year it has become 1.905. This is the highest impact factor in our history and puts us near the top of peer journals, behind Journal of Anatomy (2.479); this is the first year we surpassed Annals of Anatomy and The Anatomical Record.

Top-cited papers covered a variety of topics. The sources of submissions remained similar – U.S., China, India, and the U.K. predominated. Review papers remain highly-cited and highly-read. Special issues on Eye Trauma and Surgical Anatomy of Gender Re-assignment were published in 2017. More special issues will be published in the next few years.

5. MOPP Committee Report (David Porta – Program Secretary)

Thanks to our meeting managers for the last several years: Sarah Green, Jennifer Burgoon, Greg Smith, and Sherry Downie. Jennifer Burgoon is our new program secretary. Moderators and presenters did an excellent job, no one ran over time. A meeting survey will be sent out and we encourage all members to answer and make suggestions that can help us improve.

Upcoming Meetings

2018 AACA Regional Meeting, Georgetown University, Washington, D.C. - *Carlos Suarez-Quian*
2019 AACA Regional Meeting with HAPS, Louisville, KY. - *David Porta (AACA) and Rachel Hopp (HAPS)*
2019 AACA Annual Meeting, Tulsa, OK. - *Elmus Beale*
2020 AACA Joint Meeting with BACA, location TBD

6. Annual AACA Awards (Marios Loukas – AACA President)

Marios recognized our 2018 AACA Honored Member, Dr. Anne Agur. She will be given the award at the banquet later this evening.

7. Old Business

8. New Business

The silent auction remains open until 4 PM and we have currently raised to $1232 to scholarships.

ADJOURNMENT: 3:12 PM

2018 – 2019
Officers of the AACA Council

President - Marios Loukas, M.D.

President-Elect - to be determined in special election

Secretary - Peter J. Ward, Ph.D.

Treasurer – Thomas R. Gest, Ph.D.

Past-President - Neil S. Norton, Ph.D

Program Secretary – Jennifer M. Burgoon, Ph.D.

Councilors

James Coey, MBBS
Anthony V. D'Antoni, M.S., D.C., Ph.D.
Anne M. Gilroy, MA
Joe Iwanaga, DDS, Ph.D.
Lisa M.J. Lee, Ph.D.
Maria du Plessis, MS
Alan T. Richards, M.D.
Robert J. Spinner, M.D.
Shane Tubbs, Ph.D.
Gilbert M. Willett, Ph.D, PT, OCS

Clinical Anatomy

The Official Journal of the American Association of Clinical Anatomists, the British Association of Clinical Anatomists, the Australian and New Zealand Association of Clinical Anatomists, and the Anatomical Society of Southern Africa.

Editor-in-Chief – R. Shane Tubbs

Editor Emeritus – Stephen W. Carmichael

AACA Co-Editors – Senior Editor: Robert J. Spinner; Anthony V. D'Antoni, Thomas R. Gest, Joe Iwanaga, Marios Loukas, Susan Standring

BACA Editor – Philip Adds

Assistant BACA Editor – Jenny Clancy

ANZACA Editor – Stephanie Woodley

ASSA Editor – Graham Louw

Founding Editors: Ralph Ger and Ray J. Scothorne

Editorial Board – 2019
Associate Editors

Marwan F. Abu-Hijleh
Keiichi Akita
Robert H. Anderson
Nihal Apaydin
Peter Dangerfield
Raffaele De Caro
Fabrice Duparc
Jerzy Gielecki
Mohammed Khalil
Hee-Jin Kim
Sanjib Kumar
Nirusha Lachman
Duncan Lee Hamilton
Chelsea M. Lohman Bonfiglio
Vishy Mahadevan
Joanna Matthan
Stuart McDonald
Niladri Kumar Mahato
Ali Mirjalili
Stanley Monkhouse
Garrett Moore
Martin M. Mortazavi
Alan Moulton
Bernard Moxham
Horia Muresian
Richard Newell
Michał Polguj
Alan T. Richards
Elias Rizk
Daisy Sahni
José Ramón Sañudo
Louise Scheuer
Gulgun Sengul
Mark D. Stringer
Richard Tunstall
Albert van Schoor
Ivan Varga
Huan Wang
Koichi Watanabe
Peter L. T. Willan
Bülent Yalçin

Editorial Assistant: Kevin Tubbs

Production Editor: Lisa Wydrzysnki

Committee Reports

Anatomical Services Committee
Brand Promotion and Outreach Committee
Career Development Committee
Clinical Anatomical Terminology Committee
Educational Affairs Committee
Journal Committee
Listserv Report
Membership Committee
Meeting Organization & Program Planning Committee
Nominating Committee

Anatomical Services Committee Report

The Anatomical Services Committee (ASC) represents academic and technical members of the Association who are active in the operations and administration of institutional whole body donation programs. ASC functions to serve the AACA membership by developing symposia, special sessions, courses, and guidance documents and promoting technical and academic aspects of human anatomical tissue use in health care, university education, and research. The group advocates for the informed, ethical, and safe operation of body donation programs in order to support the human anatomical tissue requests of students, faculty, staff, and researchers who contribute to the advancement of medicine through education and research. The ASC meets monthly to focus on topics relevant to the operation of body donation programs including current practices, compliance, ethics, public relations, and to plan future Association annual meeting activities.

2018-2019 ASC highlights:

- Following our meeting last year in Atlanta, the ASC welcomed two new members to our committee: Nirusha Lachman and Scott Barton.
- We de-briefed, reviewed, and reacted to our 2018 ASC Symposium *"HIPPA & PHI in Anatomical Donation, Education & Research"*. Links to these presentations can be found on the AACA website.
- Review of the 2018 ASC meeting and planning for the 2019 meeting.
- Submissions for the Anatomical Services Award are organized for judging and presentation at the annual meeting.

Information about ASC, including position statements, best practices, contact information, and links can be accessed from the Association's website: http://clinical-anatomy.org/Committees

Anatomical Services Committee events at the 2019 AACA Annual Meeting:

Members of the Anatomical Services Committee will be present at the **Welcome Reception** on **Tuesday, June 11th, 6:30 to 8:30 PM**. AACA meeting attendees interested in anatomical services are encouraged to attend, meet the committee members, and learn what we do and how to get involved.

The **Anatomical Services Committee Meeting** will be held on **Friday, June 14th from 10:30 AM to 12:00 PM**. The agenda for this year's meeting features our popular *Lessons Learned* session where real case studies in academic donation programs will be presented and *Ask an Expert* where questions concerning anatomical donation programs will be posed and advice solicited from AACA colleagues in attendance at the session. Other agenda items include a report on the work of the

ASC during the last year and discussion of current topics, future meetings, and symposia. Active AACA members will also be electing a new ASC member. All meeting attendees are welcome! Details of the ASC meeting are at: http://clinical-anatomy.org/Anatomical Services Committee Meeting

****Join the ASC for lunch immediately following our regular meeting to discuss anatomical services issues or to share your experiences****

Current members of the ASC:

Presidential Appointees:

2016-2019: David Conley, Washington State University, Academic Co-Chair – dmc@wsu.edu

2018-2021: Bobbi Morgan, West Virginia School of Osteopathic Medicine, Technical Co-Chair – bmorgan@osteo.wvsom.edu

2018-2020: Nirusha Lachman, Mayo Clinic College of Medicine and Science

Elected Members:

2016-2019: Nicole Herring, University of Louisville

2017-2020: Dianne Person, Elon University.

2018-2021: Scott Barton, University of California

Ex Officio:

James Coey, St. George's University - ASC Special Councilor

Brand Promotion & Outreach Committee (BPOC)

Program Report for 2019 Annual Meeting

Members
Christina Lewis (Chair), Jonathan Wisco (Outgoing Chair Emeritus, Advisory), Nena Mason, Scott Barton, Soo Kim, Kenneth Jones, Danielle Royer.

BPOC Activities
The bylaws governing this *ad hoc* committee are as follows:

The Brand Promotion and Outreach Committee (BPOC) is responsible for the promotion and maintenance of strategic initiatives of the AACA by:

- ✓ *Providing oversight of regional meeting proposals and selecting hosts, in conjunction with the MOPP committee; and, providing logistical support in conjunction with the AACA's professional management service;*
- ✓ *Establishing a promotional and collaborative presence with other professional organizations with* complementary missions (particularly those involved with initiatives related to clinical anatomy research and educational scholarship);
- ✓ Maintaining and updating the AACA website and social media outlets to reflect current events, connect members, and seamlessly tie the efforts of the standing committees together in order to unify the public presentation of the Association;
- ✓ Soliciting information from the membership and monitoring current trends and emerging issues in the field of clinical anatomy to determine how AACA can best meet members' needs; this information will be communicated with the standing Committees and Council;
- ✓ Soliciting information from the membership regarding their perception of: events at the annual meeting, interface of the Society's social media outlets, events that would benefit the Association in the future;
- ✓ Interacting with media on behalf of the Association and directing inquiries to an appropriate member or member of Council;
- ✓ Selectively promoting products or services offered by or endorsed by the Association;
- ✓ Working with each of the standing committees to promote their initiatives to the public and other stakeholders;
- ✓ Recommending further suggestions, as needed, to Council to improve promotion of AACA as a clinically oriented, scientific and educational scholarly institution; and,

Subcommittee Work
We have organized our committee into 4 subcommittees (Regional Meetings, Community Outreach, Social Media, Website).
(1) Regional Meetings Subcommittee

- Members: Jon Wisco, Christina Lewis, Soo Kim
- Purpose: Organize and run two regional meetings per year (previously, just one per year).

The Regional Meetings Subcommittee has achieved the following milestones this year:

- ✓ *This year, 2019, for the first time, AACA will hold 2 regional meetings, and will continue this new plan each year moving forward.*
- ✓ *We had a successful Spring Regional Meeting co-hosted by the AACA in collaboration with the Human Anatomy and Physiology Society (HAPS). The hosting institute was Bellarmine University in Louisville, KY, and the conference Co-Chairs were Dr. David Porta and Rachel Hoop. The program included keynote speakers Dr. Jeffrey Petruska (who talked about how new technologies reveal new anatomy, but the oldies are still goodies too!), and Dr. David Porta (who described forensic anatomy and bone trauma research). There were several workshop sessions, and lots of enthusiasm for co-hosting joint meetings again in the future between AACA and HAPS.*

- ✓ *The next/ Fall Regional Meeting will be hosted by Samuel Merritt University, in Oakland, CA, on Saturday, October 26, 2019. The planning committee includes members Dr. Jon Wisco (Boston University), Dr. Christina Lewis (Samuel Merritt University), Dr. Greg Smith (St. Mary's College), and Dr. Soo Kim (University of Saskatchewan), as well as non-member Dr. Barb Puder (Samuel Merritt University). The theme will be focused around the use augmented approaches for the application of clinical anatomy to inform education, research, and clinical management. The major topics will be 3D modeling, simulation, and motion analysis as approaches to clinical anatomy.*
- ✓ *We are poised to work with you and your institution if you would like to host a Regional Meeting. Come visit with us to learn more!*

(2) Silent Auction Subcommittee

- Members: Christina Lewis, Soo Kim
- Purpose: Organizes and runs a recurring Silent Auction at the Annual Meeting, as well as at Regional Meetings (when possible/ appropriate). Funds raised will fund Early Career Travel Awards to eligible individuals who are attending the Annual Meeting and who have had an abstract for presentation accepted by the Programming Committee. Early Career is defined as students, postdocs, residents, and junior faculty within 10 years of their terminal degree.

(3) Community Outreach

- Members: Christina Lewis, Soo Kim
- Purpose: Identifies and establishes collaborations with professional and avocational groups to promote AACA and serve the community.

The Community Outreach Subcommittee continues to build upon the following milestones:

- ✓ Anatomy Academy has become an official partner with AACA. If you would like to institute service-learning in your curriculum, Jon Wisco, who directs Anatomy Academy can get you started! The program teaches anatomy, physiology and nutrition concepts as an effort to combat the obesity epidemic through educational intervention, and inspire kids to pursue science as a career. Anatomy Academy is low cost (~$200 to get started per classroom, all of which are used to purchase supplies to run the curriculum). The following curricula, compatible with the Core Curriculum model, are freely available to AACA faculty and school site partners: 5th Grade Anatomy, Physiology; Nutrition, 6th Grade Anatomy, Physiology, Nutrition; 7th Grade Dissection and Histology; 8th Grade Musculoskeletal System; Cooking Anatomy Academy; Dance Anatomy Academy; Exercise Anatomy Academy; Special Needs Anatomy Academy. Please direct questions to Jon Wisco or Christina Lewis.
- ✓ We are working with community outreach partners located in the proximity of Regional Meetings to host enrichment service activities for local elementary and secondary school children. Our hope is to provide community service opportunities for AACA members and colleagues.

(4) Social Media Subcommittee

- Members: Nena, Scott Barton
- Purpose: Determines strategies for and implements AACA social media presence

The Social Media Subcommittee has achieved the following milestones this year:

- ✓ We now have a very strong Twitter, LinkedIn and Facebook presence. You can follow on any of these outlets by clicking on the appropriate icon on the AACA website. We encourage you to participate in the opportunity to stay connected through social media!
- ✓ Tweet with us! @AACAnatomy and use the hashtag #ClinAnat2018. Pick up your "I Tweet" ribbon at the registration desk!
- ✓ Follow us on LinkedIn! Stay up to date with AACA news, discover new job opportunities, connect to other members: go to
- ✓ https://www.linkedin.com/company/american-association-of-clinical-anatomists.

(5) Website Committee

- Members: Ken Jones
- Purpose: Works with Association Services Group to maintain content and relevancy of our AACA website.
- The Website Subcommittee has achieved the following milestones this year:
  - ✓ Check out the most recent Member Spotlight on the AACA website!

We thank everyone for their support! If you are interested in getting involved, ask how!

Career Development Committee

The role of the Career Development Committee (CDC) is to support career growth and the advancement of clinical anatomy knowledge for an individual at any stage of their career. Additionally, the CDC strives to encourage high quality anatomical research and scholarly educational work. The committee accomplishes these goals through numerous activities, including: coordinating the judging of student posters (Sandy C. Marks, Jr. Award) and platform presentations (Ralph Ger Award) at the annual meeting, planning and implementing the mentor social at the annual meeting, and planning the Career Development Symposium.

The CDC has been working hard on expanding mentorship opportunities both within and outside of the annual meeting platform. We will be reaching out to our registered mentees ahead of the 2019 meeting to begin to help new and early career members navigate the meeting and network with mentors. The Mentor Reception is a time when we will encourage networking between mentees and mentors.

If you are interested in serving, have a passion for mentoring, or have innovative ideas to promote career growth, please consider becoming a member of the CDC. We will be electing one new member at our breakfast meeting on Thursday, June 13th from 7:30 am-9:00 am. We also look forward to an exciting round table discussion on defining and developing your teaching portfolio, so don't miss out!

Presidential Appointees

Sarah Greene, Chair (sgreene@msm.edu)

Maira du Plessis (maira.duplessis@gmail.com)

Estomih Mtui (epmtui@med.cornell.edu)

Members Elected at Annual SIG Meeting of Committee

Eileen Kalmar (Eileen.Kalmar@osumc.edu)

Natalie Langley (langley.natalie@mayo.edu)

Eiman Abdel-Meguid (e.abdel-meguid@qub.ac.uk)

Clinical Anatomical Terminology Committee

Co-chairs: Chelsea Lohman Bonfiglio and Evan Goldman

Members: Noel Boaz, Paul Gobée, Evan Goldman, Chelsea Lohman Bonfiglio, Brad Martin, Amy Mork, Alan Richards, Richard Tunstall, Sakti Srivastava, Tony Weinhaus, Ian Whitmore

The CAT committee holds meetings on the 1st and 3rd Wednesdays of each month. Subcommittees were created to handle a new set of initiatives; the subcommittees meet on alternate weeks to the regular CAT meetings, or as needed. All CAT meetings are held using video conferencing using "Zoom".

CAT has continued reviewing definitions created by the Dutch company, Incision, whose physician members are creating first-draft definitions of anatomical terms, based on the Patterns and Guidelines document. The definitions are created using CAT's online "definition machine". During the past year, CAT switched from the original Definition Machine, created by Evan Goldman, to a new definition machine, programmed by Paul Gobée. The new Definition Machine uses a web-based, database system. The front-end interface is more streamlined than the original and the back-end is easier to administrate. During 2019, CAT beta-tested the new system and has made continuous updates to its interface and usability.

CAT has worked on redesigning and redeploying the AnatomicalTerms.info (ATI) website. The website now includes direct access to creative-commons images; modified, clarified, and streamlined interface; Approval from the IFAA/FIPAT for ATI to formally house the official Terminologia Anatomica terms is being sought.

The CAT committee submitted an abstract to the 2019 IFAA meeting in London. The abstract was accepted and CAT will be running a three hour symposium entitled, "Towards Standardized Open Anatomical Definitions". The following will be presented at the IFAA symposium:

1. **Brief Historical Overview of the Development of the Modern Anatomical Lexicon and Etymologies**. Presenter: Ian Whitmore.
2. **Rationale for Standardized Definition Initiative.** Presenters: Evan Goldman, Noel Boaz
3. **Presentation of the Proposed Patterns and Guidelines.** Presenter: Paul Gobée, Ian Whitmore
4. **Presentation of Semi-Automated Online Definition-Creation System.** Presenters: Chelsea Lohman Bonfiglio, Paul Gobée.
5. **Workshop to Develop a Series of Anatomical Definitions Using the Definition-Creation System.** Presenter: Sakti Srivastava, Noel Boaz; All CAT attendees will aid in running the workshop.

At the 2019 meeting in Tulsa, CAT's symposium will include a guest speaker, Dr. Scott, an Emergency Medicine physician best known for founding: Boston Medical Publishing, eMedicine/WebMD, Pearlsreview, and StatPearls. He will be talking about the importance of communication between clinicians and anatomists and the role of a common language. He will also discuss the role of Anatomist Editors in StatPearls. Following Dr. Scott's presentation CAT will host a workshop where participants will take a critical look at a clinical manuscript to evaluate the anatomical/medical terminologies used.

New initiatives recently undertaken by CAT include:

1. **Clinical Terminology Initiative** (Noel Boaz, chair). This initiative was undertaken to develop a compendium of clinical terminologies, compare these to the TA terminologies to assess similarities/differences, and develop a system for dissemination via the AnatomicalTerms.info website.
2. **Pronunciation Initiative** – (Evan Goldman, chair). This initiative will evaluate questions of "appropriate pronunciations" across regional and international boundaries.
3. **Technology** (definition machine, ATI, Twitter account) (Paul Gobee & Chelsea Lohman-Bonfiglio, chairs)
4. **Etymology and Eponymous Terms Initiative** – (Anthony Weinhaus, chair) This initiative will develop a compendium of etymologies and eponyms of anatomical terms, and develop a system for dissemination via the AnatomicalTerms.info website.

Educational Affairs Committee

Purpose of Committee: The Educational Affairs Committee (EAC) shall promote the teaching of clinical anatomy, track national and international curricular changes, and develop educational initiatives that will benefit the Association's members, health care professionals, the education community, and the general public. The Committee shall disseminate data and recommendations for best practices for all aspects of anatomical education as it relates to clinical practice. The Committee shall plan and implement the Educational Affairs Symposium when scheduled by the Meeting Oversight and Program Planning Committee. The Committee shall consist of six (6) members, each serving a three (3) year term. The President-Elect shall appoint one (1) member in the second year of his/her term, and the President shall appoint one (1) member in the first year of his/her term. One (1) member shall be nominated and elected by the Active Members in attendance at its annual open meeting.

During the 2018-2019 monthly EAC meetings, discussions focused on creating webinars, planning the EAC breakfast meeting, and exploring scholarly initiatives on integration of clinical anatomy in medical education.

The topic for the 2019 EAC breakfast meeting is **"Choose your Case Wisely!"** After a brief introduction on case-based learning, participants will discuss a sample case and evaluate it using the rubric provided. A facilitated open forum will follow where participants will discuss the results and be encouraged to share their experiences with case-based learning. Participants will leave the meeting with tools for assessing their cases and tips on how to build teaching cases. We hope you'll join the discussion!

For those interested in getting more involved, we will be electing a new member to the Educational Affairs Committee at the breakfast meeting on June 14th.

EAC Members

Presidential Appointees

2016-2019: Mohammed Khalil (KhalilMK@greenvillemed.sc.edu)

2017-2020: Vaughan Lee (vlee@southalabama.edu)

2018-2021: Priti Mishall (Priti.Mishall@einstein.yu.edu)

Members-at-Large Elected at Annual SIG Meeting of Committee

2016-2019: Lela Giannaris, Chair (EustathiaLela.Giannaris@umassmed.edu)

2017-2020: Dolgor Bataar (dolgor.baatar@ttuhsc.edu)

2018-2021: Saskia Richter (saskiarichter@atsu.edu)

Journal Committee Report

Committee Members: Marios Loukas, Neil Norton, Tom Gest, Jinnie Kim (Wiley editor), Phil Adds (ex officio; BACA), Shane Tubbs (Editor-in-Chief).

The journal Clinical Anatomy has had a very successful year and continues to grow and flourish. We continue to publish high quality papers devoted to all aspects of the anatomical sciences that have direct application to several disciplines in medicine, dentistry and surgery. The Journal is on track to receive more submissions in 2019 than any previous year. Additionally, several Special Issues are in the works and will be introduced over the next two years.

The Journal is fortunate to continue to have an international group of experts serving on its editorial board and contributing as co-editors and reviewers. Many thanks to each of these individuals for their support and contributions to making Clinical Anatomy a success.

Please consider submitting your work to the Journal and continue to follow us online, in print, or your mobile device with the Clinical Anatomy app for Android or iPhone users.

Listserv Report

AACA's Education Issues Listserv was moved from the mailserver at Einstein to being hosted on Google Groups in February of 2016. There are currently 1,392 subscribers to AACA's Listserv. From May 1, 2018 to April 1, 2019 there were 58 subjects posted. To the right of this report is a table of those posts that received the most responses.

AACA Education List

Total Subscribers (as of 4/1/19) = 1,392

Most Commented upon Threads

Activity 5/1/18-4/1/19 = 58 messages

May 2018 – April 2019 Monthly Email Activity

May '18 = 4
June '18 = 4
July '18 = 3
August '18 = 6
September '18 = 5
October '18 = 6
November '18 = 5
December '18 = 4
January '19 = 9
February '19 = 4
March '19 = 8
April 1, '19 = 0

Total Emails = 58
Total Replies = 150

Students right to know cadaver identity (17)
Do lectures precede cadaver labs on same day in your course? (14)
Tissue for use in training rescue dogs (11)
Call for participation in Open Anatomical Atlas by Open Education Consortium (11)
Advice re students undergoing cancer treatment sought (9)
Lactation and formaldehyde inhalation (8)

Membership Committee

President-Elect - to be determined

Committee Members - Neil S. Norton, Rachael George, and Quentin Fogg

The membership committee is pleased to state that the following new members have joined AACA from July 25, 2018 to April 1, 2019. The total number of active members in the association is 557.

AFFILIATE

Matthew Farrow

ASSOCIATE POST-DOC ELECTRONIC

Ryan Hillmer
Samia Massaad
Shaina Reid
Laura Solis
Cristian Torres

ASSOCIATE ELECTRONIC

Rasha Alhazzaa
Russell Arellanes
Jessica Avila
Seth Bayird
Cameron Beck
Seth Bergeron
Paulina Blanc
Athena Clemens
Tatum Brianne Colburn
Bernhard Dietz II
Ryan Dyches
Emily Edwards
Meghan Flannery
Christopher Fleming
Anna Forbes
Joshua Gaunt
Ralitsa Gencheva
Julia Haffner
Hannah Hales
John Han
Camryn Hawkins
Shannon Helbling
Jonathan Hunter
Shelley Hunter
Eugene Ismailov
Trenton Jackman
Christopher Johnson
Mai-Lan Johnston
Jenny Kaiser
Sarah King
Bryan Lebron
Hillel Maresky
Jonathan Millard
Mary Moon
Youjin Na
Hannah Newland
Ricky Ng
Tarimobo Michael Otobo
Michael Peng
Allison Pickron
Zachary Pierce
Danielle Plutino
Sinead Joanna Regan
Danielle Reitherman
Mica Rosenow
Scott Rowe
Jessica Rutyna
Gabriella Schreiner
Pranav Sharma
Courtney Shepard
James Spagna
Megan Taylor
Cameron Thiele

continued on next page

Karen Tong
Lang Van
Angela Wang-Selfridge
Katie Wiele
Nadha Fathima Yakoob
Jocilyn Yarnell

REGULAR ELECTRONIC

Kamal Abouzaid
Peter Agaba
Lorreen Agandi
Tamara Alcala Dominguez
Abduljabar Yasin Alhubaity
Ryan Badger-Bridewell
Maria Bartanuszova
Ricardo Belmares
Hugo Bergen
Keith Bishop
Erika Blanck
Yvonne Body
Stephen J. Bordes Jr.
Katherine Brooks
Kristen Bruzzini
Kelsey Byers
Alan Cashell
Mark Clunes
Graham Dupont
Seif Eid
Cory Gritton
Santiago Gutierrez
Heather Guzik
Beth Habelow
Arpan Haldar
John K. Hubbard
Basem Ishak
Hisako Iwanaga
David Jaynes
Skyler Jenkins
Amin Karadaghy
Gurvinder Kaur
Douglas Keskula
Ikue Kikuta
Kathryn E. Klump
Theofanis Kollias
Stefan Lachkar
John Layne
Sang Lee
Stany Lobo
Roberto Lopez-Rosado
Adel Maklad
Naleen Mathur
Lori McGrew
John Patrick McNamara
Allan Meares
Karishma Mehta
Nancy Minugh-Purvis
Rohit Mishra
Kelly McCarver Munizzi
Stephanie Muth
Judi Nath
Kathryn Norton
Annette Occhialini
Anthony Olinger
Nathan Ozobia
Joanne L. Peterson
Jacqueline Phillips
Kelsey Picha
Kimberly Pipe
Adam Puche
Kristina Pugh
Thejodhar Pulakunta
Raja Rachakatla
Rabjot Rai
Vineeta Ramnauth
Krystal Rampersad
Asad Rizvi
Luigi Fabrizio Rodella
Jeffrey Rot
George Salter
Suresh Selvaraj
Steven Snyder
Mitra Soleimani
Karen Stevens
Nitsa Topale
Isaiah Tubbs
Kendall Tubbs
Susan Tubbs
Diane Tyczynski
Kristopher Vaudrey
Nitin Vishwakarma
Alexander von Glinski
Lauren Wahl
Paul Walker
Adam Wilson
Patricia Wisenden
TL Wong
Ashley Yearwood
Mehtap Yuksel Tiryakioglu

REGULAR – PRINT

S. M. Irshad Akhtar
Jenny Brown
Dennis Burke
Nasir Butt
William Mayer
Rea Prakash
Edie Sperling

Meeting Organization & Program Planning Committee Annual Report, 2018-2019

Members:

Special Interest Committees

Anatomical Services Committee, Co-Chairs – Bobbi Morgan & David Conley

Career Development Committee, Chair – Sarah Greene

Educational Affairs Committee, Chair – Lela Giannaris

Clinical Anatomical Terminology Committee, Co-Chairs – Chelsea Lohman Bonfiglio & Evan Goldman

Meeting Managers (Formerly Known as Annual Meeting Committee Co-Chairs)

Sarah Greene 2018-2019

Melissa Quinn 2019-2020

Local Hosts

Elmus Beale – 2019

Anthony D'Antoni – 2020

ASG Representatives (Contracted Professional Organization Management Company)

Caitlin Hyatt, Executive Director

Kendra Tyner, Program Coordinator

Executive Committee

Marios Loukas, President

H. Wayne Lambert, President Elect

Neil Norton, Past President

Tom Gest, Treasurer

Peter Ward, Association Secretary

Jennifer Burgoon, Program Secretary & MOPP Chair

This report is being filed on April 30, 2019. The information contained herein is the most accurate available as of this date. I am completing my first year of my 3-year term as Program Secretary, after serving a 2-year term as a Meeting Manager.

During the 2018-2019 year, the Meeting Organization and Program Planning (MOPP) Committee has worked energetically to bring you the 2019 American Association of Clinical Anatomist (AACA) Annual Scientific Conference. Planning began in earnest immediately following the 2018 Conference in Atlanta by a thorough review of the post-conference surveys. During the year, the MOPP Committee held conference calls on the third Tuesday of each month. The 2019 AACA Annual Conference and the program you are reading are the direct result of the tireless effort of the MOPP Committee and through the exceptional professional support by ASG. Special thanks to Caitlin Hyatt, Kendra Tyner, Melissa Quinn, and Sarah Greene whose work behind the scenes on behalf of the MOPP Committee has made the 2019 AACA Annual Conference possible.

Realizing the importance of having a keynote speaker in the morning to kick-off the day's activities, we have added a new session to the second full day of the conference. This session includes two invited speakers that will have approximately 30 minutes to speak.

Preliminary Planning for Future AACA Meeting

One of my goals for the MOPP Committee is to have in place early the future AACA Annual Conferences. Thus far, we have been able to plan the following:

- 2019 Regional AACA Meeting to be held in Oakland, California on October 26 and hosted by Christian Lewis (Samuel Merritt University).
- 2020 National AACA Meeting to be held in New York, New York from June 15-June 19 and hosted by Estomih Mtui and Anthony D'Antoni (Weill Cornell Medicine).
- 2021 National AACA Meeting to be held in Bellevue, Washington at the end of June and hosted by R. Shane Tubbs (Seattle Science Foundation).

If you are interested in hosting a regional and/or national meeting, please see me at the conference or contact me via email (jennifer.burgoon@osumc.edu).

Abstract Submissions

Each year, the MOPP Committee reviews all its documents, including the Abstract Submission Guidelines, in an effort to improve clarity. The AACA works to accept completed, original, previously unpublished work that has IACUC and IRB approval, if applicable.

The table below shows the recent trends regarding abstracts, attendance, and presentations at our conferences.

Meeting Stats	2019 Tulsa	2018 Atlanta	2017 Minnesota	2016 Oakland	2015 Vegas	2014 Orlando
Initial Abstract Subs	97	147	135	192	147	139
Returned for Format	16	13	10	32	51	20
Late-Breaking Subs	11	15	10	4	21	26
Total Rejections	3	2	1	23	24	10
Registrants	???	350	345	350	338	327?
Platform Presentations	20	24	16	18	22	29
Tech Fair Presentations	0*	7	7	5	3	6
Publishable Posters	67	98	97	115	78	80
Not Publishable Posters	14	29	22	26	43	40

*Note: No Tech Fair will be held during the 2019 AACA Meeting as not enough abstracts were submitted to necessitate the session. The membership is encouraged to submit abstracts that describe technological advancements for the 2020 AACA Meeting so that the Tech Fair can return to the program schedule.

In closing, please let the MOPP committee know of any improvements we can make to the conference through talking to those listed above and/or completing the post-conference survey. As always, we are striving to provide you with the best conference possible.

Respectfully Submitted on Behalf of the MOPP Committee,

Jennifer Burgoon, Program Secretary

Nominating Committee Report

The Nominating Committee consist of Kazzara Raeburn (Chairperson), Anthony D'Antoni, and James Foster as presidential appointees, and Stephen Carmichael and Priti Mishall as elected Members-at-Large. On October 16th 2018, the Committee met for the first time on a conference call. All members of the committee were present. The main aim of the discussion was to nominate a diverse group of candidates from members who are active within the association. At the end of this meeting, the decision was taken to request the full list of members of the association, as well as records of conference attendance for the past 3 years. This provided a list of active members and possible nominees. The committee met several times again during the end of 2018, with the last meeting being held November 29th, 2018. At this meeting, a preliminary list of candidates for each vacant position was produced. The committee was then contacted by the president, indicating the resignation of the current president of the association, and the need for a special election. The committee met again on January 31st, 2019, at which point we finalized the list of candidates for the positions vacant for the regular election, and also submitted a candidate for the special election for President. These nominations were submitted to Dr. Peter Ward, the association secretary. Prior to the submission of names, each candidate was contacted by the chair of the nominating committee to get their acceptance of the nomination, and each candidate was directed to send a copy of their CV to the committee and to the association in care of Caitlin Hyatt, the executive director.

Respectfully submitted on behalf of the committee

Kazzara Raeburn, Chairperson of the Nominating Committee.

Abstracts – Platform Presentations

(Listed by presenting author last name)

AGANDI, Lorreen A., Kristy R. PUGH, Samuel A. TISHERMAN, and Adam C. PUCHE. School of Medicine, University of Maryland, Baltimore, MD, 21201, USA.
Can a Telementor Improve Incision Placement and Vessel Identification in Exposure of Femoral Artery?

INTRODUCTION. In civilian surgery, it is standard practice for surgeons to work as a collaborative team identifying structures and actions. However, in combat surgery, there may be high casualty rates necessitating available surgeons to operate alone. One approach to provide support to the solo-surgeon is a remotely-located telementor viewing the procedure by camera. We asked if a telementor could enhance incision placement and vessel identification in the exposure and control of femoral artery branches when only monitoring the procedure via camera. METHODS. For this analysis, 21 ASSET-trained (Advanced Surgical Skills for Exposure in Trauma course by the American College of Surgeons) surgeons were recruited without advanced knowledge of which procedures they would be asked to perform. They were cohort matched and assigned to either receiving guidance from a telementor or receiving no assistance. Each participant was instructed to mark the incision and perform an exposure of the femoral artery to obtain proximal control on a cadaver. We assessed successful positioning of the incision relative to 3 key placements as well as success at initial identification of the common, superficial and profunda femoral arteries. SUMMARY. The unassisted control group achieved only 46% of the incision placement parameters, which improved to 80% when telementor guidance was available. Initial vessel identification was also improved, from 47% in control to 74% with a telementor. CONCLUSIONS. The results show that approximately half the incision placement positioning and initial vessel identification is incorrect in unassisted solo-surgeons. We also conclude that a telementor viewing via camera is able to significantly improve incision placement and initial vessel identification by the solo-surgeon. (Sponsored by Department of Defense W81XWH-17-2-0011.)

BECK, Cameron M.[1], Austin DICKERSON[1], Kevin KADADO[1], Zach COHEN[2], Somer BLAIR[2], Jenna HOLCOMB[1], and Cara FISHER[1]. [1]Center for Anatomical Sciences, University of North Texas Health Science Center, Fort Worth, TX, 76107, USA; [2]John Peter Smith Hospital, Fort Worth, TX, 76104, USA.
Novel Investigation of the Deep Band of the Lateral Plantar Aponeurosis and Lateral Plantar Nerve.

INTRODUCTION. A recent dissection of a cadaveric foot uncovered a fascial band arising from the medial aspect of the lateral plantar aponeurosis (PA) and diving deep into the foot. A branch of the lateral plantar nerve passed deep to this fascial band. A review of current literature turned up limited and outdated sources, while the most commonly used anatomy textbooks and atlases failed to describe or depict this band. Our study objectives were twofold. First, determine the frequency among cadavers that possess this fascial band. Second, determine the location where the lateral plantar nerve passed deep to it. METHODS. 50 pairs of cadaveric feet were dissected by removing the skin and superficial fascia. If the medial portion of the lateral PA was present, the fascial band was dissected further to determine if it dove deep to the central PA and the tendons of the flexor digitorum brevis and longus muscles to insert on the plantar plates of the 3rd and 4th metatarsophalangeal joints. Images were taken and ImageJ was used to take two measurements assessing the relationship of the tuberosity at the base of the 5th metatarsal to where the nerve crossed deep to the fascial band. Measurements were also taken from the great toe to the heel to assess foot length. SUMMARY. The fascial band was found unilaterally in 10 pairs and bilaterally in 14 pairs. Therefore, 38% of feet possessed the deep band of the lateral PA. On average, the point at which the lateral plantar nerve passed deep to the fascial band was 2.0037 cm medial and 1.6637 cm anterior to the tuberosity at the base of the 5th metatarsal. When separated by sex, both distances were not significantly different ($p<0.05$). CONCLUSIONS. The deep band of the lateral PA should be included in textbooks and atlases because of the frequency of presence and its relationship to the lateral plantar nerve. The clinical implications of this study should be applied to the care of podiatry patients.

DIETZ, Bernhard E., Megan L. BRUINIUS, Evan D. CRAWFORD, and Adam KOLATOROWICZ. Department of Anatomy, Lincoln Memorial University-Debusk College of Osteopathic Medicine, Harrogate, TN, 37752, USA.
Relevant Morphological Pelvic Variation in Mid-Urethral Sling Surgeries.

INTRODUCTION. Over 50% of females over the age of 40 will experience stress urinary incontinence. Precise placement and orientation of mid-urethral slings used in surgical treatment maximize clinical outcomes. This study aims to quantify variation in the spatial relationships of bony pelvic landmarks related to the anchoring sites and orientation of slings placed via the trans-obturator route. This study is the first to investigate morphological pelvic variation relevant to this surgical procedure using landmark morphometric techniques. METHODS. A MicroScribe® G2X digitizer was used to register 11, 3D landmarks from 341 pelvises (females aged 27-84 years) in the William M. Bass Donated Skeletal Collection. Landmark data were subjected to a generalized Procrustes analysis and then a principal components analysis was conducted to identify

continued on next page

landmarks with the greatest variation. Wireframe graphs were created to show clinicians variable pelvic and surgical plane shape. Six additional distance and angle variables were calculated from the landmarks and descriptive statistics were computed. Data were analyzed with MorphoJ v1.06d and SPSS v25. SUMMARY. Morphometric analyses reveal that pelvic floor depth, lateral ischial flaring, and sacral curvature explains 25.1%, 20.5%, and 12.5% of shape variation, respectively. Pubic and ischial landmarks are overall less variable than sacral landmarks. Pelvic inlet and outlet AP dimensions as well as pelvic floor shape are variable; however, the surgical plane defined by the urogenital triangle is relatively stable. CONCLUSIONS. Variability in the ischiopubic rami and related surgical landmarks for the trans-obturator route are predicted to have the greatest impact on sling orientation and placement. Surgeons can use these findings as a reference to more effectively plan and conduct mid-urethral sling surgeries. (Sponsored by the DeBusk Research Fellowship Award, Lincoln Memorial University-DeBusk College of Osteopathic Medicine.)

FOGG, Quentin A. Department of Anatomy and Neuroscience, The University of Melbourne, Melbourne, VIC, 3010, Australia.
Comprehensive Visualisation and Quantification of the Radiocarpal and Intercarpal Ligaments.

INTRODUCTION. The precise anatomy of the radiocarpal and intercarpal ligaments is subject to ongoing scrutiny and uncertainty. Numerous studies suggest a single model of ligamentous pattern, whilst others suggest multiple arbitrary models, or distinct subtype patterns based on wrist morphology and/or function. It has been previously demonstrated that typing of the proximal row carpal bones based on morphology aids in more accurately describing ligament patterns in a functionally and clinically meaningful way. A complete view of these ligament patterns is yet to be assembled. This study therefore aims to quantitatively describe and accurately visualise the complete radiocarpal and intercarpal ligamentous array. METHODS. In addition to collating group data from more than 15 previous studies done in-house, a further 16 body donor specimens (8 Genelyn embalmed, 8 unembalmed; F = 10, M = 6). CT scans of each specimen were segmented to provide unique skeletal templates. Each specimen was dissected under 8x magnification and each ligament reconstructed with a digital microscribe, and integrated with the CT imagery. Ligament dimensions were measured in the same virtual environment as the reconstructions. SUMMARY. Lunate typing clearly separates the majority (69%) of wrists into Type I and Type II. The ligamentous patterns for each reinforce previous suggestions of distinct intercarpal mechanics. Where the lunate typing is indistinct (31%) the ligamentous structures are more pronounced with significant ($p<0.05$) increases in ligament width in both radial and ulnar columns of the palmar ligaments. CONCLUSIONS. The wrist should be considered to be one of two distinct functional types. This is clearly represented in the precise, quantified anatomy described here. This should be reflected in all levels of education, and be considered in clinical management of dysfunction of the carpus.

GIANNARIS, Eustathia Lela, Amanda J. COLLINS, and Yasmin CARTER. Division of Translational Anatomy, Department of Radiology, University of Massachusetts Medical School, Worcester, MA, 01655, USA.
The Donor Rose Ceremony – Providing Closure and Promoting Humanism in the Anatomy Lab.

INTRODUCTION. Learning from an anatomical donor is a unique privilege and often described as a medical student's "first patient". For many students, this experience is the first time they must confront their feelings about death and dying. Without proper reflection and closure, coping with patient mortality in their clinical years can be difficult. A Donor Rose Ceremony (DRC) was implemented based on student feedback and their expressed desire to formally bid farewell to their donor and gain closure on the lab experience. RESOURCES. A ceremony is held in the laboratory soon after the anatomy course has ended. Roses are purchased for each donor and printed copies of a donor-written poem are provided. Blank cards and paper are made available. A one-hour block of time is scheduled, with attendance optional. DESCRIPTION. Since 2014, anatomy faculty have organized a special ceremony at the end of the first-year medical student anatomy course. The DRC includes a brief welcome by faculty, reading of poem "To a Medical Student" by anatomical gift donor Claire Small, placing a rose with their donor, and a moment of silence. Faculty then leave the room and students are given time with their donor to use as desired. Students have the option of leaving notes or artwork to be cremated with their donor. This ceremony has three goals for students: 1) chance to pay last respects to their anatomical donor; 2) opportunity to gain closure on the lab experience; 3) time for a moment of silence in appreciation of the anatomical donors. SIGNIFICANCE. The DRC was created as a student-centered initiative to provide an opportunity for closure from the lab experience. The roses are used as a focal point for the ceremony, but are also a physical gift of thanks. Student comments following this event have included expressions of appreciation, gratitude, and respect. The ceremony has also promoted reflection on the anatomy experience, respect for patients, and the humanity of their donor.

continued on next page

HAN, John R.[1], John TRAN[1], Philip W.H. PENG[2], and Anne M.R. AGUR[1].[1]Division of Anatomy, Department of Surgery and [2]Department of Anesthesia, University of Toronto, Toronto, ON, M5S 1A8, Canada.
Anatomical Study of Innervation of Ankle Joint Capsule: Implications for Image-Guided Intervention.

INTRODUCTION. Chronic ankle joint pain is managed with opioids and arthrodesis, but these interventions have been associated with serious side effects and significant loss of function. A viable alternative is image-guided nerve block and/or radiofrequency ablation (RFA). However, optimizing this technique relies on precise anatomic knowledge of the sensory innervation of the joint capsule. No 3D studies were found documenting the innervation, in relation to bony and soft tissue landmarks, visible under ultrasound and fluoroscopy. The purpose of this cadaveric study was to determine the pattern of sensory innervation of the ankle joint and its association to bony and soft tissue landmarks. METHODS. Three formalin embalmed specimens were used in this pilot study. The saphenous (SAN), tibial (TN), sural (SUN), superficial fibular (SFN), and deep fibular (DFN) nerves and their branches were traced to their termination. Articular branches supplying the joint capsule were identified and digitized (Microscribe® G2X Digitizer) relative to anatomical landmarks and reconstructed in 3D using Autodesk® Maya®. SUMMARY. The ankle joint received innervation from articular branches from the TN, SUN, SAN, and DFN: the posteromedial capsule was innervated by articular branches of TN that coursed through the fat pad deep to the calcaneal tendon; posterolateral and lateral capsule by articular branches of SUN located just inferior to the lateral malleolus; medial capsule by articular branches of SAN which coursed over the medial malleolus; and anterior aspect by articular branches by DFN just inferior to the middle third of the inferior margin of the tibia. CONCLUSIONS. The results of this pilot study provide 3D data of the innervation to the ankle joint and relationship to bony and soft tissue landmarks visible with image-guidance. This provides the anatomical basis to propose novel clinical nerve block/ablation techniques.

ISMAILOV, Eugene L., Derek SCHIRMER, Russell ARELLANES, Andrew DANG, Karen TONG, Angela WANG-SELFRIDGE, Zakary ROSE-RENEAU, Tatum B. COLBURN, and Anthony B. OLINGER. Department of Anatomy, College of Medicine, Kansas City University, Kansas City, MO, 64106, USA.
Relationship Between Wrist Circumference and Left Ventricular Structure in Adult Cadavers.

INTRODUCTION. Wrist circumference (WC) is an easily obtainable measurement that has been shown to be a potential predictor of cardiometabolic risk. WC was shown to be associated with left ventricular structural changes in overweight children, likely via insulin mediated pathways that affect both bone and heart structure. Current study evaluates whether WC is associated with left ventricular mass (LVM) and left ventricular dimensions in an adult cadaveric sample. METHODS. WC was measured on 30 cadavers (average age of 75.7) using dorsal bony prominences of the distal radius and ulna for consistency. The left ventricle (LV) was then isolated by removal of epicardial fat, great vessels, atria, valves and the right ventricle, leaving the septum intact. Left ventricular mass index (LVMI) was calculated to normalize LVM by body size. We used linear regression to analyze the relationship between WC and LVMI, septal thickness and posterior left ventricular thickness. Age, gender were entered as covariates. We then ran the analyses on only the donors with BMI of 25+ to determine if BMI influenced the findings. SUMMARY. In our model, age was significantly associated with increased septal wall thickness, but no significant relationship was observed between wrist circumference and any of our dependent variables. After selecting for donors with BMI of 25 or higher (n=16, average BMI=30.6) the relationship between age and septal wall thickness was not significant. CONCLUSIONS. Our analyses showed no significant associations between WC and measured LV changes. These results indicate that WC may not be a useful predictor of pathologic changes to the left ventricular structure in adults. In comparison to children, we suspect that in adults these relationships are affected by a number of potential factors influencing LV structure independent of bone. Our future goals are to attempt this in live subjects using echocardiographic data and control for these comorbidities.

KALMAR, Eileen L., Melissa M. QUINN, and Kirk M. MCHUGH. Department of Biomedical Education and Anatomy, College of Medicine, The Ohio State University, Columbus, OH, 43210, USA.
Longitudinal Integration of Anatomy: Advanced Anatomy Competencies in Medical Education.

INTRODUCTION. Given the downward trend in hours allotted to anatomy education, better integration of anatomical concepts beyond the first-year medical student experience has become increasingly essential. The need for longitudinal integration of anatomic structural relationships and fascial planes, content that often challenges the early undergraduate medical student, is critical since a working understanding of anatomy is required for nearly all aspects of medicine, including differential diagnosis, image interpretation, and treatment planning. RESOURCES. Advanced Anatomy Competency (AAC) is a dissection-based elective course created to extend the foundational anatomy knowledge base and direct dissection to applications based on clinical rotations. Cadavers from The Ohio State University Body Donor Program were prepared with light embalming solutions and used in the AAC course. DESCRIPTION. The AAC is a 1-month course for the fourth-year medical student. The student with Anatomy faculty guidance and appropriate clinical consultation, creates dissections that mimic treatment plans for cases encountered during their clinical rotations. The limited course duration permits the use

continued on next page

of alternative preservation allowing the dissection process to more closely simulate actual clinical experiences. Ultimately, the students present a comprehensive review of all the procedures explored, why they were used, difficulties encountered and how these difficulties were resolved. SIGNIFICANCE. Each student performs various dissection procedures on more life-like cadaveric material that better approximates normal fascial planes, and tissue mobility and pliability. Students also report an improved appreciation for common anatomical variants. This unique course integrates anatomical concepts, promotes independent student preparation and presentation, and provides an educational opportunity that more closely approximates the clinical experience.

KING, Sarah D., Russell ARELLANES, Victoria GORDON and Anthony OLINGER. Department of Anatomy, Kansas City University of Medicine and Biosciences, Kansas City, MO, 64106, USA.
Branching Patterns of the Mental Nerve.

INTRODUCTION. The mental nerve is essential for sensory innervation of the lower third of the face, yet it is rarely studied and has been given little attention in anatomy and medical text books. Surgical and dental procedures regularly risk encountering the mental nerve, and therefore we decided to better define its branching patterns. The purpose of this study is to analyze the branching patterns of the mental nerve and compare them to the findings and classification of previous reports, to provide clinicians with better anatomical awareness of the course of this nerve. METHODS. One hundred and nineteen mental nerves were dissected from 60 cadavers from the Kansas City University anatomy lab. We determined that the mental nerve distributions followed the five branching patterns previously reported (Types I-V) and found three additional patterns that have not been previously documented (Types VI-VIII). SUMMARY. There was an anatomical anomaly found that did not fit into any of the described patterns. Type I was the most common at 21.01% found, closely followed by Type IV at 20.17%. Type II, which was the most common variation in previous research, was found to be the fourth least common in our study and represented only 10.08% of our specimens. Type VII, one of the newly identified branching patterns, represented 12.61% of our data. The other new branching patterns, Type VI and Type VIII, represented 5.05% and 9.24% of the data respectively. CONCLUSIONS. These findings can help providers predict the location of the mental nerve and its branches when performing dental or mandibular procedures and surgeries.

PETTIT, L. Diana, Heather A. BALSIGER, Ricardo BELMARES, Thomas GEST, and Dolgor BAATAR. Department of Medical Education, Paul L. Foster School of Medicine, Texas Tech University Health Sciences Center El Paso, El Paso, TX, 79905, USA.
Getting the Most Out of Limited Anatomy Time in an Integrated Curriculum.

INTRODUCTION. Due to the need for integration across multiple disciplines, we have less time for anatomy labs than found in traditional curricula with dissection-based anatomy lab. However, our students are still held to the same standard as students in a traditional curriculum. As a result, we have tried to maximize outcomes by combining prosection labs with case-study sessions. METHODS. We compared student performance on Anatomy test questions for our most anatomy-intensive units (51% of all anatomy labs), Gastrointestinal (GI) and Musculoskeletal (MSK). Data for two years of student performance using prosection labs and clinical case study sessions was compared to student performance in a prior year using traditional dissection labs. SUMMARY. Anatomy exam scores were significantly increased with the introduction of prosections and clinical cases in the 2017 (74%) and 2018 (75%) GI units over exam scores from 2016 using only dissection (64%; $p < 0.001$). Student outcomes also improved for the MSK unit, in 2017 (78%) and 2018 (80%) vs. 2016 (72%; $p<0.001$). These results suggest that the combination of prosection labs and clinical case study sessions were more effective than dissection labs within an integrated curriculum. A comparison of performance on 13 GI, and 22 MSK anatomy questions common to exams for all three years showed significant improvement in student performance (GI: 2017, 71%, 2018, 75% vs. 2016, 62%; MSK: 2017, 78%, 2018, 81% vs. 2016, 73%; $p<0.001$). There was no significant difference in performance in non-anatomy disciplines between all three classes ($p >0.5$). These improved outcomes were accomplished in parallel with a reduction in allocated anatomy lab time. CONCLUSIONS. The introduction of prosection labs paired with case study sessions improved student outcomes despite a reduction in anatomy lab time. This approach may be a better alternative to dissection-based anatomy labs for medical schools with an integrated curriculum.

RICHTER, Saskia D., Cailee E. WELCH BACON, and Kellie C. HUXEL BLIVEN. A. T. Still University, Mesa, AZ, 85206, USA.
Influence of a Brief Ultrasound Exposure in Anatomy on Students' Spatial Ability.

INTRODUCTION. While ultrasound (US) exposure is increasingly integrated into health professions education, it is unclear whether US enhances spatial ability beyond skills developed from an anatomy course. This study assessed if a brief US exposure in an anatomy course improves spatial ability scores and perceptions. METHODS. Graduate health professions students in a human gross anatomy course were separated into control (n=68) and intervention (n=62) groups. The intervention group received 3 US modules over 7 weeks on basic principles, shoulder, knee and ankle. US modules included an online narrated presentation (~10min) prior to a hands-on session (~15min). Both groups completed the validated

continued on next page

Mental Rotations Test to assess scored spatial ability (0-24 points) and perceived spatial ability (0-100%) before and after the course. The intervention group completed a perceptions survey using Likert-scale questions (1=strongly disagree, 4=strongly agree) about application, feasibility and helpfulness of US following the US modules. User matched data were used in a generalized linear model with repeated measures to assess group differences over time. SUMMARY. No pre- or post-course differences (P>0.05) on scored (control:14.8±5.2pts, intervention:15.8±5.4pts) or perceived (control:65.8±15.6%, intervention:68.8±16.5%) spatial ability between control (n=31) and intervention (n=32) groups existed. 81% (50/62) of the intervention group completed the perceptions survey and agreed that US is applicable to future practice (3.2±0.7), can identify structures on US (2.8±0.6), and found it helpful in developing spatial ability (3.1±0.6). CONCLUSIONS. While not statistically different in scored or perceived spatial ability, US intervention students perceived the value of US in understanding anatomy and clinical practice. A more integrated US curriculum in anatomy and clinical courses may have greater impact on spatial ability and should be examined for applicability and feasibility.

SATO, Tatsuo. Tokyo Medical and Dental University, Tokyo, 113-0023, Japan.
Photographic Demonstration of Actual Dissection of Lymphatic Relationships: Esophagus and Stomach.

INTRODUCTION. In order to develop function-preserving cancer operations, precise knowledge of the topographic anatomy of the lymphatics, autonomic nervous system and visceral fasciae is of utmost importance. Since there are few reference books to date for surgeons and anatomists, I want to introduce my pictorial demonstration of detailed lymphatic anatomy related to cancer, as based on actual dissections. RESOURCES. Donors were carefully dissected and imaged. Particular attention was paid to the various lymphatic systems closely related to the esophagus, stomach, large intestine and rectum. DESCRIPTION. Regarding the detailed anatomy of the mediastinal lymphatics, the right and left lymphatics differ greatly. The left tracheal lymphatic chain is closely associated with the left recurrent laryngeal nerve. In some cases, the lymph vessels from the esophagus drain into the thoracic duct. Such critical mediastinal points will be shown. As for the lymphatics of the stomach, in addition to the typical lymphatics along the gastric branches of the coeliac trunk, atypical lymph vessels, along the posterior gastric artery, left inferior phrenic artery, and the right gastro-omental vein are demonstrated. Regarding the termination of gastric lymphatics, the interaorticocaval nodes close to the left renal vein deserve careful recognition. SIGNIFICANCE. To develop a 3-D understanding of the critical lymphatics, it is important to view actual dissections that clearly illustrate the topographical relationships of minute structures. Although numerous separate reports have been published, the images presented provide a meaningful culmination of cancer-related lymphatic systems, as demonstrated in large actual dissection
photographs.

SCHREINER, Gabriella and Darren SALMI. Division of Clinical Anatomy, Department of Surgery, School of Medicine, Stanford University, Stanford, CA 94305, USA.
Wolff Parkinson White and Other Matters of the Heart – A Description of a Morphological Anomaly.

INTRODUCTION. Anatomical analysis of cardiac defects is essential for a comprehensive understanding of cardiovascular diseases. Wolff-Parkinson White Syndrome (WPWS) is a rare disease affecting 0.68 to 1.7 per 1000. It is characterized by an abnormal electrical pathway in the heart, often causing episodes of elevated heart rate. Most patients with WPWS have otherwise normal cardiac anatomy. Only 9-32% of patients do have associated structural anomalies, almost all of which are either Ebstein anomaly, hypertrophic cardiomyopathy, or transposition of great arteries. However, we present a case with anomalies not previously reported in association with WPWS. RESOURCES. The patient autopsy report was reviewed for morphological descriptions of all cardiac morphologies. DESCRIPTION. We present the autopsy findings of a 10-year-old girl who had a history of WPWS. She was in her usual state of health until she developed sudden cardiac arrest at home. Autopsy revealed her heart was above average weight for her age, (190g compared to normal=139g). The right atrial appendage demonstrated aneurysmal change including effacement of pectinate muscles. Non-compaction was present in the inner one-third of the left ventricular wall. This area also demonstrated acute myocardial infarct which correlated with the timing of cardiac arrest. Additionally, the right subclavian artery originated directly from the aortic arch distal to the origin of the left subclavian artery. SIGNIFICANCE. WPWS is a rare defect, and only on rare occasion is it concomitant with ventricular noncompaction or aberrant subclavian origin. It is an especially rare occurrence with atrial appendage aneurysm. This case represents the first reported occurrence of this constellation of findings in association with WPWS. The opportunity to learn how the coexistence of all four defects affects the regional structures of the heart poses a unique ability to understand the association between anatomical aberrations and WPWS.

continued on next page

SHAFFER, Harry G.[1], Stanley BENKOVIC[2], Divine NWAFOR [2], and Ashley B. PETRONE [1,3]. [1]Department of Pathology, Anatomy and Laboratory Medicine, West Virginia University, Morgantown WV, 26506, USA. [2]Department of Physiology and Pharmacology, West Virginia University, Morgantown WV, 26506, USA. [3]Department of Neurology, West Virginia University, Morgantown WV, 26506, USA.
Immunohistochemical Analysis of Adrenergic Receptor Density in Cadaveric Cerebrovasculature.

INTRODUCTION. Autoregulation of cerebral blood flow refers the capability of maintaining relatively constant blood flow, despite continuous changes in cerebral perfusion pressure, if pressure stays within the range of 50-150 mmHg. Within the pressure range, it does not seem that the autonomic nervous system plays a role in autoregulation; however, the sympathetic nervous system, may mediate cerebral blood flow where the perfusion pressure falls below 50mmHg. Sympathetic neurons typically use norepinephrine as a neurotransmitter, and norepinephrine binding to alpha-1 causes vasoconstriction, whereas norepinephrine binding to alpha-2 or beta-receptors causes vasodilation of vasculature. Thus, the effect of sympathetic nervous activity is dependent on the receptor type and density present on the vessel. Several experimental studies have concluded that alpha-1 receptors are most abundant on the cerebrovasculature; however, there have been no studies that have examined the adrenergic receptor subtypes and densities in human cadaveric tissue, thus was the purpose of this study. METHODS. Cerebrovasculature was harvested from n=20 cadavers following routine dissection. The anterior, middle, and posterior cerebral arteries, basilar artery, and vertebral arteries were harvested from each cadaver. Vessels were embedded into a 15% gelatin block, frozen at -80 degrees and sectioned at a thickness of 35 micron. Vessel sections were stained with antibodies for three adrenergic receptors: alpha-1a, alpha-2b, and beta-2, and receptor density was calculated using fluorescence microscopy and densitometry. Statistical analyses were performed to compare intra- and inter-subject differences in receptor density across the cerebrovasculature. RESULTS. There were significant inter- and intra-subject differences in adrenergic receptor density within the cerebrovasculature, and receptor density may be influenced by clinical factors, such as age, sex, and cardiovascular risk factors.

SPITZER, Victor M. Center for Human Simulation, University of Colorado School of Medicine, Aurora, CO 80045, USA
Segmentation and Identification of Massive, Three Dimensional Image Data (Visible Human Style).

INTRODUCTION. Segmentation of Visible Human data was completed on original images. This process only required storage of a single slice (original or reconstructed) in computer memory while identifying structures. Anatomical structures, however, do not conform to cardinal planes and can best be identified and segmented when displayed in a plane coincident with the long axis of each structure. Following vessels and nerves is far most efficient when the entire structure is visualized. This requires that all images (the entire 3D volume containing the structure) be in computer (or graphic) memory. The value of the technique was proven on low resolution data (the Visible Human Male) where real-time adjustment of the angles of the reconstructed plane is used to present each structure in an optimal view for segmentation. RESOURCES. A complete female cadaver was recently sectioned and imaged at a resolution on the order of 250 times higher than the Visible Human Male. The new dataset is composed of more than 20,000 images. Each image is 7360 x 4912 pixels. The entire dataset is in excess of two terabytes, well beyond commodity computers today. We have subsampled the data to segment large structures and used smaller regions to identify the smallest visible structures. Both the technique of following vessels and all their branches as well as the results from a major portion of this data will be presented. DESCRIPTION. To implement and test a vascular segmentation tool for massive 3D data. SIGNIFICANCE. The sectioning and photographic imaging process for block face imaging has been vastly improved both in quality and in automation. The segmentation and identification process remains the major bottleneck in producing the 3D modeling and visualization fundamental to virtual reality display and high fidelity simulation. With the spline techniques outlined here it is reasonable to. (Sponsored by the Department of Cell and Developmental Biology and Touch of Life Technologies, Inc.)

STIVER, Mikaela L.[1,2], Luke R. BRADSHAW[3], Ethan M. BREINHORST[3], Anne M.R. AGUR[1,2], and S. Ali MIRJALILI[3]. [1]Division of Anatomy, Department of Surgery, University of Toronto, Toronto, ON, M5S 1A8, Canada; [2]Rehabilitation Sciences Institute, University of Toronto, Toronto, ON, M5G 1V7, Canada; [3]Department of Anatomy with Medical Imaging, Faculty of Medical and Health Sciences, University of Auckland, Auckland, 1142, New Zealand.
Trapezius Architecture in Infancy and Adulthood: Preliminary Developmental Insights.

INTRODUCTION. The 3D morphometric and architectural complexity of the human trapezius has only recently begun to be examined and quantified using in vivo and cadaveric approaches. While most research has focused on adults, the functional involvement of the trapezius changes considerably throughout post-natal development and adulthood. The purpose of this study was to quantify and compare the comprehensive 3D architecture of trapezius between infancy and adulthood using cadaveric digitization and computer models. METHODS. Fiber bundles from the trapezius muscles of two lightly-embalmed female cadavers (6 months and 72 years) were serially dissected, digitized (MicroScribe® G digitizer), quantified, and modeled (Autodesk® Maya®) throughout the entire muscle volume. Architectural parameters, including physiological cross-sectional area (PCSA), muscle volume (MV), and fiber bundle length (FBL), were computed and compared between

continued on next page

functional muscle partitions (descending, transverse, and ascending) and proportionally between the infant and adult specimens. SUMMARY. Significant architectural differences were found when comparing functional partitions within each muscle: the transverse partition consistently had the shortest mean FBL but accounted for over 50% of the whole muscle PCSA. Comparison between the infant and adult muscles revealed distinctly different patterns in FBL range, PCSA, and MV. CONCLUSIONS. Changes in proportional architectural parameters between infancy and adulthood appear to coincide with primary functional roles of the trapezius at each timepoint. Clinically, a better understanding of post-natal trapezius development could help guide therapeutic approaches for chronic muscle pathology. (Sponsored by a Vanier Canada Graduate Scholarship from the Canadian Institutes of Health Research)

THIELE, Cameron M.[1], Sonya E. VAN NULAND[2], and Natalie R. LANGLEY[2]. [1]Mayo Clinic Alix School of Medicine, Scottsdale, AZ 85259, USA. [2]Department of Anatomy, Mayo Clinic College of Medicine and Science, Scottsdale, AZ 85259, USA.
Variation: The Rule Not the Exception.

INTRODUCTION. Anatomy is one of the foundational sciences of clinical knowledge. Medical students typically learn the classic presentation of anatomic structures in textbooks and atlases and reinforce the information with cadaveric learning. This study uses axillary artery (AA) branching patterns to assess the comparability of textbook and cadaveric learning. METHODS. Branching patterns of the axillary artery were documented bilaterally on 14 dissections completed by first year medical students during the anatomy course, as well as postmortem computed tomography scans of the cadavers (n=28 axillae). The recorded data was compared to several commonly-used anatomy textbooks and atlases, and any differences noted. Additionally, a literature review was conducted on 18 articles that documented 943 upper limbs. SUMMARY. Only 3 cadavers displayed the "classic" AA branching pattern presented in textbooks and atlases, one bilaterally and two unilaterally (14% of the sample). The most common variants include the posterior circumflex humeral artery arising as a branch of the subscapular artery (21%), and the lateral thoracic artery arising as a branch of the thoracodorsal artery (25%) or, more commonly, the subscapular artery (29%). These observations are consistent with variations described in the literature, which reports 31 unique variations of the major AA branches. CONCLUSIONS. It is important that students learn authentic, clinically-relevant anatomy, even at the early stages of medical education. Major arterial branches taught based on "classic" presentations in anatomy texts and atlases may not reflect what will be encountered on a routine basis in the operating room. Recognizing anatomic variations is part of surgical competence, and therefore should not be dismissed as one-off or unusual presentations. The classic AA branching patterns were only observed in 14% of axillae in a first-year anatomy course, meaning that variation may be the rule, not the exception.

TRAN, John[1], Philip W.H. PENG[2], and Anne M.R. AGUR[1]. [1]Division of Anatomy, Department of Surgery, Faculty of Medicine, University of Toronto, Toronto, ON M5S 1A8, Canada; [2]Department of Anesthesia, Faculty of Medicine, University of Toronto, Toronto, ON M5T 2S8, Canada.
Augmented Reality for Regional Anesthesia (AR4RA): A 3D Education Tool for Image-Guided Procedures.

INTRODUCTION. Effective image-guided procedures for acute/chronic joint pain requires a detailed understanding of three-dimensional (3D) location and course of articular branches supplying the joint. Previous studies of joint innervation have been descriptive with results summarized using line drawings and photographs. However, recent cadaveric studies have documented 3D nerve trajectory relative to bony/soft tissue landmarks important for image-guided procedures. Although 3D data has been collected in our laboratory, the results are summarized using images of the dissection and 3D models from multiple views. Advances in 3D computer modeling and visualization technology have facilitated the development of platforms to visualize structures in 3D. One such platform is augmented reality which has enabled the visualization of computer-generated 3D models superimposed onto a user's view of the real world. RESOURCES. 3D data of the trajectories of articular branches innervating the knee and shoulder joints, along with bony/soft tissue landmarks, were collected (Microscribe Digitizer/Faro® ScanArm®). Data were modeled using Autodesk® Maya®. The Unity game engine with integrated Vuforia® software development kit was used to create an augmented reality education tool to enable users to interact with the 3D models. DESCRIPTION. A novel research-informed augmented reality tool for mobile devices was developed for regional anesthesia procedures. This AR4RA tool provides a 3D dynamic environment for volumetric visualization of 1) the location and innervation patterns of the knee and shoulder joints and 2) the extent of injectate spread in clinical procedures. SIGNIFICANCE. Translation of 2D images into a 3D environment presents a conceptual challenge, thereby limiting the effectiveness of image-guided procedures. The AR4RA education tool provides a novel platform to enhance understanding of 3D joint innervation patterns to improve the effectiveness of nerve blocks and ablation.

continued on next page

VILDE, Tomas A.[1], Allen DUONG[1], Valera CASTANOV[1], Jason HERMENEGILDO[1], Soo Y. KIM[2], and Anne M.R. AGUR[1]. [1]Division of Anatomy, Department of Surgery, University of Toronto, Toronto, ON M5S 1A8, Canada; [2]School of Rehabilitation Science, College of Medicine, University of Saskatchewan, Saskatoon, SK S7N 2Z4, Canada.
Superior, Middle, and Inferior Parts of Infraspinatus: Do They Have Differing Functional Roles?

INTRODUCTION. Infraspinatus (IS) has been described as having three parts: superior (SP), middle (MP), and inferior (IP). The contributions of each part to IS function is not well understood. This overview aims to integrate the results of 2 anatomic studies and 1 in vivo ultrasound study of the parts of IS to elucidate the possible functional roles of each part. RESOURCES. The results of the 3 studies that will be integrated include: 1) a 3D model of the musculo-aponeurotic architecture of SP, MP and IP; 2) a 3D model of the intramuscular innervation pattern of SP, MP, and IP; 3) architectural parameters if SP, MP and IP collected in vivo with ultrasound (US) imaging during a relaxed resting position and three 90° abducted positions [no rotation (NR), maximal internal rotation (IR), maximal external rotation (ER)]. DESCRIPTION. The 3D models of musculo-aponeurotic architecture and innervation from the anatomic studies confirmed the presence of SP, MP and IP based on architectural differences and independent innervation. SP was found to consist of fibre bundles with similar spatial arrangements to the posterior part of supraspinatus, suggesting SP may be an abductor. The US study supported these findings, as the muscle thickness (MT), and cross-sectional area (CSA) of SP were significantly different on abduction compared to ER and IR? of the shoulder. The US findings of MP suggest that it acts primarily as an external rotator, as MT and CSA were significantly increased in ER in comparison to NR. In addition, CSA and MT during IR were significantly less than NR. MT and CSA of IP were found to be significantly increased during IR in comparison to ER, suggesting IP may be a stabilizer of the scapula during IR. SIGNIFICANCE. The three studies support the potential individual activation of SP, MP, and IP during shoulder abduction, IR, and ER. Common rehabilitation exercises for IS should be investigated to ensure that they are tailored to target all three parts of IS.

WILSON, Adam B.[1], Andrew NOTEBAERT[2], Audra F. SCHAEFER[2], Bernard MOXHAM[3], Shiby STEPHENS[3], Caroline MUELLER[2], Michelle D. LAZARUS[4], Aaron KATRIKH[1], and Williams S. BROOKS[5]. [1]Department of Cell and Molecular Medicine, Rush University, Chicago, IL, 60612, USA; [2]Department of Neurobiology and Anatomical Sciences, University of Mississippi Medical Center, Jackson, MS, 39216, USA; [3]School of Biosciences, Cardiff University, Cardiff, Wales, CF10 3AX, UK; [4]Department of Anatomy and Developmental Biology, Monash University, Clayton, Victoria, 3800, AU; [5]Department of Cell, Developmental, and Integrative Biology, University of Alabama at Birmingham, Birmingham, AL, 35233, USA.
Is there a Shortage of Anatomy Educators? An International Study.

INTRODUCTION. In 2002, a report projected an anatomy educator shortage based on the perceptions of department chairpersons. Now, 16 years later, does a perceived shortage of anatomy educators (AEs) continue to persist? If there is a shortage, how severe is it and is it a global phenomenon? METHODS. Two surveys were internationally distributed to 1) departmental leaders and 2) trainees (i.e., graduate students and postdoctoral fellows) within anatomy-related departments. Trends in the number and type of AE job openings were also explored by analyzing job postings over the past 2 years. Descriptive statistics were used to evaluate perceptions, historical trends, and future projections. SUMMARY. The majority (51% or more) of departmental leaders who responded from the US/Canada (n=81), the European Union (n=52), and 'other countries' (n=26) anticipate they will have 'moderate' to 'great' difficulty hiring AEs in each of the four classic anatomy disciplines over the next five years. Within the US alone, the number of AE job postings for allopathic and osteopathic medical schools has increased from a minimum of 17 postings in 2017 to 25 postings (and counting) in 2018. While the number of open AE positions within the US/Canada and 'other countries' is perceived to remain in a steady state over the next 5 years, the European Union estimates a 5 fold increase in the number of openings. Departmental leaders prioritize AE applicants who have teaching experience (90%), the ability to teach multiple anatomy disciplines (72%), and the knowledge/experience of employing different teaching pedagogies (65%). Through the eyes of most (67.2%) trainees, the current job market is perceived to be highly competitive. CONCLUSIONS. Based on the perceptions of international departmental leaders and trends in documented job postings, the job vacancy gap for AEs continues to widen with the European Union projecting the greatest need for AEs over the next 5 years.

continued on next page

Abstracts – Poster Presentations Session 1

(Listed by presenting author last name)

ARAKAWA, Takamitsu. Department of Rehabilitation Sciences, Kobe University Graduate School of Health Sciences, Kobe, Hyogo, 654-0142, Japan.
Macroscopic and Histological Examination of the Myocardium Architecture in the Human Right Atrium.

INTRODUCTION. Architecture and morphological constitutions of the myocardium in the human right atrium are important for understanding the accurate position of the internodal conduction pathways. Pathologies of the internodal pathways are the subject for the catheter ablation to prevent the atrial flutter and WPW syndrome. Gross anatomical studies with histological examination of the normal myocardium constitutions in the human right atrium including the internodal pathways are very scarce. The purpose of this study is to examine the gross anatomical and histological investigation in the human normal right atrium to know the precise positions of the internodal pathways. METHODS. Gross anatomical observations of the right atrium were performed 7 human embalmed specimens. After careful removing the endocardium, myocardium architectures were recorded by digital images and line drawings. Previously described internodal pathways were partly sampled and examined histologically using the H-E and Periodic acid-Schiff (PAS) stains. SUMMARY. In normal human right atrium, some myocardium could be observed relatively whitish bundles in three internodal pathways, anterior, middle and posterior. In these three internodal pathways, orientations and architectures varied according to the specimens. In H-E stains, histological features of the whitish bundles in the internodal pathways differed from the normal working myocardium. In the PAS stain, reaction of the whitish myocardium varied notably in the middle pathway. CONCLUSIONS. These variation of the whitish myocardium with positive reaction of the PAS stain might be corresponded with the variation of the internodal pathways. In using the catheter ablation for the right atrium, this data could be used as a basis for the diagnosis and appropriate procedures.

BAIDYA, Ritwik, Sushil KUMAR, Anthony V. D'ANTONI, Santosh SANGARI, and Estomih P. MTUI. Division of Anatomy, Department of Radiology, Weill Cornell Medicine, New York, NY 10065, USA.
Situs Inversus Totalis in a Female Donor Who Died at 55 Years: Case Report and Literature Review.

INTRODUCTION. Situs inversus totalis (SIT) is a very rare congenital anomaly (1/10,000 births) characterized by transposition of thoracic and abdominal viscera. SIT can be completely missed or misdiagnosed in clinic. RESOURCES. A female donor who died at age 55 was dissected during an anatomy course. DESCRIPTION. Cardiac anomalies included cardiomegaly, single atrial chamber, membranous interventricular septal defect and patent ductus arteriosus. Both the lungs had three fissures. Thoracic aorta was on the right and superior vena cava (SVC) on the left. Length of ascending aorta and arch of aorta were 76.50 and 33.97 mm and their diameters were 38.94 and 38.78 mm, respectively. Right brachiocephalic vein (length, 63.64 mm) coursed across the midline to unite with a short left brachiocephalic vein (length, 13.85 mm) to form the SVC on the left. The SVC in turn entered into the atrial chamber via the coronary sinus. No inferior vena cava (IVC) opening into the right atrium was seen; rather a hepatic vein drained directly into it. In the abdomen, there was malposition of the small intestine, colon and retroperitoneal structures. The small intestine was located on the right, whereas the colon was on the left and more inferiorly positioned. There were multiple splenic nodules on the left located between the body of stomach and diaphragm. Hepatomegaly was observed with no groove for IVC. The IVC was to the left of abdominal aorta and vertebral column, and its continuation into the thorax was seen as a left-sided azygos vein which drained into the left-sided SVC. The right gonadal vein drained into the right renal vein, whereas the left gonadal vein drained into IVC. SIGNIFICANCE. SIT may develop as part of multiple malformational disorders such as Kartagener syndrome. It is generally an autosomal recessive condition, although it may be X-linked. It is important to inform medical personnel of a SIT diagnosis in order to decrease errors and prevent complications in clinic.

CASTELLANOS, Bedia, Naveen Babu KANDAVALLI, Sushama RICH, Ramona BAEZ, and Carlos QUINTEROS. Department of Anatomy, Touro College of Osteopathic Medicine, New York, NY, 10027, USA.
Repositioned Common Hepatic Artery with Very Rare Anterior Portal Vein.

INTRODUCTION. Anterior unpaired branches at three different levels of the abdominal aorta provide arterial vascularization to the gastrointestinal system. The celiac trunk is the first unpaired branch of the abdominal aorta which trifurcates into left gastric, splenic and common hepatic arteries. In the present case, there is a repositioned common hepatic artery with portal vein lying anterior in the portal triad, which makes this case report unique. RESOURCES. During a routine dissection of the abdominal region in a 96-year-old female donor, an infrequent branching pattern of the celiac trunk was observed. Further dissection of the blood supply to the abdominal viscera was performed and the specimen was photographed. DESCRIPTION. After reflecting the anterior abdominal wall, the vessels and ducts within the hepatoduodenal ligament were dissected

continued on next page

along with the branches of the celiac trunk and tributaries of the portal vein. The celiac trunk was bifurcating into the left gastric and splenic artery. The common hepatic artery was arising from the superior mesenteric artery and followed normal anatomical branching pattern. The abdominal aorta and the rest of its branches were dissected and inspected. The aorta was found to be tortuous and followed the normal branching pattern. Posterior to the pancreas, the superior mesenteric vein joined the splenic to form the portal vein that coursed anteriorly in the portal triad. SIGNIFICANCE. Repositioned common hepatic variants are of considerable importance in liver transplants, laparoscopic surgery, radiological abdominal interventions and penetrating injuries to the abdomen. Portal vein variants are easy to recognize and in case of complex surgical or interventional procedures, these variations should be described in imaging studies because of their considerable impact on subsequent surgical and interventional radiological procedures.

CASTANOV, Valera, Maxine D. VIENNEAU, and Anne M. R. AGUR. Division of Anatomy, Department of Surgery, University of Toronto, Toronto, ON, M5S 1A8, Canada.
Do Functional Pairs of Extraocular Muscles Have Similar Excursion and Force Generating Capabilities?

INTRODUCTION. Strabismus, characterized by ocular misalignment, has been found to affect approximately 2-5% of the population in Eastern Europe and North America. One of the reported causes of ocular misalignment is extraocular muscle (EOM) imbalance. However, morphometric studies are scarce and do not quantify architectural parameters such as physiological cross-sectional area (PCSA), an indicator of relative force-generating capability, and fibre bundle length (FBL), an indicator of excursion capability. Therefore, the purpose of this pilot study was to model in 3D the architecture of the six EOMs and compare their relative functional characteristics based on quantified architectural parameters. METHODS. The EOMs and levator palpebrae superioris (LPS) of one formalin-embalmed specimen (80yr) were serially dissected, digitized (Microscribe® G2X Digitizer), and modelled in 3D (Autodesk® Maya®) bilaterally. FBL, PCSA and muscle volume (MV) of the functional pairs of EOMs (inferior oblique (IO)/superior oblique (SO), inferior rectus (IR)/superior rectus (SR) and medial rectus (MR)/lateral rectus (LR)) were computed and compared. SUMMARY. SO and SR were found to have the shortest and longest mean FBL, respectively. IO, SR and LR had longer mean FBL (2-7mm) than their antagonistic counterpart. Of the functional pairs of EOMs, the LR/MR had the greatest PCSA followed by IR/SR. The PCSA of IO/SO was about 4-5 times less than that of the other functional pairs. One muscle of every functional pair had smaller PCSA compared to the other, with the difference ranging from 1.3cm2 LR/MR to 1.8 cm2 IR/SR. CONCLUSIONS. Based on the findings of this study, SR had the greatest excursion capability and SO the least. LR had the greatest relative force-generating capability (PCSA), whereas SO had the smallest. This is a novel, pilot-study that provides insight into the architecture and functional characteristics of EOMs. Future studies with an increased sample size are warranted.

COLBURN, Tatum B., Zakary ROSE-RENEAU, Karen TONG, and Anthony OLINGER. Department of Anatomy, Kansas City University of Medicine and Biosciences, Kansas City, MO, 64106, USA.
Rare Anatomical Variation of the Psoas Minor Muscle and a Review of Its Variants.

INTRODUCTION. The psoas minor muscle is flat, fusiform, and small muscle that lies anteromedial to the larger psoas major muscle. It functions to stabilize the hip joint, aids in lateral flexion of the lumbar spine, and to assist in the balance of the trunk. It originates from the 12th thoracic vertebra, 1st lumbar vertebra, and the corresponding intervertebral disc and is innervated by the first lumbar nerve. The psoas minor muscle is well known as a variable muscle that has a high propensity for being absent, approximately 56%. When found, it has a high rate of variation in origin, insertion, muscle heads, as well as variations with race and sex. Variations in this muscle are important for clinical function and pathologies, particularly psoas minor syndrome. Previous studies have explored the variations of psoas minor however, detailed descriptions are scarce. RESOURCES. In this case, we describe an anatomical variation not found in a previous literature review, a psoas minor muscle with two muscle bellies, one at its insertion point and the other at its origin site. DESCRIPTION. An 83 year old female cadaver at death with a history of Parkinson's disease and chronic obstructive pulmonary disease underwent routine dissection of the posterior abdominal wall. Gross anatomical observation found on the right side, a psoas minor with two muscle bellies, one at its insertion point and the other at its origin site. SIGNIFICANCE. Knowledge of the potential for the presence of a rare psoas minor muscle with two muscle bellies has clinical significance given that psoas minor syndrome can result in the spread infection and malignancy to the retroperitoneal region of the body, and as such clinicians should be aware of this anomaly prior to treatment. Further studies are needed to fully determine the effects of this psoas minor variant on clinical function and pathologies.

continued on next page

DYCHES, Ryan[1] and Heather F. SMITH[2,3]. [1]Department of Osteopathic Manipulative Medicine, Arizona College of Osteopathic Medicine, Midwestern University, Glendale, AZ, 85308, USA; [2]Department of Anatomy, Arizona College of Osteopathic Medicine, Midwestern University, Glendale, AZ, 85308, USA; [3]School of Human Evolution and Social Change, Arizona State University, Tempe, AZ, 85287, USA.

Anatomical Study of Celiac Trunk Angle and Its Association with Median Arcuate Ligament Syndrome.

INTRODUCTION. Median arcuate ligament syndrome (MALS) is a rarely diagnosed condition resulting from compression of the celiac trunk (CT) by the median arcuate ligament (MAL) of the diaphragm. Ischemia due to reduced blood flow through the CT and/or neuropathic pain resulting from celiac ganglion compression may result in a range of gastrointestinal symptoms, including nausea, postprandial discomfort, and weight loss. However, the mechanism of compression and its anatomical correlates have not been thoroughly investigated. It has been hypothesized that the CT angle of origination may be more acute in individuals with MALS; however, this relationship has not been empirically tested. METHODS. Frequency of anatomical variation in the MAL and CT were assessed in 35 cadaveric subjects (17M/18F). Variables recorded included vertebral level of origin of the CT and superior mesenteric artery (SMA), distance between the CT and each of the MAL and SMA, angles of origination of the CT and SMA, diameter at CT base, and presence of MAL compression. Chi-squared analyses were conducted to determine whether significant sex differences existed in frequency of MAL compression, and ANOVAs assessed differences in other anatomical variables. Correlation and Partial Correlation analyses (controlling for age) were performed to assess the relationship among each pair of variables. SUMMARY. Females were found to exhibit significantly higher rates of MAL compression than males. Significant correlations were revealed between MAL compression and angles of origination of celiac trunk and SMA. However, the origin of the celiac trunk in individuals with MAL compression was not significantly higher than in those without. CONCLUSIONS. Sex differences in MAL compression that have been reported clinically by patients are corroborated. This study revealed a significant relationship between MAL compression and angle of origination of the celiac trunk.

FLANNERY, Meghan M.[1], Emily L. DURHAM[1,2], Kalpana Deepa Priya DORAYAPPAN[3], Eileen L. KALMAR[1], Michelle D.S. LIGHTFOOT[3], Michael F. TWEEDLE[4], and Karuppaiyah SELVENDIRAN[3]. [1]Department of Biomedical Education and Anatomy, College of Medicine, The Ohio State University, Columbus, OH, 43210, USA; [2]Oral Health Sciences, Medical University of South Carolina, Charleston, SC, 29425, USA; [3]Department of Obstetrics and Gynecology, College of Medicine, The Ohio State University, Columbus, OH, 43210, USA; [4]Department of Radiology, College of Medicine, The Ohio State University, Columbus, OH, 43210, USA.

Identification of Tissue Factor as a Potential Biomarker for Early Detection of Ovarian Cancer.

INTRODUCTION. Ovarian cancer is the deadliest gynecologic malignancy. Although curable if detected in early-stage disease, most cases go undetected until advanced-stage, largely due to the lack of an effective screening tool or biomarker. The protein tissue factor (TF) is expressed in many different tumor types, but not on most normal tissues. Previous studies have shown TF expression on angiogenic, tumor-associated vascular endothelial cells (VECs), but not normal VECs. Because angiogenesis is an early event within tumor development, tumor-specific angiogenic markers represent attractive diagnostic targets. The objective of this study was to identify TF expression in ovary tumors and their VECs and its potential as a biomarker for ovarian cancer detection. METHODS. TF expression was examined in both ovarian cancer cell lines, as well as patient-derived tumor samples via western blotting. Serial sections of murine and human ovarian tumors were IHC stained with either anti-TF or anti-CD31 (to confirm localization on endothelial cells). Additionally, serial sections of normal murine ovary tissue were also stained with anti-TF and anti-CD31 to demonstrate the specificity of TF to tumor-associated VECs, and not those of normal ovary VECs. SUMMARY. We have identified TF expression on tumor-associated VECs in both mouse and human tissues, but not on normal murine ovary VECs. Quantification of TF expression showed that TF is more highly expressed in murine and patient ovarian tumor samples than controls. CONCLUSIONS. Early detection is key for reducing the high mortality rate associated with ovarian cancer. As angiogenesis represents an early event in tumorigenesis, our findings of TF expression on tumor-associated VECs, and not those of normal ovary VECs, suggest that TF has promise as a biomarker for early ovarian cancer detection.

GENCHEVA, Ralitsa, Bryce GIBSON, Anthony FORREST, Shruthi GARUGU, and Sumathilatha SAKTHI-VELAVAN. Department of Biomedical Sciences, Marian University College of Osteopathic Medicine, Indianapolis, IN, 46222, USA.

A Unilateral Pelvic Kidney with Variant Vasculature: A Case Report.

INTRODUCTION. The incidence of pelvic ectopia accounts for approximately 1 out of 2,500 live births. Although pelvic kidneys are most often asymptomatic, they can be associated with a number of pathologies including hypertension. Pelvic kidneys frequently present with an atypical and variable blood supply, thus being surgically significant. This report describes a case of a unilateral pelvic kidney with multiple vascular variations, and this case is reported to provide additional insight of the variability and its correlation to surgical anatomy. RESOURCES. During routine dissection of a 65-year-old Caucasian male donor, a pelvic kidney was discovered on the right side. The posterior abdominal wall and pelvis were dissected in

continued on next page

detail to note the position, vascularity, and relation of both the kidneys. DESCRIPTION. The right kidney was smaller than the left, and its hilum was facing anteriorly. It was positioned anterior to the right psoas major at the L4-L5 vertebral level. The right renal artery originated from the abdominal aorta just above its bifurcation, and it branched into five divisions to enter the pelvic kidney. Multiple renal veins emerged from the kidney and drained into the inferior vena cava. Five major calyces emerged at the hilum and united to form a single ureter. The left kidney was normal in position and vasculature. SIGNIFICANCE. Pelvic ectopia occurs due to brief interference of the developing kidney, ureter, and vasculature. In addition to the abnormal anatomical position, pelvic kidneys are often malrotated, thus presenting significant variations in vasculature and ureter positioning. It is essential to evaluate the position and functionality of pelvic ectopic kidneys prior to abdominopelvic surgical procedures to avoid intraoperative complications.

ISMAILOV, Eugene L., James Y. YANG, Andrew S. LANGILLE, Seth J. LARSEN, and Sarah A. KEIM. Department of Anatomy, College of Medicine, Kansas City University, Kansas City, MO, 64106, USA.
Anatomic Variation of Short Gastric Artery in Relationship to Splenic Blood Supply.

INTRODUCTION. With increasing prevalence of gastroesophageal reflux disease and obesity, Nissen fundoplication and sleeve gastrectomies are commonly performed. These surgeries require dissection of the gastrosplenic ligament, prompting prior studies of the branches of the splenic artery embedded within the ligament in relation to the stomach; however, these studies failed to address their association with the spleen. Due to anatomic variations of short gastric arteries that extend from the stomach to the spleen, ligation of the gastrosplenic ligament carries a risk of splenic infarction. This can cause several post-operative complications such as abdominal pain and splenic abscesses. This study analyzes the variations of the short gastric artery and its splenic contributions. METHODS. 28 cadaveric abdominal cavities were accessed by making incisions from the xyphoid process to the pubis and along the interspinous plane. The gastrosplenic ligament containing the short gastric vessels was identified and explored to visualize arteries extending between the stomach and the spleen. SUMMARY. Several important variations were identified. 21.4% (6 of 28) of the cadavers had a short gastric artery extending from the stomach to the spleen, with an anastomosing branch from the splenic artery supplementing the splenic blood supply. 39.3% (11 of 28) had an isolated short gastric artery extending from the stomach to the spleen. Overall, 60.7% (17 of 28) cadavers had a short gastric artery with a direct connection from the stomach to the spleen. CONCLUSIONS. A significant portion of the population possesses variations of the short gastric arteries which contribute to the splenic blood supply. Isolated blood supply from the stomach to the spleen may confer increased risk of splenic infarct after surgery. Awareness of the prevalence of the described variations will allow surgeons to more accurately assess the operative risks associated with ligation of the gastrosplenic ligament.

KARADAGHY, Amin A., Matthew J. BELL, Evan S. QU, Daniel T. DALY and Yun TAN. Center for Anatomical Science and Education, Department of Surgery, School of Medicine, Saint Louis University, St. Louis, MO, 63104, USA.
Retro-External Iliac Megaureter with Extrarenal Calyces and Associated Arterial Anomalies.

INTRODUCTION. A number of rare anatomical anomalies were observed in a 96-year-old female cadaver during a routine dissection in the fall of 2017 medical anatomy course. RESOURCES. The cadaver was obtained through the Gift Body Program at the Center for Anatomical Science and Education, Department of Surgery at Saint Louis University School of Medicine. DESCRIPTION. A markedly dilated left extrarenal pelvis with a diameter of 3.15 cm was noticed. Three major calyces were found outside of the normal sized left kidney. The left ureter ran inferiorly, crossed over the left psoas minor and major muscles, passed posterior to the external iliac artery and medial to the internal iliac artery, then continued to the bladder. The left ureter was most dilated, having a diameter of 1.7 cm, when traveling over the psoas muscles. The abdominal aorta, instead of normal bifurcation, branched to right common, left external, and left internal iliac arteries. The median sacral artery was a direct branch from the right common iliac artery. No hydronephrosis was observed on the affected side, and no urinary tract anomalies were observed on the right side. SIGNIFICANCE. The retro-iliac megaureter is a rare congenital anomaly, with less than 25 cases reported, and our case of retro-external iliac megaureter appears to be rarely reported. Additionally, the extrarenal calyces are amongst the rarest anomalies of the renal collecting system. Further, this is one of few reported cases of the observed branching pattern of the abdominal aorta. Combined, these anomalies appear to be quite rare, and the relationship between them is unclear. Common clinical manifestations of retro-iliac ureters are the results of ureteric obstruction, hydronephrosis and secondary infection. Knowledge of these anomalies can help radiologists and surgeons make a definitive diagnosis and prevent inadvertent injury during surgery.

continued on next page

LOZANO, J. Antonio, and W. Allan BESSELINK. The University of St. Augustine for Health Sciences, Austin, TX, 78739, USA.
The Master Knot of Henry: A Dynamic Role in Heel and Foot Pain?

INTRODUCTION. The Master Knot of Henry (MKH) has historically been described as an anatomical variation noted at the intersection of the flexor digitorum longus (FDL), the flexor hallucis longus (FHL) and the quadratus plantae (QP). This consists of accessory bands between one, two, or three of these structures. However, there is a lack of current research on the topic. RESOURCES. The feet of eight embalmed cadavers (16 feet in total) were dissected for visualization of the second layer, including FHL, FDL, and QP. DESCRIPTION. In all 16 feet, the MKH was clearly visualized. While variations existed in terms of the configuration of the bands, all the feet consistently displayed the MKH. The main characteristic observed was the blending of fibers directly from the QP into the division of the FDL at the MKH, while the FHL intersects with the FDL in a common fibrous sheath. In some feet, this band attached to the first metatarsal. SIGNIFICANCE. Although these differences have been historically noted as anatomical variations in the literature, the MKH was consistently noted in the second layer of all the dissected feet. The MKH and its dynamic nature may play a role in the production of heel and foot pain and may differentiate from other misdiagnosed clinical conditions such as plantar fasciitis.

PENG, Michael, Kathleen CHENG, Joshua WONG, Erin BOYNTON, and Anne M.R. AGUR. Division of Anatomy, Department of Surgery, University of Toronto, Toronto, ON, M5S 1A8, Canada.
Role of the Abdominal Musculature in Core Stability: A Novel 3D Anatomical and Biomechanical Study.

INTRODUCTION. Functionally, the abdominal muscles, including external (EO)/internal (IO) obliques, transversus abdominis (TA), and rectus abdominis (RA) have been described as muscles which provide core strength and stability to the trunk. Rehabilitation programs promoting core training have demonstrated some success, however, the contributions of the abdominal muscles have not been elucidated. Few studies have investigated abdominal muscle morphology; no volumetric studies were found. The purpose of this study was to model and quantify the 3D architecture of EO, IO, RA, and TA to enable comparison of relative functional capabilities. METHODS. A Microscribe® G2X Digitizer was used to digitize the fibre bundles and aponeuroses throughout the volume of each muscle (n=3 specimens). Digitized data were reconstructed into 3D models (Autodesk® Maya®). The morphology was analyzed and architectural parameters including fibre bundle length (FBL), pennation angle (PA), and physiological cross sectional area (PCSA) were computed and compared. SUMMARY. EO was the largest muscle which spanned the full length of the anterior aponeurosis, from the ribs to the ilium, with 4-5 partitions based on FBL and attachment sites. The muscle belly of IO was located inferolaterally, whereas as the belly of TA was U-shaped with the longest fibre bundles spanning the thoracolumbar fascia and TA aponeurosis. IO had the greatest mean PA (39.4 ± 18.3^{o}), being 3 times greater than EO and 1.4 times greater than TA. However, EO had the greatest mean FBL, almost double that of TA. CONCLUSIONS. Musculoaponeurotic architecture of the abdominal muscles has been captured at the fibre bundle level, providing 3D data for finite element and biomechanical modelling. Based on the results, comprehensive in vivo ultrasound protocols could be developed to investigate the role of the abdominal muscles in normal core stability and related pathology, such as unilateral imbalance injuries in overhead athletes.

PULAKUNTA, Thejodhar, Akram JAFFER, and Rob SANDESKI. Department of Medical Neuroscience, Dalhousie University, Halifax, NS, B3H 4R2, Canada.
Incidence of Abnormal Obturator Artery in the Maritime Population.

INTRODUCTION. Abnormal obturator artery (AOA) is the term used to describe an origin of the obturator artery (OA) from the external iliac artery (EIA) instead of the internal iliac artery (IIA). The knowledge of incidence and presence in a patient of such an artery is essential for surgeons operating in this region because it could be cause for fatal bleeding. Anastomoses between the obturator and external iliac vessels is rightfully termed the Corona Mortis (or the crown of death). There are many cadaveric and clinical studies on the AOA and its importance, we have conducted this cadaveric study to document the incidence in maritime population. METHODS. Body donors to our cadaver program are exclusively from the maritime population and are between 60-80 years. We studied 150 cadaveric hemi pelvises and 40 cadaveric full pelvises to observe the origin of the OA. SUMMARY. Of the total 250 hemi pelvises that we studied 130 were right sided and 120 were left sided and 115 male and 135 female pelvises. 65 of the pelvises had the OA arising from the EIA of which 25 were direct branches of EIA and the remaining 40 were arising from inferior epigastric artery (IEA). 10 out of the 65 had bilateral AOA. 185 of the 250 hemi pelvises had the OA arising from the IIA, out of which 20 were direct branches of the IIA and 140 were branches from the anterior division of the IIA and the remaining 25 were branches from the posterior division of the IIA. AOA did not have a gender preponderance. CONCLUSIONS. The incidence of AOA seems to be over 25% in the Maritimes, and 4% of the times it was bilateral. There is no statistically significant difference in the incidence reported by other studies in different populations. Considering how the existence of an AOA could be fatal if not ascertained, surgeons should be aware of its presence and avoid its injury.

continued on next page

QUINTEROS, Carlos I., Steve A. ORELLANA, Haley A. MEGARITY, Varsha VENKAT, Bryan A. LEBRON, Young PARK, Samiyyah TILLMAN, Alessia ZAMBRANO, John CHOI, Bedia CASTELLANOS, and Reine Y. SINTHIA. Touro College of Osteopathic Medicine, New York, NY, 10027. USA.
Aberrant Testicular Artery.

INTRODUCTION. The testicular arteries typically originate from the abdominal aorta at the level of the second or third lumbar vertebrae. In some cases, the right testicular artery arises from the right renal artery, referred to as an aberrant testicular artery. This abstract reports a right testicular artery originating from the right renal artery. RESOURCES. During routine dissection of an 85-year-old Caucasian male donor an aberrant testicular artery was found. DESCRIPTION. During dissection of the peritoneal and genitourinary cavities, we discovered a right testicular artery branching from the right renal artery at the intervertebral space between the first and second lumbar vertebra. The right testicular artery then follows the predictable trajectory on the right side, passing anterior to the inferior vena cava and posterior to the middle colic, ileocolic and the terminal ileum arteries. SIGNIFICANCE. Our variation is of significance, from not only a developmental standpoint, but a physiological one as well. Unusual origins of arterial vasculature are important considerations for physicians performing urogenital or abdominal surgical procedures, as reports have shown hemorrhagic post-operative complications following retroperitoneal surgeries tend to occur at higher rates in patients with testicular vascular variations.

RUTLAND, Marsha D., Chris R. GRAVES, Amanda R. RICHTER, Mary E. SAMMANN, and Aaron W. WALLING. Department of Physical Therapy, Hardin-Simmons University, Abilene, TX, 79698, USA.
Could a Large Umbilical Hernia Be Associated with a Connective Tissue Disease?

INTRODUCTION. Large umbilical hernias are commonly seen with obesity. Abdominal hernias may be related to connective tissue dysfunction with the development of other conditions, such as colon diverticulitis and abdominal aorta aneurysms (AAA). This case study evaluates a cadaver with an unusually large umbilical hernia. RESOURCES. An embalmed 66-year-old male cadaver (of one year) dissected over 8 months. The cause of death was cardiovascular accident. DESCRIPTION. Observation revealed ulnar drift (all fingers), hypermobile PIP joints (Swan neck deformities), bilateral MCP and ulnar styloid process enlargement, and multiple joint degenerative changes resembling rheumatoid arthritis. Additionally, the cadaver had bilateral total knee arthroplasties and a total shoulder arthroplasty. The cadaver was obese with a large 6"x5" umbilical hernia deviating laterally left. The intestines were strangulated within the hernia. Additionally, colon diverticulosis was present. A moderate abdominal aorta aneurysm and left ventricular hypertrophy were present. Rheumatoid arthritis effects on connective tissue (elastin and collagen) of joint structures is well known. Connective tissue changes were present in the abdominal wall, the gastrointestinal tract and heart. Although obesity is commonly associated with umbilical hernia, perhaps collagen abnormalities were causative. Association of varicose veins, umbilical, inguinal and hiatal hernias are associated with connective tissue changes. SIGNIFICANCE. Since a cadaver is a physical therapy student's first patient, the effects of connective tissue dysfunction can assist students' differential diagnosis skills examining multiple systems in the body. The presentation of a large umbilical hernia in a patient with a rheumatic arthritis resulted in critical thinking and encouraged differential diagnosis and an understanding of connective tissue dysfunction and pathophysiology of diseases.

SNYDER, Steven G.[1], Mathew WEDEL[2], and Jacqueline B. TRUONG[3]. [1]Department of Physical Therapy, Western University of Health Sciences, Pomona, CA, 91766, USA. [2]College of Osteopathic Medicine of the Pacific, Western University of Health Sciences, Pomona, CA, 91766, USA. [3]College of Podiatric Medicine, Western University of Health Sciences, Pomona, CA, 91766, USA
Description and Comparison of Bilateral Variations of the Soleus Accessorius Muscle in a Cadaver.

INTRODUCTION. The Soleus Accessorius muscle is a recognized anatomical variant. A bilateral variant of this muscle was discovered that had not previously been described in the literature. RESOURCES. Bilateral presentations of the accessory soleus muscle with variant attachments were discovered during the course of a standard cadaver dissection in PT5035 Physical Therapy Anatomy II course at Western University of Health Sciences. The subject was a 69-year-old male with COPD listed as cause of death. Anatomy faculty further dissected the variant muscles, documenting and photographing the lower limb and dissection process. DESCRIPTION. A poster presentation of descriptions of the two muscles, as well as photographs of the muscles in situ will be presented. Comparisons between the right and left muscles will be presented, as well as comparison of this cadaver's presentation to previously published descriptions of the accessory soleus muscle. SIGNIFICANCE. Anatomical variation in muscle morphology can impact both surgical and non-surgical medical treatments, as well as function of the living person. Asymmetrical muscle attachments of muscles in the lower limb can affect gait and function in the living person. Visual representations and descriptions of these variations can allow for alternative treatment considerations in living individuals.

continued on next page

TORRES, Cristian and Darren SALMI. Division of Clinical Anatomy, Department of Surgery, School of Medicine, Stanford University, Stanford, CA 94305, USA.
Thrombotic Events in Pulmonary Artery Conduits.

INTRODUCTION. Many infants are born with congenital heart conditions that compromise the blood flow to the lungs via the pulmonary arteries (PA). The use of artificial conduits to circumvent malformations has greatly reduced mortality rates in recent years. However, despite this improvement in overall patient outcome, conduits may become thrombosed and fail, which can lead to reoperation or even death. RESOURCES. Autopsy reports were searched for patients 4 weeks or older who had conduits implanted to aid in the pulmonary artery blood supply. A total of 37 autopsies were reviewed for primary and secondary diagnoses, conduit type, conduit duration, and whether thrombosis was present. DESCRIPTION. Data was analyzed to observe trends and prevalence in conduit types and thrombotic events. The most common heart conditions requiring artificial PA conduits were hypoplastic left heart syndrome (41%) and some form of heterotaxy (22%). The most common conduit types included right ventricle-to-PA conduit (38%) and Glenn shunt (28%). The overall rate of thrombus formation was 54% of which 60% were found in the artificial conduit. SIGNIFICANCE. Blood flow through the pulmonary artery is vital for life. There are many congenital conditions that require the insertion of artificial conduits to provide adequate blood flow through the PA that would otherwise lead to oxygenation deficiencies without the conduit. However, a conduit may result in the formation of a thrombus, often in the shunt itself, which can occlude blood flow and/or dislodge to become an embolus. Thrombosis of PA conduits remains a challenge for patients with a wide range of congenital heart defects regardless of conduit type.

VAN, Lang[1], Anthony HANG[1], Shireen SACHDEVA[1], and Mark MILLER[2]. [1]Lincoln Memorial University, Harrogate, TN, 37752, USA; [2]Department of Surgery, Methodist University Hospital, Memphis, TN, 38104, USA.
The Active Formation of a Cholecystogastric Fistula Secondary to Calculous Cholecystitis.

INTRODUCTION. Gallstone ileus is a rare complication of cholelithiasis due to gallstone erosion into the gastrointestinal tract via a biliary-enteric fistula. The gallstone most commonly lodges within the terminal ileum or ileocecal valve. We review a unique case of cholecystogastric fistula secondary to gallstone erosion. RESOURCES. This is a case report of an 85-year-old African American female presenting with 5 days of nausea, vomiting, abdominal pain, and diarrhea. Ultrasound and CT scans revealed non-visualization of the gallbladder, normal hepatic clearance, and no evidence of common bile duct obstruction. Gallbladder was without activity at 60 and 90 minutes. Surgery referral prompted a pre-operative diagnosis of "acute cholecystitis with cholelithiasis" and recommended cholecystectomy. During laparoscopic surgery, a 3 cm gallstone was found to be completely obstructing the cystic duct. A Mirrizzi-like syndrome was noted, in which a gallstone-impacted cystic duct externally compresses the common hepatic duct. Upon dissection, no distance was seen between the gallbladder and the common duct. An intraoperative cholangiogram showed a shortened cystic duct, and with this, the abdomen was opened through a midline incision. An opening at the cystic duct-common bile duct junction was enlarged to allow a 14 French T-tube to be placed and sewn into place. TISSEEL, a fibrin sealant, was used to seal around the T tube and gallbladder fossa. A T tube cholangiogram showed good filling of the biliary radicles and common bile duct. Next, the abdomen was irrigated, TISSEEL was placed, and the T tube was hooked to a bile bag and sewn into place. The patient was in good condition and tolerated the procedure well. DESCRIPTION. To highlight the presence of a rare type of cholecystoenteric fistula secondary to calculous cholecystitis. SIGNIFICANCE. Although rare, it is critical to consider gallstone ileus with cholecystogastric fistula when caring for patients with cholecystitis.

VAN, Lang[1], Hau LY[1], Suma NADIMPALLI[1], Jessica CANLAS[1], Cassandra ROBERTSON[1], and Mark MILLER[2]. [1]Lincoln Memorial University, Harrogate, TN, 37752, USA; [2]Department of Surgery, Methodist University Hospital, Memphis, TN, 38104, USA.
Amyand Hernia Complicated by Appendicitis and Necrotizing Fasciitis.

INTRODUCTION. An Amyand hernia is a rare type of inguinal hernia in which the appendix displaces into the hernia sac. This abnormality predisposes the appendix to obstruction, inflammation, and perforation. We review a case involving an Amyand hernia complicated by appendicitis and necrotizing fasciitis. RESOURCES. This is a report of a 66-year-old Caucasian male presenting with fever, hematuria, and pain in the right lower abdomen and inguinal region. His past medical history was significant for hypertension, previous inguinal hernia repair, and recent removal of a scrotal mass. CT scans confirmed the presence of necrotic scrotal tissue and a recurrent inguinal hernia containing peritoneal contents, including the appendix. The patient was quickly transferred to the operating room. During surgery, the scrotum was incised and debrided of necrotic tissue. The right testicle was mobilized, the spermatic cord was ligated and divided, and the radical orchiectomy was completed. Once the Amyand hernia was identified, the adhesions that connected the appendix to the

continued on next page

sac were lysed, and the appendix was retracted from the hernia sac. The appendix was separated from the mesoappendix, ligated at the appendiceal base, and sent for pathological assessment. The hernia sac was further debrided. A purse-string suture was then placed and inverted. Next, a Cooper ligament repair was performed with interrupted Prolene sutures to close the myopectineal orifice. The scrotum and groin were irrigated, and a drain was placed in the scrotal defect through a stab incision. Lastly, the incisions were closed, and dressings were applied. The patient was brought to the recovery room in good condition. DESCRIPTION. To highlight a case involving an Amyand hernia complicated by appendicitis and necrotizing fasciitis. SIGNIFICANCE. Considering Amyand hernias when caring for patients with inguinal hernias can lead to earlier diagnoses, decreased complications, and better patient outcomes.

YARNELL, Jocilyn R., Allison L. PICKRON, and Philip A. FABRIZIO. Department of Physical Therapy, Philadelphia College of Osteopathic Medicine-Georgia, Suwanee, GA, 30024, USA.
Frequency and Variation of the Iliocapsularis Muscle.

INTRODUCTION. Iliocapsularis is a variation of the iliacus muscle reported as originating from the ASIS and inserting into the lesser trochanter of the femur. While the function of this muscle is undecided, it has been hypothesized to be a dynamic stabilizer of the hip. RESOURCES. Twenty-four cadaveric hips were dissected at Philadelphia College of Osteopathic Medicine-GA Campus' Anatomy Lab. To preserve any possible iliocapsularis muscles, the dissection was performed with a lateral-medial incision from one inch above the ASIS across the iliac fossa cutting both the iliacus and psoas. The inferior portion of the iliacus and psoas muscles were reflected from the ilium allowing access to the hip joint capsule. DESCRIPTION. Of the twenty-four hips dissected only three iliocapsularis muscles were discovered. Each iliocapsularis was positioned under the iliopsoas within a separate fascial compartment from the iliacus muscle. The attachments of two of the iliocapsularis muscles were not consistent with the documented literature. Variation one originated from between the ASIS and AIIS, blended into the iliacus muscle, and inserted into the lesser trochanter of the femur. Variation two originated from the ilium inferior and medial to the ASIS and bifurcated into two bands with the lateral band inserting into the vastus intermedius muscle and the medial band inserting into the shaft of the femur and lesser trochanter. SIGNIFICANCE. Finding three iliocapsularis muscles out of twenty-four hips confirm that this muscle is not a commonality in all individuals, contradicting literature declaring it as such. Knowledge of hip anatomical variations can be helpful in differential diagnosis of anterior hip dysfunctions. Since dynamic hip stabilization will be altered in the presence or absence of the iliocapsularis muscle, as well as by variations in origin, insertion and line of pull of this muscle; the iliocapsularis should be considered when assessing hip stability.

Abstracts – Poster Presentations Session 2

(Listed by presenting author last name)

AVILA, Jessica A.[1], Johan S. VALCARCEL[2], and Thomas R. GEST[3]. [1]Paul L. Foster School of Medicine, Texas Tech University Health Sciences Center El Paso, El Paso, TX, 79905, USA; [2]University of Texas at El Paso, El Paso, TX, 79968, USA; [3]College of Medicine, Central Michigan University, Mount Pleasant, MI, 48859, USA.
Anatomical Variations of the Hypoglossal Nerve, the Vagus Nerve, and the C1 and C2 Ventral Rami.

INTRODUCTION. The hypoglossal nerve (CN XII) exits the base of the skull through the hypoglossal canal where it joins branches from the C1 ventral rami and fibrously joins the vagus nerve. Below the C1/C2 vertebral level, CN XII breaks away from vagus and travels inferiorly between the internal carotid artery and the internal jugular vein. This study aims to determine the anatomical pattern of connections between CN XII, the vagus nerve, and C1 and C2 ventral rami. METHODS. CN XII was grossly dissected posterior to the angle of the mandible and followed superiorly to the external opening of the hypoglossal canal in 9 formalin-fixed adult cadaveric heads. The specimens consisted of 3 men and 6 women. Specimen age ranged from 60 to 93. SUMMARY. On all 9 sides, CN XII, the vagus nerve, and C1 and C2 ventral rami were identified and preserved. In 5 of the 9 specimens, a common fiber of both the C1 and C2 ventral rami attached to the back of the fibrous fusion of CN XII and the vagus nerve; in one of the specimens an additional branch was seen from the union of the C1/C2 attaching to the union of the C3/C4 ventral rami. In another body, the C1, C2, and C3 ventral rami joined to a single fiber and connected with the vagus and CN XII fibrous fusion. In another, the C1 ventral rami connected to the vagus and CN XII fusion independently and a small branch from C1 connected to the union of the C2 and C3 ventral rami. In another, C1 and C2 both attached to the vagus and CN XII fusion individually at their own levels. In the last body, C1 and C2 joined to a common fiber and attached to CN XII superior to the vagus and CN XII fusion. No specimens had previous dissection in the area. CONCLUSIONS. Many anatomical variations of this area exist. The most commonly observed was C1/C2 ventral rami union joining to the fibrous fusion of CN XII and vagus nerves. Further studies need to be done with larger sample sizes to determine the prevalence of the less common anatomical various.

continued on next page

BAEZ, Ramona[1], Bedia CASTELLANOS[1], and Eric BAKER[2]. [1]Department of Anatomy, Touro College of Osteopathic Medicine, New York, NY, 10027, USA. [2]Department of Basic Science and Craniofacial Biology, College of Dentistry, New York University, New York, NY, 10010. USA.

Unusual Bilateral Accessory Flexor Digiti Minimi Brevis Muscle.

INTRODUCTION. The hypothenar group of muscles of the hand consist of the abductor digiti minimi, flexor digiti minimi brevis and the opponens digiti minimi. Our case consists of a bilateral accessory digiti minimi brevis muscle. RESOURCES. Bilateral dissection of the upper limbs in a 74-year-old Caucasian male donor. DESCRIPTION. During routine anatomy lab dissection of the upper limbs and upon reflection of the antebrachial fascia, we noticed an unusual muscle belly of the flexor digiti minimi muscle originating within the flexor compartment of the forearm attached proximally to the medial intercompartmental septum. It then passed through the Guyon's Canal and sent a muscle slip to the pisiform bone, before continuing down on the medial side of the flexor digiti minimi brevis with which it shared the distal attachment to the base of the proximal phalanx of the fifth digit. Hyperflexion of the metacarpo-phalangeal and proximal interphalangeal joints of the fifth and fourth digits were very noticeable especially on the left upper limb of the donor. SIGNIFICANCE. Detailed knowledge of the anatomy and function of the hand is important to diagnose and treat the array of variations and pathologies that could affect the hypothenar region. Compression of the ulnar nerve and artery in the Guyon's canal due to an accessory flexor digiti minimi brevis muscle can lead to affection of the ulnar nerve sensory and motor functions as well as arterial thrombosis and deficits that can lead to ischemic episodes and pain. Claw finger deformity of the fifth and fourth digits should be ruled out from other similar conditions like Volkmann's ischemic contracture, Dupuytren's contracture, and spastic hand besides other conditions.

BAEZ, Ramona, Lizbeth L. ZAMBRANO, and Aura M. AMOROS. Department of Anatomy, Touro College of Osteopathic Medicine, New York, NY, 10027, USA.

Aberrant Formation and Communication to the Median Nerve and Unusual Subscapular Artery Branching.

INTRODUCTION. The neurovasculature of the upper limb can demonstrate plasticity such that it can differ in vascular flow patterns and innervation distributions. The presence of an unusual formation and communicating branches to the median nerve as well as an aberrant trunk arising from the third portion of the axillary artery provides clinical and surgical importance. RESOURCES. Dissection of the upper limb of an embalm 80-year-old female Caucasian donor was performed in the anatomy lab of Touro College in NYC, Harlem Campus and the findings were documented and photograph. DESCRIPTION. After exposition of the structures of the left upper limb, the median nerve was formed solely by an upper and lower medial root of the median nerve (MRMN). The lateral cord sends a communicating branch to the upper MRMN before continuing as the musculocutaneous nerve (MCN). The MCN sends a communicating branch to the median nerve half way of the arm before continuing in the lateral aspect of the forearm as the lateral antebrachial cutaneous nerve. The third part of the axillary artery give rise to a common subscapular trunk before dividing into the lateral thoracic, thoracodorsal, circumflex scapular and posterior circumflex humeral arteries. SIGNIFICANCE. The existence of communicating branches and variations to the median nerve and aberration of the arterial patterns may provide importance of unexplained sensory loss after trauma, surgical interventions, or from arterial compression in an area of the upper limb.

D'ANTONI, Anthony V.[1], Carlos A. G. MACHADO[2], Jimmy XIA[1], R. Shane TUBBS[3,4], Marios LOUKAS[4], Douglas N. MINTZ[5], Sushil KUMAR[1], Ritwik BAIDYA[1], Santosh K. SANGARI[1], and Estomih P. MTUI[1]. [1]Division of Anatomy, Department of Radiology, Weill Cornell Medicine, New York, NY, 10065, USA; [2]Medical Illustrator, Austin, TX, 78759, USA; [3]Seattle Science Foundation, Seattle, WA, 98122, USA; [4]Department of Anatomical Sciences, St. George's University, Grenada; [5]Department of Radiology and Imaging, Hospital for Special Surgery, New York, NY, 10021, USA.

Triangular Fibrocartilage Complex: An Anatomical, Radiological and Medical Illustration Study.

INTRODUCTION. There is no formal anatomico-clinical consensus on the structures that form the triangular fibrocartilage complex (TFCC). Most atlases do not have accurate illustrations of the TFCC and its articular disc (AD). Our purpose was to study the TFCC and AD morphometry via dissection, histology and imaging. Dissection photographs, micrographs, biofidelic plastic models of ADs, and magnetic resonance (MR) images were sent to a medical illustrator. METHODS. Fifty-eight ADs from thirty-four (N=34) embalmed cadavers (20 females, 14 males) with mean age at death of 78.69 years (range 52-98) were removed. The length, width and thickness at five standardized points was measured for each AD. One TFCC was sectioned and stained with modified Masson's trichrome. Biofidelic models of ADs were fabricated and MR images of TFCC obtained. Descriptive and inferential statistics, including correlations, were calculated using STATA 15.1 (p-value<0.05 was significant). SUMMARY. For the entire sample, mean (SD) length and width of left ADs were 18.09 (3.17) and 9.60 (3.02) mm, respectively.

continued on next page

Mean (SD) thickness of anterior, posterior, medial, lateral and center of left ADs were 3.32 (1.96), 2.32 (0.96), 2.40 (1.33), 1.03 (0.71) and 1.97 (0.82) mm, respectively. For the entire sample, mean (SD) length and width of right ADs were 18.63 (3.81) and 9.93 (2.70) mm, respectively. Mean (SD) thickness of anterior, posterior, medial, lateral and center of right ADs were 3.61 (2.22), 2.78 (1.26), 2.70 (1.19), 0.89 (0.49) and 2.00 (1.07) mm, respectively. No significant differences were found between corresponding right and left AD measurements. There were significant differences between female and male ADs. The AD has a complex triangular and biconcave shape with a transition zone (bone to hyaline cartilage to fibrocartilage). CONCLUSIONS. Data were analyzed and a medical illustrator created novel illustrations that clarify the structures that form the TFCC and help illuminate its anatomy.

DOWNIE, Sherry A.[1,2], Carly R. BASS[1], Sharon J. GALPERIN[1], Samir ZAMAN[1], Fernando S. GONZALEZ[1], and Priti L. MISHALL[1,3]. [1]Department of Anatomy and Structural Biology, Albert Einstein College of Medicine, Bronx, NY, 10461, USA; [2]Department of Physical Medicine and Rehabilitation, Albert Einstein College of Medicine, Bronx, NY, 10461, USA; [3]Department of Ophthalmology and Visual Sciences, Albert Einstein College of Medicine, Bronx, NY, 10461, USA.
Multiple Bilateral Variations in Lumbricals, FDS and FDP: Could this Affect Hand Function?

INTRODUCTION. The intrinsic muscles of the hand facilitate precision movements integral to human behaviors. The flexor digitorum superficialis (FDS) and flexor digitorum profundus (FDP) produce flexion of the interphalangeal joints of the medial four digits. The lumbricals flex metacarpalphalangeal joints and extend the interphalangeal joints, thus linking the flexor system to the extensor system of the hand. Variations in these muscles may impact hand functionality. RESOURCES. During routine dissection of a 70-year-old female cadaver, we observed bilateral variations in the lumbricals, FDS, and FDP muscles. A literature search was performed and results support the hypothesis that these variations are rare and will be of interest to both clinicians and anatomists. DESCRIPTION. The left 1st lumbrical was duplicated. The anomalous belly (AB) ran volar and parallel to the typical belly (TB) and arose from a long tendon derived from the FDS. The tendon travelled through the carpal tunnel and median nerve compression was evident. The TB arose from the appropriate FDP tendon and was joined by the AB just proximal to its insertion on the extensor expansion. Each belly was the size of a typical first lumbrical. Bilaterally: the 4th lumbricals were absent; the FDS tendons to the 5th digits were hypoplastic; the FDP tendons to the 4th and 5th digits arose from a common tendon that split at the base of the web space; and the FDS muscle belly extended distally into the carpal tunnel. SIGNIFICANCE. The lumbricals, FDS, and FDP are essential to normal function of the hand. Their absence or underdevelopment may render the affected digits less functional. Extra muscles and tendons in the palm of the hand or the carpal tunnel might lead to compression of adjacent structures, e.g. median nerve. We report a rare and complex constellation of findings in the forearm and hand that is of both academic and clinical interest.

EZRA, David[1], Lyman JELLEMA[2], Yelena STUKALIN[3], and Viviane SLON[4]. [1]School of Nursing Science, Tel Aviv Jaffo Academic College, 6818211, Israel. [2]Department of Physical Anthropology Natural History Museum, Cleveland, Ohio, 44106, United States. [3]Statistics Education Unit, Tel Aviv Jaffo Academic College, 6818211, Israel. [4]Department of Anatomy and Anthropology, Sackler Faculty of Medicine, Tel-Aviv University, Tel Aviv, 69978, Israel.
Diffuse Idiopathic Skeletal Hyperostosis (DISH) in the Cervical Vertebrae Vertebral Bodies (C3-C7).

INTRODUCTION. Diffuse idiopathic skeletal hyperostosis (DISH) is a form of arthritis that involves the tendons and ligaments around the spine. Also, known as Forestier's disease, this condition occurs when these tendons and ligaments become hardened, a process known as calcification. Once the tendons and ligaments harden, parts of these tissues can turn into bone. This usually occurs where the tissue connects with the bone. As a result, bone spurs develop, which is an outgrowth of bone that develop along the edges of a bone. DISH commonly affects the spine. METHODS. The study population was sampled from the collection of human skeletons housed in the Natural History Museum in Cleveland, Ohio, USA. The sample included 2779 individuals, which divided to European-Americans and African-Americans, Gender and Age groups. A grading system for DISH in the segments of motion (SOM) was developed to assess the presence and severity of the phenomenon in each segment. Three categories of DISH were defined, as follows: Grade 1: One SOM with DISH. Grade 2: Two SOM with DISH Grade 3: Three and more SOM with DISH. SUMMARY. The highest SOM with DISH grade 1 was found in the levels C2-C3 and C3-C4; in grade 2 the highest SOM with DISH was found in C5-C7; Males and European-American manifest higher DISH frequencies. We assumed that the location of the DISH is probably for two reasons: 1. SOM C2-C3 and C3-C4 are located at the beginning of the cervical lordosis which can cause compression. 2. C5-C7 SOM located in the pick of the cervical lordosis and in the end so there are two major forces compression and tension forces. CONCLUSIONS. The compression and tension on the SOM's C2-C3, C3-C4 and C5-C7 is the mechanical reason for the DISH phenomena in those cervical spine sites.

continued on next page

HALES, Hannah, Tiffany CHAMBERS, Sara MICHIE, and Darren SALMI. Department of Surgery, School of Medicine, Stanford University, CA, 94305, USA.
Case Report: Anatomical Abnormalities seen in the Epiglottis of a Cystic Fibrosis Patient.

INTRODUCTION. Anatomical variations of the epiglottis are rare. Congenital laryngeal anomalies like aplastic, hypoplastic and bifid epiglottides, have been reported, and are often associated with digestive/respiratory complications. However, there are no recorded cases of an epiglottis with focally absent cartilage. The present study describes the histological and pathological characteristics of this rare structure/condition. RESOURCES. This anomaly was discovered incidentally during autopsy. Histologic tissue analysis was performed. DESCRIPTION. A twenty-seven-year-old patient with cystic fibrosis and end-stage lung disease was observed to have an epiglottis with a thin and transparent mid-portion. The histological analysis showed the region lacking elastic cartilage contained bland connective tissue surrounded by normal stratified squamous epithelial layers. The larynx was otherwise normal. The trachea and bronchi contained thick mucus, and the lungs showed classic pathologic changes of cystic fibrosis. SIGNIFICANCE. An epiglottis with focally absent cartilage has not previously been reported. Patients with abnormalities of the epiglottis are expected to have problems with airway, aspiration and feeding, however this was not reported for this patient. While the primary symptoms of cystic fibrosis are classically respiratory/pancreatic abnormalities, other structural abnormalities may occur, such as absent/underdeveloped vas deferens. Similarly, the etiology of this patient's focally absent epiglottic cartilage may be related to cystic fibrosis.

JOHNSTON, Mai-Lan, Ellis KELLY, Zhi LI, Nancy McKEE, and Anne M.R. AGUR. Division of Anatomy, Department of Surgery, University of Toronto, Toronto, ON, M5S 1A8, Canada.
Intramuscular Aponeuroses and Fibre Bundle Morphology of Flexor Digitorum Superficialis: A 3D Study.

INTRODUCTION. The flexor digitorum superficialis (FDS) has important functional implications for the flexion of the 2nd -5th digits. However, no studies were found that examined the fibre bundle (FB) attachments to aponeuroses. For development of targeted treatment techniques for strain injuries, a detailed knowledge of musculoaponeurotic arrangement is required. The purpose of this study was to investigate the 3D musculoaponeurotic architecture of FDS to determine the location and extent of aponeuroses, tendons, and FB attachment sites for each belly. METHODS. The musculotendinous elements of FDS were serially dissected and digitized (MicroScribe® Digitizer) in 7 embalmed specimens. The data were reconstructed into 3D models (Autodesk® Maya®) that were used to visualize, document, and compare the spatial relationships of the aponeuroses and FB attachment sites of bellies of FDS. SUMMARY. FDS consisted of 4 digital bellies and a proximal belly. The muscle bellies originated from intramuscular aponeuroses: 1) a triangular proximal aponeurosis extending from the medial epicondyle into the superior 1/3 of the forearm, providing attachment for the proximal belly; 2) a distal aponeurosis on the deep surface of the 3rd digital belly, continuous with the tendon of the 3rd digit; 3) a long aponeurosis on the medial aspect of the 2nd digital belly spanning from the medial epicondyle proximally and continuous distally with the digital tendon. The 4th digital belly was most superficial, attaching to aponeuroses 1 and 3 proximally, and to the 4th digital tendon distally. The FBs of the 5th digital belly originated from aponeurosis 3, distal to the 4th digital belly. CONCLUSION. The results suggest that each of the bellies of FDS has a complex musculoaponeurotic core for FB attachment. Functionally, aponeuroses are an important component of force transmission to terminal tendons, however their location and role is poorly understood and requires further investigation.

KUMAR, Sushil, Ritwik BAIDYA, Anthony V. D'ANTONI, Santosh K. SANGARI, and Estomih P. MTUI. Division of Anatomy, Department of Radiology, Weill Cornell Medicine, New York, NY, 10065, USA.
Variations of Vertebral Artery and Suboccipital Artery of Salmon: Hypothesis-Generated Case Report.

INTRODUCTION. The vertebral artery (VA) is divided into four segments. Segment V1 originates from the subclavian artery (SA) to first enter the transverse foramen of the C6 vertebra. Segment V2 ascends the remaining transverse foramina, ultimately traversing the transverse foramen of the atlas. Segment V3, found in the suboccipital triangle, courses posteromedially around the lateral mass and lies in a groove on the posterior arch of the atlas, eventually traveling beneath the posterior atlanto-occipital membrane. Intracranially, segment V4 courses from its entrance into the dura mater to its union with the opposite VA to form the basilar artery. As it ascends, the VA gives off different branches. Any muscular branch that specifically arises from segment V3 is called the suboccipital artery of Salmon. RESOURCES. An embalmed male donor who died at age 72 was dissected during an anatomy course. DESCRIPTION. We observed no variations of the right VA. Regarding the left VA, segment V1 originated from the arch of the aorta instead of the SA (occurs in 5-8% of people) and first entered the transverse foramen of the C5 vertebra instead of the C6 vertebra (occurs in 5% of people). Segment

continued on next page

V1 measured 94.54 mm. Segment V2 ascended the cervical spine from the transverse foramen of the C5 vertebra to the transverse foramen of the atlas. Segment V3 in the suboccipital triangle contained two separate and distinct suboccipital arteries of Salmon (occurs in 20-67% of people). Segment V4 had the usual intracranial arrangement. SIGNIFICANCE. We observed three variations of the left VA: (1) origin from the arch of the aorta, (2) first entering the C5 vertebra, and (3) two suboccipital arteries of Salmon. Because the combination of these three congenital arterial variations is very rare and to our knowledge has never been explored, we hypothesize that there might be a relationship between them. Further studies are needed.

LEBRON, Bryan, Steven ORELLANA, Daniel MILLER, Ezra PLEETER, and Ramona BAEZ. Touro College of Osteopathic Medicine, New York, NY, 10027, USA.
Unusual Accessory Abductor Pollicis Longus Muscle.

INTRODUCTION. The abductor pollicis longus, extensor pollicis brevis, extensor pollicis longus, extensor indicis and the supinator muscles form the deep group of muscles in the posterior compartment of the forearm. The abductor pollicis longus originates on the posterior surface of the radius, ulna and interosseous membrane and attaches distally at the base of the first metacarpal. This abstract reports an accessory abductor pollicis longus arising from the supracondylar ridge with a distal insertion at the base of the first metacarpal bone. RESOURCES. Bilateral dissection of the upper limb of a 94-year old Caucasian female cadaver. DESCRIPTION. During routine dissection of the upper limb and upon exposition of the right forearm and hand, we discovered an accessory pollicis longus muscle with a muscle belly originating from the extensor carpi radialis longus coming off the supracondylar ridge and with a distal attachment to the base of the first metacarpal bone. SIGNIFICANCE. Variations of abductor pollicis longus muscle are an uncommon and rare anatomical anomaly. Its knowledge is of high significance for clinicians, radiologists and surgeons during diagnosis, clinical approach as well as in surgical procedures such as tendon transplant and reconstructive surgery. Furthermore, it expands our insight of the upper limb musculoskeletal system and its variations.

LOPEZ-OJEDA, Wilfredo. Department of Foundational Science, Kaiser Permanente School of Medicine, Pasadena, CA, 91101, USA.
The Cranial Nerve Zero (CN0) and Kallmann Syndrome (KS).

INTRODUCTION. Despite the overabundance of literature describing the traditional 12 pairs of cranial nerves, very little has been documented on the seemingly innocuous nerve known as the cranial pair zero (0). RESOURCES. A thorough review was performed across the cranial nerves and medical literature. Remarkably, the so-called cranial nerve 0 (CN0) remains greatly unspoken among the medical written works, particularly because most anatomy and medical books have overlooked its presence in the human brains. However, many elegant works have been published over the last hundred years describing the CNO's embryology, histology, neurophysiology and even its clinical significance. DESCRIPTION. The enigmatic pair 0 neurons are functionally linked to gonadotropin-releasing hormone (GnRH), suggesting a pivotal role in the regulation of human reproductive functions and behaviors. Reports point to a function in the unconscious perception of special odorants regulating human autonomic and reproductive behaviors via the ubiquitous hypothalamic-pituitary-gonadal axis (HPG). SIGNIFICANCE. Clinically, these nerves may trigger neuroendocrine responses, independently or together with other brain circuits, such as the kisspeptin neural circuit. Alterations of these neural connections may cause Kallmann syndrome (KS), a compelling genetic disorder characterized by hypogonadotropic hypogonadism (HH) that manifests with hypo- or anosmia, among other clinical implications. However, this important neuroscience clinical correlation is not discussed in most medical titles, nor is currently integrated into the anatomy teachings of medical curricula. Given its medical significance, we propose that the cranial pair zero is included in medical textbooks and is suitably integrated into clinical cases for undergraduate medical education.

continued on next page

MAREK, Tomas[1], Mark A. MAHAN[2], Kimberly K. AMRAMI[3] and Robert J. SPINNER[1]. [1]Department of Neurologic Surgery, Mayo Clinic, Rochester, MN, 55905, USA. [2]Department of Neurologic Surgery, University of Utah, Salt Lake City, Utah 84132, USA. [3]Department of Radiology, Mayo Clinic, Rochester, MN 55905, USA.

Lipomatosis of Nerve and Nerve-territory Overgrowth.

INTRODUCTION. Lipomatosis of nerve (LN) is a part of a spectrum of adipose lesions affecting peripheral nerves which also includes intra and extraneural lipomas. LN is characterized by abundant proliferation of fibro-adipose tissue within the epineurium. MRI features of this pathology are pathognomonic and obviate the need to perform diagnostic biopsy. It has been known that nerve-territory overgrowth can be associated with LN, however not many studies has been done on this topic. Our aim was to compile the world's literature on LN to better understand this pathology. METHODS. PubMed and Google Scholar databases were searched to identify papers of LN in any language. A variety of terms was queried including: lipomatosis of nerve, fibrolipomatous hamartoma, macrodystrophia lipomatosa and others. Papers were sorted into 2 groups: 1) definite LN cases and 2) probable LN cases (cases demonstrating features of LN – e.g., nerve-territory overgrowth – however lacking definite proof of nerve involvement). SUMMARY. The initial search yielded 2465 articles. After all exclusions, 281 articles reporting cases of LN with definite proof and 120 articles of probable LN cases were identified. We gathered 618 definite LN cases and 407 probable LN cases. The nerve most commonly affected was median (n=391) followed by plantar (n=69) and ulnar nerves (n=34). Nerve-territory overgrowth was found to be present in 62% of LN cases (78% when definite and probable LN cases were combined). All cases except for 5 were within the nerve-territory of the affected nerve. CONCLUSIONS. Our work strengthens the association of LN and nerve-territory overgrowth. We believe that all LN cases with nerve-territory overgrowth can be explained using knowledge of clinical anatomy. Even the 5 outlier cases can be explained by clinical anatomy.

MILLARD, Jonathan A., Aaron W. BEGER, and Jalen HAMMONDS. Department of Anatomy, DeBusk College of Osteopathic Medicine, Lincoln Memorial University, Harrogate, TN, 37752, USA.

Posterior Auricular Muscle - A Morphometric Analysis.

INTRODUCTION. The posterior auricular muscle arises from the mastoid process of the temporal bone and inserts onto the concha of the ear. It acts to retract the pinna, drawing the external ear posterosuperiorly. It has been shown that aberrant insertion of the muscle has a positive relationship with aesthetically undesirable ear protrusion. Contemporary plastic surgery techniques report utilizing the muscle as a landmark for conchomastoid suture placement. Complete transposition of the muscle during otoplasty has also been reported. The purpose of this study is to perform a morphometric analysis of the posterior auricularis muscle, as well as evaluate the muscle with respect to demographics. METHODS. Fourteen formalin-fixed cadavers (six males, eight females) were dissected bilaterally to completely expose the posterior auricular muscle. The height of each specimen was measured from the base of the heel to the vertex of the skull. The width and length of each muscle was measured (Neiko electronic Vernier calipers 01407A). Data were analyzed with SPSS. SUMMARY. The bilateral presence of each muscle was confirmed as 100% (N=28). The muscle presented as two slips in 6 out of 28 cases (21.4%). The average muscle width was 8.97 mm (SD= 2.28 mm, Min.- 5.76 mm Max.- 12.67 mm). The average muscle length was 29.20 mm (SD= 6.01 mm, Min.- 18.62 mm Max.- 40.06 mm). Insignificant correlations were found between specimen height and mean muscle width and length (r=-.078, N=14, p=.791; r=.036, N=14, p=.036, respectively). Insignificant correlations were found between specimen sex and mean muscle width and length (r=-.331, N=14, p=.248; r=.081, N=14, p=.784, respectively). CONCLUSIONS. Interestingly, the data showed no significant correlation between muscle morphometrics and cadaver height or gender. The unpredictability of the muscle's form and its significant variability in width and length should be considered when performing a translocation of the muscle.

MISHALL, Priti L.[1,2], Anthony MA[1], Carolyn E. MILLER[1], Taylor L. MUSTAPICH[1], Jerryl P. ABRAHAM[1], Jinsung KIM[1] and Sherry A. DOWNIE[1,3]. [1]Department of Anatomy and Structural Biology, Albert Einstein College of Medicine, Bronx, NY, 10461, USA; [2]Department of Ophthalmology and Visual Sciences, Albert Einstein College of Medicine, Bronx, NY, 10461, USA; [3]Department of Physical Medicine and Rehabilitation, Albert Einstein College of Medicine, Bronx, NY, 10461, USA.

Pointing in a Different Direction: A Case of Bilateral Absence of Extensor Indices.

INTRODUCTION. A thorough knowledge of the arrangement of tendons on the dorsum of the hand is essential when performing surgical procedures for tendon repair or tendon transfer on the hand. A number of extensor muscle and tendon variations have been reported in the literature including duplication or triplication, as well as absence of the extensor muscles and tendons, especially the extensor indices muscles and tendons. RESOURCES. During routine dissection in an 83-year-old male cadaver, students observed bilateral absence of the extensor indices muscles and tendons in both the upper limbs. DESCRIPTION. The dorsum of the index finger received only one tendon. Further, dissection confirmed that only three muscles arose from the posterior surface of the radius, ulna and interosseous membrane - extensor pollicis longus

continued on next page

and brevis, and abductor pollicis longus, further confirming that the extensor indicis muscle was absent on both upper limbs. SIGNIFICANCE. Extension of the index finger is performed through the action of extensor indicis and/or the extensor digitorum. However, extension of the index finger when the hand is fisted is compromised in the absence of extensor indicis as the tendons of extensor digitorum are linked by oblique intertendinous connections that restrict independent extension of the fingers. The incidence of this anatomical variant ranges from 0 to 4%.. This report highlights the importance of obtaining a pre-operative ultrasound scan to confirm the presence of two extensor tendons to the index finger when planning tendon transfer procedures utilizing extensor indicis. In cases when only one extensor tendon to the index finger is identified, an alternate graft source must be found (e.g. palmaris longus).

PUGH, Kristy R., Lorreen A. AGANDI, Samuel A. TISHERMAN, and Adam C. PUCHE. University of Maryland School of Medicine, Baltimore, MD, 21201, USA.
Landmark Identification & Compartment Decompression in Performance of Upper Extremity Fasciotomy.

INTRODUCTION. Compartment syndrome of the forearm is a condition that can occur after a fracture, traumatic vascular injury or prolonged ischemia. This condition can threaten preservation of the limb and potentially the life of the patient, necessitating surgical treatment with an upper extremity fasciotomy (UEF). In surgeons who had undergone advanced training (ASSET, Advanced Surgical Skills for Exposure in Trauma course by the American College of Surgeons) we measured their knowledge of key UEF landmarks and compartment/constriction decompression. METHODS. For this analysis, 12 ASSET-trained surgeons were recruited without advanced knowledge of which procedures from the ASSET course they would be asked to perform. They were instructed to mark the surface landmarks and to perform a UEF on an embalmed cadaver. We assessed identification of the 9 major anatomical landmarks and decompression of the 6 compartments/constrictions. SUMMARY. The radius and the wrist crease were the two most commonly identified landmarks among the participants, with a score of 50% and 46%, respectively. The medial border of the thenar eminence and the mobile wad, were the least identified by only 8% of participants. The dorsal compartment was most the commonly decompressed compartment with a score of 54% whereas the bicipital aponeurosis was only released by 17% of participants. CONCLUSIONS. The results show a large percentage of surgeons do not identify the key landmarks or decompress all the compartments during UEF. This study indicates absence of knowledge, or deterioration of recollection, of the landmarks and compartments needed for successful UEF. This suggests additional or refresher training may be needed to maintain currency in this trauma procedure.(Sponsored by Department of Defense W81XWH-17-2-0011.)

REITHERMAN, Danielle E., Jill SCHULDT, Anthony M. IUSO, and Ramona BAEZ. Touro College of Osteopathic Medicine, New York City, NY, 10027, USA.
Aberrant Branching of Axillary Artery and Median Nerve, and Accessory Flexor Pollicis Longus Muscle.

INTRODUCTION. The median nerve is the primary supply to the anterior forearm and does not usually communicate with the musculocutaneous nerve. The normal action of the flexor pollicis longus (FPL) is to flex the thumb, while the flexor digitorum superficialis (FDS) acts on the other four digits. The third part of the axillary artery gives rise to the subscapular, anterior and posterior circumflex humeral arteries before continuing as the brachial artery (BA). RESOURCES. Bilateral dissection of the upper limb of an 85-year-old Caucasian female donor. DESCRIPTION. During dissection of the left upper limb, we discovered that the anterolateral aspect of the median nerve gave rise to a communicating fiber with the musculocutaneous nerve. Further dissection revealed a muscle belly at the medial aspect of the antecubital fossa, deep to the pronator teres, originating on the FDS and attaching distally on the medial surface of the FPL. Lastly, the third part of the axillary artery exhibits an aberrant branching pattern. The superficial BA courses anterior to the median nerve, giving muscular branches to the anterior compartment of the arm, and descending to the antecubital fossa where it divides as expected. The deep BA courses posterior to the median nerve as a trunk which divides into two branches; a deep BA and the subscapular artery. The deep BA gives off two anterior circumflex humeral arteries before continuing in the medial aspect of the arm where it branches into the profunda brachii, and superior and inferior ulnar collateral arteries. The subscapular artery gives off the posterior circumflex humeral and circumflex scapular before continuing as the thoracodorsal. SIGNIFICANCE. The contraction of the FDS is likely causing thumb flexion, influencing the fine movements of the hand. The neurovascular anomalies are important regarding potential sources of compression, delineation of graft sites, and avoiding injury during medical procedures.

continued on next page

ROSENOW, Mica J., and Alla G. BARRY. Department of Biology, Missouri Southern State University, Joplin, MO, 64801, USA.
Anatomic and Histologic Investigations of Brachial Plexus Variations.

INTRODUCTION. Brachial plexus variations are common and extensively studied. Variations can cause alteration of signal velocity during electromyography. Viewed mostly benign outside the surgical suite, specific variations can show inconsistent clinical presentation, and cause prolonged symptoms after routine surgical procedures of the upper limb. Further investigations into the brachial plexus and variation compositions are needed to individualize treatment protocols in sports medicine, pain management, massage therapy, physical therapy, and osteopathic medicine. RESOURCES. Routine dissection of fourteen embalmed cadavers was performed in the Missouri Southern State University human dissection laboratory. DESCRIPTION. Brachial plexus anatomy was documented. Variation sites were analyzed microscopically by H&E staining to determine nerve fiber type. Microdissection was completed of variated brachial plexuses to further elucidate pathways of individual fascicles from roots to branches. Modified Sihler's stain was completed on a double innervated coracobrachialis muscle to visualize the distribution of the nerves. SIGNIFICANCE. Brachial plexus variations play an important part in anesthetic placement for surgical intervention, ambiguous symptomology in the clinical setting, varied signal velocity in electromyography, and decreased treatment efficacy. Continued inquiry into the prevalence and composition of brachial plexus variations is required to assess the extent of impact on biomechanics and pain perception, and to provide individualized manual therapy treatments.

RUTYNA, Jessica, Bedia CASTELLANOS, Naveen Babu KANDAVALLI, Poonit MEHTA, Peter NELSON, Samantha OKUNDIA, Dominique PEAN, Ethan YOUSSEFZADEH, Taylor CHARTER, and Ashley COVATTO. Department of Anatomy, Touro College of Osteopathic Medicine, New York, NY, 10027, USA.
High-Origin Radial Artery Arising from the Thoracoacromial Artery.

INTRODUCTION. Variations in the anatomical origin of the radial artery are frequently reported in anomalous arterial patterns of the upper limb. In our case, we report a unilateral high-origin radial artery arising from thoracoacromial artery in the right upper limb. RESOURCES. During a routine dissection of a 90-year-old Caucasian female, a rare variant branch originating from the thoracoacromial artery was discovered. The branching pattern is further traced carefully through the brachium and antebrachium. DESCRIPTION. The branch originating from the thoracoacromial artery followed a course similar to radial artery in the forearm thus confirming it a high-origin radial artery. In the brachium, the radial artery coursed between the brachialis and biceps brachii muscle giving off a branch supplying the biceps brachii. In the cubital fossa, the radial artery is situated beneath the biceps tendon and bicipital aponeurosis lying lateral to the brachial artery and median nerve. The artery follows a normal course lateral to the flexor carpi radialis in the distal aspect of the antebrachium. It bifurcates into palmar and dorsal carpal branches at the proximal border of pronator quadratus. The brachial artery in the cubital fossa did not bifurcate and continued as ulnar artery on the medial side of the forearm. There were no observed anastomotic branches in the cubital fossa between the brachial artery and the radial artery. SIGNIFICANCE. The presence of high-origin radial artery may result in misdiagnosed radiculopathy owing to its close relationship with the median nerve. It is clinically significant in surgical management procedures such as a graft for coronary bypass, an intra-arterial injection and catheterizations of cardiac cavities. It is highly important to understand the variations in imaging studies to avoid misinterpretation of angiographic images.

SAKAMOTO, Yujiro. Graduate School of Medical and Dental Sciences, Tokyo Medical and Dental University, Tokyo, 113-8549, Japan.
Spatial Relations of the Lingual, Facial, and Occipital Arteries with the Submandibular Triangle.

INTRODUCTION. The digastric and stylohyoid muscles and the mandible form the submandibular triangle. The facial and occipital arteries branch off from the external carotid artery as it crosses the posterior belly of the digastric and the stylohyoid to enter the triangle. This study examined the branching point of the arteries to clarify their spatial relationships with the muscles. METHODS. The posterior belly, the thylohyoid and the origins of the lingual, facial and occipital arteries were gross anatomically examined in 15 Japanese cadavers. SUMMARY. The lingual artery arose from the external carotid artery above (24 sides) or below (1 side) the hyoid greater horn or at its level (5 sides). The origin of the artery was located inferior to the posterior belly and the stylohyoid, and the thyrolingual, linguofacial and thyrolinguofacial trunks were found in 1, 7 and 1 sides, respectively. The origin of the facial artery was superior (6 sides), inferior (21 sides) or deep (3 sides) to the muscles, and the trunks belonged to the inferior case. The occipital artery arose at the level of the origin of the lingual (2 sides) or facial (2 side) artery or above (18 sides) or between (8 sides) them. The facial type included the linguofacial trunk (1 side), the between the thyrolingual and the above the linguofacial (6 sides) and thyrolinguofacial. Its origin was located superior (8 sides) or inferior (22 sides) to the muscles, and the superior case was the above (7 sides) and between (1 side) types. CONCLUSIONS. The origins of the facial and occipital arteries are located inside or outside the submandibular triangle or deep to the posterior belly and the stylohyoid. The findings also suggest that the facial artery having the trunk with the lingual artery shows inferior position. The precise knowledge of the variations of the branching pattern of the arteries and their spatial relations with the muscles is useful to identify the arteries and their affected portions.

continued on next page

SANGARI, Santosh K.[1], Sven WALDERICH[2], Alexandru BARBULESCU[2], Sushil KUMAR[1], Ritwik BAIDYA[1], Anthony V. D'ANTONI[1], Estomih P. MTUI[1], and Roger HARTL[3]. [1]Division of Anatomy, Department of Radiology, Weill Cornell Medicine, NY 10065, USA; [2]Weill Cornell Medical College, NY 10065, USA; [3]Brain and Spine Center, New York-Presbyterian Hospital, Weill Cornell Medicine, NY 10065, USA.

Quantitative Measurements of Cadaveric Atlas and Axis Vertebrae as Guidelines for Screw Fixation.

INTRODUCTION. Posterior fixation using C1 lateral mass and C2 pedicle screws are preferred methods among spine surgeons for superior biomechanical stability. The translaminar screws rigidly capture posterior elements of C2 and is a suitable alternative in cases where pedicle screws are not possible or contraindicated. Most of the surgical papers have estimated the screw length by their experience and empiric estimation or measurements from imaging studies. METHODS. This study was conducted on various gross measurements of dry atlas (N=32) and axis (N=37) vertebrae available in the gross anatomy lab. The data was statistically evaluated to develop parameters for spine surgeons to avoid potentially fatal complications in cases of long or misdirected screws. SUMMARY. The AP diameter of atlas is an estimate of the screw length in the lateral mass of atlas. The mean (SD) AP diameter and width of the lateral mass of atlas were 20.48 (2.05) mm, (99% CI=19.82â€“21.14) and 16.16 (2.11)mm, (99% CI=15.48-16.85) respectively. The AP diameter of axis vertebra is an estimate of pedicle screw length. In axis vertebra, the mean (SD) AP screw length and width of pedicle were 23.48 (1.83)mm, (99% CI=22.93-24.03) and 7.95 (1.63) mm, (99%CI=7.46-8.44) respectively. Trans-laminar screw placement is an important alternative, a technically less demanding approach that reduces the risk of vertebral artery damage. The mean (SD) intra-laminar diameter and thickness of lamina were 16.25 (1.62)mm, (99% CI=15.76-18.25) and 5.67 (1.41)mm, (99%CI=5.25-6.09) respectively. Two-tailed t test revealed no statistically significant differences between right and left side measurements ruling out lateral dominance. CONCLUSIONS. Considering the close proximity of the vertebral artery and nerve roots to the atlas and axis vertebrae, the study provides accurate anatomical measurements to guide surgeons in the selection of screws for lateral mass of atlas, pedicle screws and trans-laminar screws in the axis.

SHARMA, Pranav, Crystal R. LEMMONS, Narinder SHARMA, and Alla G. BARRY. Missouri Southern State University, Joplin, MO, 64801, USA.

Association of a Specific Genetic Factor with Late-Onset Alzheimer's Disease: A Cadaveric Study.

INTRODUCTION. Late-onset Alzheimer's Disease (LOAD) is the most prevalent type of dementia worldwide. Although genetic factors along with risk factors have been identified as possible etiological agents of LOAD, currently, there is no definitive etiology identified for LOAD. Without a definitive etiology, specific cures or treatments are difficult to pursue and develop. In addition to other genes, recent research suggests that variants in the PLD3 gene may be involved; however, this research is inconclusive. The purpose of this study is to test the theory that the mutated PLD3 gene plays a role as a contributing factor in the aggregation of β-amyloid (Aβ) plaques in the brain -- one of the hallmark signs of Alzheimer's Disease (AD). METHODS. Ten formalin embalmed cadaver specimens were used to establish an association between a specific gene variant with LOAD. Histological examination of the brain tissue from the cadaver specimens served to diagnose AD in the cadavers, based on the presence of extracellular β-amyloid plaques and intracellular neurofibrillary tangles. Cadaveric DNA was extracted from the femur bone for analysis. SUMMARY. In the current study, cadavers were used to test for the prevalence of PLD3 gene variant in the development of LOAD. Considering the small sample size, Fisher's Exact Test was used to determine the significance of the association of the PDL3 gene variant with the histologically diagnosed LOAD. CONCLUSIONS. This novel method of using cadavers to understand the etiology of AD will further stimulate research, possibly, using different approaches to result in finding a treatment or cure for the condition.

TONG, Karen, Angela WANG-SELFRIDGE, Tatum B. COLBURN, and Anthony OLINGER. Division of Anatomy, Kansas City University of Medicine and Biosciences, Kansas City, MO, 64106, USA.

Transverse Carpal Ligament and Carpal Tunnel Morphological Analysis: A Cadaveric Study.

INTRODUCTION. The transverse carpal ligament (TCL) has been studied for its clinical relevance in carpal tunnel syndrome, and its routine surgical treatment, carpal tunnel release. Previous studies sought to better define the anatomic boundaries of the TCL and volume of the carpal tunnel to improve accuracy of surgery. However, morphological changes of these structures associated with specific patient factors, such as occupation and hand-dominance, have not been vigorously studied. The results of this study aim to help develop more targeted preemptive treatments, such as osteopathic manipulative treatment, and increase precision and reduce risk in surgical treatments. METHODS. Fifty-two embalmed adult cadaver specimens were dissected bilaterally at Kansas City University. Demographic data included age, height, weight, sex, occupation, and hand-dominance. The borders of the TCL were measured at their attachment sites to the carpal bones. The thickness was measured at the most distal, middle, and most proximal transverse fibers of the TCL. Finally, the cross-sectional axes were measured on a major and minor-axis halfway through the carpal tunnel. These measurements were

continued on next page

analyzed with sex, occupation, and hand-dominance for statistical differences. SUMMARY. Analysis of the data shows that the mean distances between scaphoid-to-pisiform and radial attachments are narrower than that of trapezium-to-hook-of-hamate and ulnar attachments, respectively. Mean lengths are overall shorter on the right than on the left. Mean thickness is highest when measured at the middle of the TCL and shortest at the most proximal fibers. The mean major and minor axes of the carpal tunnel are greater on the left than on the right. CONCLUSIONS. Presence of significant differences in morphology due to unique patient profiles may suggest benefit for specific preemptive treatment for future patients with similar morphology or factors.

WATANABE, Koichi[1], Kouji HAYAKAWA[2], Joe IWANAGA[3], Yoko TABIRA[1], Tsuyoshi SAGA[1], and Koh-ichi YAMAKI[1]. [1]Division of Gross and Clinical Anatomy, Department of Anatomy, Kurume University School of Medicine, Kurume, Fukuoka, 815-0034, Japan; [2]Hakusan Clinic, Oita, Oita, 870-0021, Japan; [3]Seattle Science Foundation, Seattle, WA, 98122, USA.

Anatomical Findings of Retaining Ligaments and Septum in the Deep Fat Compartment of the Cheek.

INTRODUCTION. The deep fat compartments of the face have a very important role in forming the basal structure of the face. This fat lies deep to the superficial musculoaponeurotic system (SMAS) and fills the spaces among the muscles, aponeuroses, and bones. A recent clinical anatomy study revealed that two fat compartments exist in the deep cheek: the deep medial cheek fat pad (DMCF) and the buccal fat pad (BF). This study was performed to increase the knowledge of these deep cheek fat pads and thus promote the development of anti-aging surgery. METHODS. Ten facial tissues, including the mandibular and maxillary bones, were removed from five formalin-preserved cadavers. Two tissues were dissected from the skin in layer order, and two tissues were dissected from the oral mucosa in layer order. Four tissues were used to create horizontal sections, and two tissues were used to create sagittal sections. Fat was removed from these sectioned tissues to observe the fibers in the tissues under a magnified view. SUMMARY. One superficial fat pad (malar fat pad) and two deep compartments (DMCF and BF) were confirmed in all tissues. A thick septum was observed between the DCMF and BF, connecting the SMAS and fascia of the buccinator. The SMAS was thick and clear posterior to the septum on the masseter and BF, was thin and irregular anterior to the septum on the DMCF, and continued to the orbicularis oris. Many thick fibers arose from the buccinator fascia about 1 cm anterior to the deep fat septum and extended in the DMCF with dendritic spread to the SMAS. CONCLUSIONS. The anterior cheek region is an abandoned territory in facial soft tissue research because it is difficult to approach during surgery. In the present study, we clarified two fibrous structures, the so-called retaining ligament and fat septum, that are considered to support the anterior cheek. These results will help to analyze the structure of the aging face and develop appropriate treatment.

YAKOOB, Nadha F., Bedia CASTELLANOS, and Naveen Babu KANDAVALLI. Touro College of Osteopathic Medicine, New York, NY, 10027, USA.

A Case of Unilateral Atrophied Right Sternocleidomastoid with Two Separate Bellies.

INTRODUCTION. Morphological variations of Sternocleidomastoid are significantly important to consider in cervical surgical procedures. It has been reported that Sternocleidomastoid exhibits changes in the muscle mass with relevance to congenital conditions such as Congenital Muscular Torticollis in infants and post-operative side effects such as radiotherapy induced toxicity of neck tumors in adults. In our case, we report an uncommon unilateral significantly atrophied right sternocleidomastoid. RESOURCES. During a routine dissection of an 85-year-old Caucasian female, sternocleidomastoid on the left side was noticed to have significant atrophy. Careful dissection of the nerve supply and adjacent structures of the neck was done. DESCRIPTION. The muscle displayed an expected dual headed attachment at the medial third of the clavicle and the sternum. However, both sterno-mastoid and cleido-occipital muscle bellies were unilaterally observed to be ranging in less than 1 cm each in width, with no other visible trauma to surrounding muscles. The Left sided sternocleidomastoid is of normal size, fully developed, with intact bilateral spinal accessory nerves and with appropriate functional attachments. There were no abnormalities observed in trapezius muscles on both sides. SIGNIFICANCE. The SCM is an amazingly complex muscle and has a multi-faceted relevance not only for anatomists, but also for clinicians, chiropractic's and surgeons. Better knowledge of its anatomy and its myriad variations can help physiotherapists to deal more effectively with SCM syndromes. Surgeons will be better oriented so as not to be confounded by the sudden appearance of any anatomical variations during invasive neck procedures.

continued on next page

Abstracts – Poster Presentations Session 3

(Listed by presenting author last name)

ABDEL MEGUID, Eiman M.[1], Claire F. SMITH[2], and Amanda J. MEYER[3]. [1]Centre for Biomedical Sciences Education, Queen's University Belfast, Belfast, BT9 1BL, UK; [2]Anatomy Department, Brighton and Sussex Medical School, University of Sussex, Brighton, BN1 9PX, UK ; [3]School of Human Sciences, The University of Western Australia, 6009, Perth , Australia.
Examining the Motivation of Health Profession Students to Study Human Anatomy.

INTRODUCTION. Student's motivation is a vital determinant of the academic performance which can be influenced by the educational program and the learning environment. Understanding student's motivation is important in assessing the effectiveness of a course. This study aimed to assess and analyze the motivation subscales between different cohorts (chiropractic, dental, medical) of anatomy students (n = 251) and if these motivation subscales were associated with examination performance. METHODS. A 31-item survey named the Motivated Strategies for Learning Questionnaire was used. It covered items on intrinsic and extrinsic goal orientation, task value, control of learning belief, self-efficiency for learning and performance, and test anxiety. SUMMARY. An overwhelming majority of respondents (n = 79%) indicated that they preferred course material that aroused their curiosity. Respondents commonly indicated that achieving a good grade was the most satisfying aspect of the course. Almost all respondents indicated that they would be able to learn course material if they used appropriate study methods. First year dental students were significantly more anxious than chiropractic students. Second year chiropractic students attached more value to anatomy education than second year medical students. A significant relationship was demonstrated between some motivation subscales and anatomy grades controlling for gender in first and second-year chiropractic students for self-efficacy for learning and performance, intrinsic goal orientation and the control of learning beliefs. CONCLUSIONS. This study provides useful information in selecting and generating appropriate motivational strategies.

BISHOP, Keith N., Caroline POAGE, and Angela HUMPERT. Doctor of Physical Therapy Program, Murphy Deming College of Health Sciences, Mary Baldwin University, Fishersville, VA, 22939, USA.
Human Cadaver Maintenance Techniques.

INTRODUCTION. Limited research exists on how different draping strategies can increase the length of time that human cadavers remain in their near pristine condition. The ability to maintain cadaver freshness and lifelike appearance is critical to extend the usability of these teaching tools especially as costs increase and availability of donors decreases. The purpose of this study was to discover an effective method to extend the serviceable time for donor bodies. METHODS. Four cadavers were included in the study and underwent regular dissections by allied health science students during the 2018-19 academic year. Donors were selected based on body composition, gender, and original skin integrity - two were chosen for upper extremity and two for lower extremity evaluation. The right limb of each cadaver served as the control limb and received a standard wetting protocol. The left limb served as the experimental limb and received one of the four wrapping methods that were secured with Velcro straps: 1) solution-soaked 2" Ace Wrap, 2) solution-soaked towels and cotton sock, 3) plastic wrap, 4) plastic bag and powder-free Nitrile glove. The limbs underwent weekly dissections for 5 out of the 9 months of the study. SUMMARY. Images of all limbs were collected between dressing changes in both prone and supine positions throughout the study. CONCLUSIONS. Visual inspection revealed ace bandage and plastic wrap methods were superior in maintaining fresh tissue appearance. The woven elastic composition of the Ace Wrap provided identical tissue coverage and similar moisture retention as the plastic wrap. The Ace Wrap was superior to plastic wrap due to ease of application and reusability of the material. Further research is needed to ensure this method is equally effective among various body types and extremities.

continued on next page

BOAZ, Noel T [1,2], Caroline Abercrombie[3], Joy Y. Balta[4,7], Robert Becker[3], Raymond Bernor [2,5], Tony Clary[1], Craig Goodmurphy[6], John Graham[1], Eileen L. Kalmar[7], Thomas Kwasigroch[3], Jon Krimsier[6], Carrie Robinson[1], Dana Sikon[8], Richard Sikon[9], Breezy Wasko[9], and Michael Wessels[10]. [1]Emory and Henry College School of Health Sciences, Marion, VA 24354, USA; [2]Laboratory of Biological Anthropology and Anatomy, Integrative Centers for Science and Medicine, Martinsville, VA 24112, USA; [3]Department of Biomedical Sciences, Quillen College of Medicine, East Tennessee State University, Johnson City, TN 37614, USA; [4]Department of Anatomy and Neuroscience, University College Cork, Cork T12 K8AF, Ireland; [5]Department of Anatomy, Howard University College of Medicine, Washington, DC 20059, USA; [6]Department of Pathology and Anatomy, Eastern Virginia Medical School, Norfolk, VA 23506, USA; [7]Department of Biomedical Education and Anatomy, The Ohio State University, Columbus, OH 43210, USA; [8]Surgical Skills Training Center, University of Virginia School of Medicine, Charlottesville, VA 22908, USA; [9]Virginia State Anatomical Program, Richmond, VA 23429, USA; [10]Trinity Fluids, Lapeer, MI 48446, USA.

Soft-Embalming Solidification Procedures to Maximize Student Learning Outcomes in Anatomy.

INTRODUCTION. Soft embalming affords many advantages that can promote active student learning in the Gross Anatomy Laboratory, particularly in respect to musculoskeletal structures. Viscera and neural structures, however, are frequently too flaccid or "collapsed" to be effectively handled and studied. RESOURCES. To maximize learning outcomes in soft-embalmed viscera and neural structures, procedures were developed for solidification of heart, lungs, and brain. Procedures and results were reviewed by a team of anatomist collaborators from a variety of programs with backgrounds in using soft-embalmed and traditionally embalmed donors. DESCRIPTION. To elaborate simple and effective procedures for injection and immersion using readily obtainable fluids that are practical for technical staff or faculty to perform on soft-embalmed structures. The primary soft embalming process must successfully fix the entire brain, optimized by injection of both common carotid and vertebral arteries, before solidification. Examples of solidified organs in situ and removed from the body are demonstrated. SIGNIFICANCE. Significant enhancement in student learning outcomes can be achieved with soft-embalmed laboratory dissection and prosection. Solidification of soft-embalmed organs can be achieved via injection and immersion to the extent that handling of structures is facilitated. Flexibility and distensibility of structures are nevertheless maintained.

BROOKS, H. Mark, Kristina K. BENSON, and S. Michael DHUY. Willed Body Program, School of Medcine, University of California at Irvine, Irvine, CA, 92697, USA.

Collaboration with Non-Profit to Increase Anatomical Donation within Korean-American Community.

INTRODUCTION. Historically, academic donation programs have appealed largely to a Caucasian demographic—as groups from more of an eastern religious or philosophical orientation have not been traditionally regarded as receptive to this type of post-mortem educational use. Partnering with a non-profit, whose mission was to make elderly Korean-Americans better informed of their final disposition options, has been a successful way in which to increase our donor registrations and case counts, while increasing community awareness to a commonly neglected ethnic subgroup. RESOURCES. Trained Korean-American volunteers to understand program objectives as they shared information about donation to their senior communities. Donation consents were translated into Korean for better understanding. Local Korean media was leveraged to promote informational events which included a public memorial service in Korean to foster appreciation and understanding. Further, university recognition was given to the organization on behalf of our Global Affairs Officer and Chancellor. DESCRIPTION. As a result of our collaboration with this non-profit, Korean-American registrations went from 2% of our total registrations in 2008 to 38% in 2018. While we received only one donor case in 2008, we received 28 in 2018. SIGNIFICANCE. After 10 years of fostering relations with a non-profit to increase awareness about anatomical donation within the Korean-American community, our Korean donations represented 33% of the total number of registrants. Training staff and volunteers to share information in a culturally and linguistically sensitive way changed the demographic profile of our donor base, while providing disposition information to a subgroup often overlooked.

CONLEY, David M.[1] and Zachary R. GALLAHER[2]. [1]Department of Medical Education and Clinical Sciences, Elson S. Floyd College of Medicine, Washington State University, Spokane, WA, 99210, USA; [2]Department of Biological Structure, University of Washington School of Medicine, Spokane, WA, 99258, USA.

Gross Anatomy Capstone Projects: Integrating Basic Sciences, Medicine, and Humanities.

INTRODUCTION. Capstones are student projects that serve as culminating academic experiences for programs of study. In our model of a gross anatomy capstone project, medical student teams deliver end-of-term presentations that summarize anatomical and clinical findings from their donor cadaver while they reflect on their personal experiences. RESOURCES. Students at the Elson S. Floyd College of Medicine (60 students) and the University of Washington School of Medicine in Spokane (60 students) separately utilize the same laboratory space for anatomical studies. Prior to any dissection, a complete post-mortem CT scan is performed on all student cadavers. Throughout their anatomical training, teams of 4 to 5 students are guided through dissections by anatomists and relevant clinical specialists (e.g., cardiothoracic surgeons during thoracic cavity dissections). Dissection teams review the CT scans of their cadaver with a radiologist and consult with a pathologist, who may obtain tissue samples and provide a report. Medical history and cause of death of donors

continued on next page

are not provided to the students. DESCRIPTION. The capstone project is presented as a ten-minute team presentation of the students' "first patient" to peers and faculty. Gross anatomy, pathology, and radiological images obtained from the donor form the backbone of the presentations, leading to postulation of the cause of death. Personal reflections and lessons learned during their time in the anatomy lab are another important component of the presentation. SIGNIFICANCE. Capstone projects are valuable self-directed opportunities for students to consolidate gross anatomy information through integration with clinical perspectives, imaging, and pathology. This approach also provides a forum for students to reflect on their preconceptions and reactions to the donated body, gain closure on the gross anatomy journey, and practice empathy, professionalism, and teamwork.

EDWARDS, Emily S. and Kyle E. RAREY. Department of Anatomy and Cell Biology, College of Medicine, University of Florida, Gainesville, FL, 32610, USA.
Creation of Student Self-Assessment Moments (SAMs).

INTRODUCTION. Self-assessment moments (SAMs) were designed to foster a new method for first-year medical students to practice their retention and recall of assigned gross anatomy, and evaluate their learning progress. METHODS. The SAMs were set up similar to an anatomy practical using images primarily of gross sections from the Virtual Human Dissector Program and Von Hagens Atlas of Sectional Anatomy. There were seven SAMs throughout a 16-week anatomy block. SAMs were setup over weekends. A survey that consisted of nine questions at the end of the semester was given. Seventy-two students of a class of approximately 140 responded. SUMMARY. Students (94%) agreed that SAMs facilitated their learning and recall of structures. Ninety-two percent acknowledged that SAMs also improved their retention of anatomy content. Students (89%) thought the weekly SAMs provided continuous feedback on their level of knowledge throughout the semester. When asked their approach to the SAMs, 51% of students used them to test themselves and 42% used them to review answers with a group. When asked how the SAMs were the most helpful, 60% of students used the SAMs as a review while 39% of the students used them as a study guide while learning the assigned material. CONCLUSIONS. Students universally expressed gratitude for the SAMs as a means to space their reviews of assigned anatomy and provide an additional measure for evaluating their learning progress.

GREENE, Sarah J.[1], and Lee ROSEN [2], [3]. [1]Department of Pathology and Anatomy, Morehouse School of Medicine, Atlanta, GA, USA; [2]Department of Psychiatry, Larner College of Medicine at the University of Vermont, Burlington, VT, USA; [3]Department of Psychological Science, University of Vermont, Burlington, VT, USA.
Sharing Personal Information About Anatomical Body Donors: What Do the Students Think?

INTRODUCTION. Of late, there has been discussion and debate about releasing personal and/or identifying information (PII) about anatomical body donors to students. It has been argued that releasing donor information may negatively affect students, emotionally or psychologically, yet there is little empirical data to support this claim. The purpose, therefore, of this study was to explore students' anticipated and actual responses to learning PII. METHODS. Four surveys were sent out to four cohorts of first-year medical students (n = 388) across the first year. These included questions about emotional responses to working with donors, what PII they would like to learn, and how this would or did affect their responses to working with the donors. Analyses examined the impact of survey timing, gender, and previous exposure to donors. SUMMARY. Based on responses of the first three cohorts, a majority of students wanted to know some form of PII, and felt learning this would or, in fact, did increase their positive responses to working with donors at all time points. At each time point, only a small percentage of students, if any, felt that learning PII would or did negatively affect their responses. CONCLUSIONS. The results of this study suggest that sharing donor PII is not detrimental, but may be desired and of benefit to students studying anatomy. Data including the forth cohort is currently being collected and will be incorporated into this presentation.

Grant Sponsors: US Dept. of Education: P03-1B141018; NIH: G12MD007602

continued on next page

HAWKINS, Camryn T., Melissa M. QUINN, and Eileen L. KALMAR. Division of Anatomy, Department of Biomedical Education & Anatomy, The Ohio State University, Columbus, OH, 43210, USA.
Comparison of Three Embalming Solutions to Fresh Tissue: Directed at Undergraduate Anatomy Courses.

INTRODUCTION. In an ideal setting, all students would be able to dissect on fresh, un-embalmed cadavers however, due to the need for cadavers to last for extended periods of time and the potential spread of infection, fresh specimens are not utilized. We explored three embalming solutions to see which solution can produce close to "life-like" quality of a diversity of tissues while preventing decomposition. RESOURCES. Four cadavers from the Ohio State University Body Donor Program were used. One cadaver was embalmed with a formalin mixture with phenol. One cadaver was embalmed with a phenol-free formalin solution. One cadaver was embalmed with a combination of alcohol and glutaraldehyde. The final cadaver was left un-embalmed but kept in refrigeration when not in use. Following embalming, each cadaver was dissected in the following areas: the axilla, the thorax, and the femoral triangle. These areas were selected because they show a wide variety of tissue types. DESCRIPTION. One dissector completed all of the dissections, photographed the areas, and completed a qualitative analysis comparing the different cadavers. The cadavers were evaluated based on their ease of dissection, the pliability and mobility of the tissues, length of preservation before decomposition, and color similarities to the fresh specimen. SIGNIFICANCE. Both the glutaraldehyde and alcohol solution and the phenol-free formalin solution were considerably more pliable and mobile than the formalin with phenol solution. Fascial layers were fused with the formalin with phenol solution making dissection more difficult than the others. The alcohol and glutaraldehyde solution showed the closest coloration to the fresh dissection, but without refrigeration decomposition begins quickly. The phenol-free solution performed the best across the board in terms of ease of dissection, pliability, length of preservation, and color similarities to the fresh specimen.

HISLEY, Kenneth B.[1], Beddhu MURALI[2], David J. ELIOT[3], Kamal A. ABOUZAID[1], Jennifer L. HOTZMAN[1], Douglas R. TRIGG[1], and Anirudh PULASANI[2]. [1]William Carey University College of Osteopathic Medicine, Hattiesburg, MS, 39401, USA; [2]University of Southern Mississippi, Hattiesburg, MS, 39401, USA; [3]Touro University California, Vallejo, CA, 94592, USA.
Tracking and Analyzing Laboratory Dissection Progress Using a Transactional Database System.

INTRODUCTION. This work describes a system supporting improved dissection progress tracking, cataloging of variations, assessment consistency and student collaboration in their laboratories. The fundamental units of anatomy courses are lectures and labs with corresponding lists of structures linking the two which we itemize as Anatomical Study Lists (ASLs). Anatomy education involves the illustration of annotated structural configurations paired with dissection confirmation of the structures as guided by these annotations. Observing inconsistencies in the tracking of tank progress, we designed an event-driven system to capture dissection progress in real-time using a client-server database system capable of rationalizing the process by ASL item. RESOURCES. The hardware includes iPad clients, a database server, lab display screens, and desktop computers. This system has four components: 1) an iPad client for real-time input to the database, 2) a transactional database server, 3) lab-wide display output, and 4) a data download application for offline analysis. DESCRIPTION. Database capture, update and status display: Clients display a touch-enabled event-based ASL/tank table (iPad) that includes the following fields: timestamp, tank number, ASL item, status ("found" or "found+exemplary", "variation"). Faculty update/confirm successful dissections at a table element by touching an element to change its status, generating a database update event that simultaneously revises all lab displays. This shows the general lab tank status including those with the best examples. Data offload: Accumulative data is downloaded to desktop computers for analysis. SIGNIFICANCE. We are looking for four initial results made possible by this system: 1) the identification of tanks falling behind, 2) the identification of anatomical variations, 3) increased student exposure to the best ASL examples, and 4), an increase in dissection quality driven by a spirit of competition.

MCWHORTER, David L., Zachary T. PIERCE, Chris W. FLEMING, Julia R. HAFFNER, Emily L. HUDSPETH, Seth E. BAYIRD, and Jonathan M. HUNTER. Arkansas College of Osteopathic Medicine, Fort Smith, AR, 72916, USA.
First-Year Medical Students' Perceptions of a Peer-Directed Simulated Anatomy Lab Practical System.

INTRODUCTION. The anatomical sciences represent the bulk of curricular content that first-year students are expected to learn during a 16-week Foundations of the Anatomical Sciences (FAS) course at the Arkansas College of Osteopathic Medicine. A peer-directed mock anatomy laboratory practical program was developed to assist students' learning of gross anatomy. The purpose of this study was to determine whether students valued a peer-directed mock practical program. METHODS. Six first-year medical students who completed an elective two-week pre-matriculation anatomical sciences prep course set up and facilitated ten mock gross anatomy practicals, consisting of primary and secondary cadaveric and osteological questions. Questions were initially tagged and verified by two teams of three students. Mock exams were held on weekends and open to all first-year students. Instructions for different exam formats were posted in the lab along with

continued on next page

answer keys. A nine-question Likert scale survey with two open-ended questions about the mock program was given to all first-year students, excluding the six students who set up the mock practicals (N=149). SUMMARY. One-hundred and nineteen students (80%) completed the survey. Ninety-two percent of respondents took three or more mock practicals, and 86% of students agreed or strongly agreed that the mock practicals helped prepare them for the actual FAS course practicals. Additionally, 88% of respondents agreed or strongly agreed that the mock practicals enabled them to identify knowledge gaps, requiring additional independent study. CONCLUSIONS. A peer-directed mock anatomy laboratory practical method was valued by first-year students. Future studies are required to assess whether participation in mock practicals affect FAS course laboratory exam performance.

HUNTER, Shelley D., Daniel O'DONOGHUE, and Nancy HALLIDAY. Department of Cell Biology, University of Oklahoma Health Sciences Center, Oklahoma City, OK, 73104, USA.
Anatomical Donor Luncheon: A Transformational Experience for Medical Students.

INTRODUCTION. The University of Oklahoma Health Sciences Center hosts an annual Anatomical Donor Luncheon during student orientation week. The purpose of this luncheon is to provide an opportunity for families to share the life story of the anatomical donors with medical students assigned to their deceased family member prior to the start of the anatomy course. Students are advised to keep the conversation focused on the life stories of the deceased, and active listening strategies are demonstrated to facilitate this process. Upon the completion of the anatomy course, students conduct a service of appreciation and submit a brief reflection paper regarding the impact of meeting the donor's family on their gross anatomy experience. The purpose of this qualitative study is to determine medical students' perceptions of donor family-student interaction on their gross anatomy learning experience. METHODS. Student reflection papers were retrieved via learner management system and were coded using the constant comparative method to saturation. Data was triangulated and themes developed by faculty investigators and doctoral students in an iterative review process. SUMMARY. A meta-theme of Positive Transformational Experiences was identified. Subthemes included Student Gratitude Regarding Experience, Donors as Student Motivators, and Contextual Influences Alter Student Attitudes. Anecdotally, faculty reported cessation of inappropriate student comments and behavior regarding the anatomical donors since the luncheon's inauguration. CONCLUSIONS. Though some initially expressed reservations about meeting donor families, upon reflection students recognized the value of learning the life stories of their "first patients." The overwhelmingly positive effects of donor family-student interaction on medical students may contribute to professional identity development and need to be considered when debating the ethics of the use of protected health information (PHI) of donors.

JACKMAN, Trent D.[1], Sara GRANT[1], Brandon METCALF[1], Stefani ATTARDI[2], Ann MARIE-BLENC[3], and Malli BARREMKALA[2]. [1]MS2, Oakland University William Beaumont School of Medicine, Rochester, MI, 48309, USA; [2]Department of Foundational Medical Studies, OUWB, Rochester, MI, 48309, USA; [3]Department of Pathology, Beaumont Health System, Royal Oak, MI, 48073, USA.
Are Soft-Embalmed Cadavers Better for Histopathological Study?

INTRODUCTION. Many first year medical students spend hours in lab dissecting and studying cadavers to master anatomical concepts. As a way to foster interest in Histopathology, Oakland University medical students have the opportunity to examine pathological lesions from their cadavers and examine after staining with hematoxylin and eosin (H&E). These cadavers are typically embalmed using a formaldehyde solution. Recently, different embalming methods have been developed to decrease the amount of formaldehyde used due to risk of toxic exposure. These cadavers are often termed soft-embalmed, and are preserved with <1% formaldehyde, <20% ethylene glycol, <10% ammonium nitrate, <10% ethanol, <10% sodium sulfite, <5% morpholine, <5% boric acid, and <1% chlorocresol. We were curious to know if the soft-embalmed cadavers impacted the quality of the histopathological samples. We believe that a soft-embalmed donor will be an excellent source of histological samples for anatomy courses. METHODS. Soft and formalin embalmed cadavers were dissected according to Thieme Dissector Guide. Samples of the cadavers liver, heart, skeletal muscle, small intestine, bladder, bone, kidney and skin were taken and prepared by pathology staff at Beaumont Hospital according to the formalin fixed paraffin embedded protocol. Staining was done with H&E. SUMMARY. Kidney: Structural preservation is worse in soft-embalmed sample compared to formalin-embalmed. Liver: Preservation of the formalin-embalmed liver is better than the soft-embalmed liver samples. CONCLUSIONS. Our initial findings show that the soft-embalmed cadavers do not maintain a high quality for histological purposes. One aspect we are eager to explore is the preservation of mucosal membranes. We assume that the trend will continue with the formaldehyde embalmed samples maintaining better preservation for histological sampling. The current study is limited to comparing one type of soft-embalming to formalin embalming.

continued on next page

JOHANSEN, Krista S[1], Ellie GLASGOW[2] and Leslie SCHNEIDER[3]. [1]Department of Medical Education, Tufts University School of Medicine, Boston, MA, 02111, USA. [2]Public Health Professional Degree Programs, Tufts University School of Medicine, Boston, MA, 02111, USA. [3]Center for Translational Science Education, Tufts University, Boston, MA, 02111, USA.
Teaching Radiological Anatomy with a Technology-enhanced Workshop and Online Collaborative Learning.

INTRODUCTION: Radiological anatomy is rarely introduced in Physician Assistant (PA) curricula. When it is, most often it involves didactic lectures using static images or is incorporated with clinical lectures, with emphasis solely on abnormal findings. Using an enhanced technology workshop format and piloting an online collaborative learning platform, Visual Classrooms, the class was able to work in groups then post marked-up images and case discussions to the online collaborative platform. This created an active learning environment with opportunities for feedback from peers and the faculty facilitator. METHODS. 50 first-semester PA students, divided into 10 groups in a technology-enhanced classroom worked together through a series of exercises and cases. Resources included a normal CT scan series case studies with chest X-rays and chest CT scans. Explicit training on how to approach chest x-rays and chest CT scans was given via a short video and reinforced in the workshop. A pre-test of radiologic identifications was given prior to the workshop and an identical post-test given the week after. SUMMARY. A paired t-test was conducted and demonstrated a significant difference in the scores for the pre-test (M=5.08, SD 2.64) and post-test (M9.23, SD 1.15); p<.001. In addition, there was higher scoring on radiologic anatomy mid-term questions for the 2019 cohort when compared to the 2018 cohort who only received didactic lecture. Survey data suggest that the 2019 cohort found radiological anatomy the most relevant component of the course. CONCLUSIONS. Using an interactive workshop with online collaborative learning platform increases PA students' ability to interpret normal radiologic anatomy and begin to recognize abnormal radiologic findings. This format was perceived as meaningful and favorable by students. Plans are being made to incorporate the collaborative learning platform into the MD student curriculum.

JOHNSON, Christopher G., Whitney A. BLODGETT, David A. PENNING, and Alla G. BARRY. Department of Biology and Environmental Health, Missouri Southern State University, Joplin, MO, 64801, USA.
Etiology of Pseudoconclusion: Phenomenon of Pseudoreplication in Anatomical Research.

INTRODUCTION. Statistics are used to describe and quantify data and to draw larger conclusions using inferential methods. There are strict guidelines and assumptions required by statistical tests when collecting and organizing data. The samples must be independent, and the treatments must be applied randomly. Pseudoreplication occurs when samples used are not independent, but treated as though they are. Pseudoreplication can introduce both type I and II errors into the conclusions. The field of anatomical research is especially prone to pseudoreplication due to the very nature of the human body having bilateral symmetry with two versions of many different structures. RESOURCES. An extensive literature review was performed, reviewing various anatomy journals to isolate possible pseudoreplication in research papers. Pseudoreplication was present in a number of isolated studies. DESCRIPTION. To discuss pseudoreplication in terms of how it affects data and ways to avoid it. SIGNIFICANCE. In the field of clinical anatomy, the results of the research could have far-reaching effects. Healthcare providers often rely on study results and the possible significance to infer the findings on a population. In order to maintain efficient use of resources and integrity of the design, pseudoreplication must be addressed in all studies. Though pseudoreplication is detrimental to the results of a study, it can be easily avoided with proper statistical analysis. This can be accomplished through more rigorous statistical training and a better understanding of test assumptions.

MEYER, Edgar R.[1], Amber M. JAMES[1], Allan SINNING[1], Kenneth THOMPSON[2], and Dongmei CUI[1]. [1]Clinical Anatomy Division, University of Mississippi Medical Center, Jackson, MS, 39216, USA. [2]Office of the Registrar and Office of Institutional Research, Millsaps College, Jackson, MS, 39210, USA.
Perception versus Performance: Discrepancies in Students' Perceived and Actual Retention of Anatomy.

INTRODUCTION. Several studies have examined the effects of virtual stereoscopic 3D models on students' anatomy learning, but limited studies examine their effects on long-term retention. This project explores the differences between first-year medical students' perceived and actual retention after viewing virtual 3D pelvic and middle and inner ear models. METHODS. Students (n=22) attended 3D learning sessions featuring the stereoscopic pelvis model while another cohort (n=117) attended 3D learning sessions featuring either monoscopic (n=53) or stereoscopic (n=64) middle and inner ear models. In all sessions, students were administered tests regarding relevant anatomy before and after their 3D learning experiences: pre-3D tests, mental rotation tests (MRTs), and short-term post-3D tests. In addition, students were administered long-term assessments one month after the learning experiences. Students also completed surveys assessing their perceptions of the virtual 3D models' improvement of their understanding of 3D relationships and enhancement of their retention. SUMMARY. This project compared short- and long-term performance outcomes to students' survey responses. Most students either agreed or

continued on next page

strongly agreed that pelvic and middle and inner models improved their comprehension of 3D relationships and enhanced their retention. However, final results showed no significant difference (p = 0.502) between the results of the virtual 3D pelvis model and traditional anatomy learning on students' short-term retention. There was also no significant difference (p = 0.069) between the results of monoscopic and stereoscopic virtual 3D middle and inner models on students' short- or long-term retention. CONCLUSIONS. Virtual 3D models have the potential to augment traditional anatomy instruction rather than supplant it. First-year medical students' perceptions of what they retain may also not necessarily reflect what they actually retain.

MOON, Mary[1,2], Daniel O. DONOGHUE[2], Kathryn KLUMP[2], and Nancy HALLIDAY[2]. [1]ILAC Department, College of Education, University of Oklahoma, Norman, OK 73019; [2]Department of Cell Biology, University of Oklahoma Health Sciences Center, Oklahoma City, OK, 73104.

Case-Based Anatomy Review: Comparison of Cadaver versus Computer Based.

INTRODUCTION. After foundational anatomy is covered in Human Structure, system specific content is re-visited in systems courses. We use case-based reviews (C-BR) of anatomy and pathologies to promote teams' participation in problem-solving and discussions of systems specific anatomy. These C-BR were with either cadavers or PowerPoint (PPT) C-BR with cadaveric images. A major difference was that the laboratory sessions were facilitated (clinicians or anatomists) while the PPT-based cases were not. METHODS. 1) Student perspectives, 2) student learning outcomes, and 3) faculty perceptions were analyzed to evaluate effectiveness of the C-BR. End of course surveys captured student perceptions of the cadaver-C-BR as compared to the PPT-C-BR. Student perceptions were analyzed with constant comparative methods. Quantitative data on student learning outcomes were collected through anonymous pre- and post-session quizzes. Faculty perspectives were collected via an anonymous on-line survey. SUMMARY. Qualitatively, student preferred the cadaver C-BR sessions over PPT C-BR. Students liked speaking with clinicians and anatomists face-to-face as a better learning encounter. The students also perceived that they understood the clinical anatomy better with the increased level of engagement. Quantitative analysis showed no difference in the proportion of correct responses before receiving C-BR (p=.60). However, cadaveric C-BR students had slightly more correct answers (82%, 95% CI:79.4,84.5) compared to students receiving the PPT-C-BR (77.6%, 95% CI:73.2,81.6), bordering statistical significance (p=.06). Faculty perceived that both forms of C-BR reached goals for learning outcomes. The faculty felt like the students were more engaged in the cadaver C-BR. CONCLUSIONS. The educational outcomes were not different by the modality of presentation of C-BR. The cadaver C-BR sessions were more resource intensive, but provided a more enjoyable encounter for both faculty and students.

NA, Youjin[1], Derek W. CLARY[2], Zakary ROSE-RENEAU[2], Philip BRAUER[1], Barth WRIGHT[2], Andrea HANSON[2], and Sarah KEIM[2]. [1]Kansas City University of Medicine and Biosciences Farber-McIntire Campus, Joplin, MO, 64804, USA; [2]Kansas City University of Medicine and Biosciences, Kansas City, MO, 64106, USA.

Spatial Visualization of Human Anatomy through Art.

INTRODUCTION. Art has a long history with anatomy education, from the drawings of Leonardo da Vinci to the atlases and 3D anatomy programs used today. Prior research has explored the relationship between art and anatomy. Most studies in this area focus on how interpretation of art improves observational skills, and not on how engaging in art affects spatial visualization. The purpose of the current study is to examine the impact of technical drawing exercises on spatial visualization and ultimately on anatomy lab education. METHODS. First-year medical student volunteers were placed into a control or art-training group, where the students in the art-training group worked through technical drawing worksheets during four instructor-led art sessions. SUMMARY. The study is currently in progress. A pre- and post-Mental Rotation Test (MRT) will be used to assess change in spatial visualization. The neuroanatomy topography practical score and anatomy-based questions on the neurology written exam will be used to assess understanding and conceptualization of anatomy. It is hypothesized that students in the art-training group will show greater improvement in MRT scores and perform better on the neuroanatomy practical and neurology written exam compared to those in the control group. CONCLUSIONS. Spatial visualization skills are utilized in orienting oneself and understanding relationships within the human body when learning anatomy. This may be beneficial in various fields of medicine, particularly radiology or minimally invasive surgeries involving laparoscopy. Results of this study could provide insight into a simple way of improving one's spatial visualization, and ultimately their understanding of anatomy, using art.

continued on next page

NG, Ricky, Ian BELL, Cindi MORSHEAD, and Anne AGUR. Division of Anatomy, Department of Surgery, University of Toronto, Toronto, ON, M5S 1A8, Canada.
Maintaining an Anatomical Museum: Experiences Choosing Materials for Specimen Containers.

INTRODUCTION. Anatomical museums have been a valuable resource for students for several hundred years. The JCB Grant Museum at the University of Toronto is one such resource that has formed the basis for Grant's Atlas of Anatomy. The museum was established in the 1940s and to this day, houses specimens used for the first edition of Grant's Atlas. The maintenance of the museum specimens requires knowledge of repair and replacement of specimen containers. Herein we provide insight into specimen container repair and replacement. RESOURCES. Cast and extruded plexiglass, and glass are the materials of interest. DESCRIPTION. The museum houses approximately 500 wet specimens in glass or plexiglass containers, preserved in 10% formalin. Over time, containers have needed replacement due to leaks and/or breaks. Initially, the plan was to construct replacement containers on-site by joining cut plexiglass sheets using acrylic cement. However, these containers proved to be unreliable, and some developed leaks within several months. It was determined that the specimen jars failed due to the presence of methanol in formalin. Methanol and other alcohols exhibit solvent-like activity on acrylics and plastics, eventually causing containers to crack and leak. After experimenting with both types of acrylics, we determined that cast acrylic should be used for specimen jars, due to significantly greater resistance to alcohol. However, both acrylics were found to be useful for suspending and posing specimens in the containers. The purchase of new glass containers has been challenging as they are produced in select sizes that do not accommodate most anatomical specimens. SIGNIFICANCE. Maintaining the quality of the anatomical specimen collection is of utmost importance to the museum and its value as a study resource.

PETERSON, Joanne L, Paulina K. BLANC, Joshua A. GAUNT, and Heather M. GUZIK. Department of Anatomy, Arkansas College of Osteopathic Medicine, Fort Smith, AR, 72916, USA.
The Effect of an Anatomy Prep Course on OMS-1 Student's Performance During the Fall Semester.

INTRODUCTION. A preparatory course was created at Arkansas College of Osteopathic Medicine (ARCOM) to pre-expose students to anatomy and help ease transition into medical school. The ARCOM Anatomy prep course is an optional two-week course delivered immediately preceding the first year of medical school. It is taught exclusively by Anatomy faculty and exposes the students to some of the same lectures and cadaver dissections as the Fundamentals of Anatomical Sciences (FAS) course. Students were also given lecture and practical exams mimicking FAS exams. The aims of this study are to 1) evaluate the effectiveness of the prep course on academic performance, not only in the FAS course, but in all courses taken during the first year of medical school, and 2) evaluate the perceived value of the course by participants (APC) and non-participants (ØAPC) of the course. METHODS. For the first aim, grades were obtained for all lecture and practical exams given during the first-year fall semester. Using a student's t-test, exam and final grades from APC students were compared to ØAPC for each course. For the second aim, an 11-question survey was administered to the APC group and a 5-question survey to the ØAPC group. SUMMARY. Students in the APC group performed significantly better on the first lecture and practical exams in the FAS course. No other exams showed significant differences. The majority of APC and ØAPC reported that the APC group had an advantage over the ØAPC on the first set of FAS exams, with most APC students reporting satisfaction with the course and many of the ØAPC group stating yes or maybe when asked if they wished they had taken the course. All of APC students agreed that the prep course eased medical school transition and most students anxious about working with cadavers claimed it eased their anxiety. CONCLUSIONS. The prep course improves academic performance on the first exams in an anatomy course and helps ease the transition into medical school.

PLUTINO, Danielle M., and Alla BARRY. Missouri Southern States University, Joplin, MO, 64801, USA.
The Effects of Cadaver Lab Exposure on Physical and Spiritual Wellness.

INTRODUCTION. In light of increased demand of gross anatomy requirements in professional school, MSSU installed a cadaver dissection laboratory on campus. Although students rated utilization of the undergraduate human dissection room as the most helpful tool in learning anatomy; negative emotional or physical responses such as anxiety, nausea, and apprehension were also reported. Students taking cadaver-based courses are strongly encouraged to treat the bodies with the utmost respect and gratitude. Developing this mindset and engaging more sensory pathways impresses the experiences in the cadaver lab more readily into students' minds and disposes them to appreciate the gift of humanity even more. The previous study of the psychosocial impact of cadaver laboratory experience at MSSU revealed that dissection room participation significantly increased willingness to consider organ donation. However, the lack of a control group in the study made results inconclusive. RESOURCES. A longitudinal study involving undergraduate students taking Anatomy

continued on next page

and Physiology II classes at MSSU and Crowder College was conducted to evaluate the impact of cadaver laboratory experience on physical and spiritual wellness. DESCRIPTION. A survey utilizing a Likert scale was distributed to students in the beginning and end of the semester. Crowder College students were chosen as the control group due to the facility not utilizing a cadaver lab in their course. SIGNIFICANCE. It is often assumed that wellness is the absence of disease when in reality it is the pro-active striving for positive physical, mental, and spiritual well-being. One of the most valuable experiences for the students taking cadaver-based courses is exposure to the priceless gift of the human body that has multifaceted effects on their well-being.

ROYER, Danielle[1], Heather CARMICHAEL[2], Kimi L. KONDO[3], Lisa L. LEE[1], and Cory B. GRITTON[1]. [1]Department of Cell & Developmental Biology, University of Colorado School of Medicine, Aurora, CO, 80045, USA; [2]Department of Surgery, University of Colorado School of Medicine, Aurora, CO, 80045, USA; [3]Department of Radiology, Division of Interventional Radiology, University of Colorado School of Medicine, Aurora, CO, 80045, USA.

SOARing to New Heights: Evaluation of a New Interactive Supplement to a Medical Anatomy Course.

INTRODUCTION. The University of Colorado implemented 9 new Structured Obligatory Application & Review (SOAR) sessions in medical anatomy. SOAR was developed to improve the anatomy block across 11 specific goals reflecting medical education trends. During SOAR, small groups rotated through 4 interactive sessions: embryonic correlations with gross, anatomy in physical exam & imaging, cadaver-side surgical cases, and board-style questions using TBL. This study aimed to evaluate achievement of SOAR goals based on student perceptions. METHODS. First year medical students (N=184) were recruited in the semester following anatomy to complete an online survey with 11 Likert questions based on the goals of SOAR, plus 2 open-ended questions. Data were analyzed using descriptive statistics and thematic analysis. SUMMARY. The class response rate was 30% (N=57). Quantitative findings are reported as percent agree + strongly agree. Analysis revealed strong agreement that SOAR met 4 of its goals: providing clinical relevance (91%), identifying knowledge gaps (91%), clinical application of knowledge (82%), and connecting anatomical concepts (74%). Ratings indicated SOAR was moderately successful in achieving goals of engagement with anatomy (68%), self-directed learning (63%), exam preparedness (60-63%), and peer teaching (61%). Responses suggested SOAR was less successful in achieving the goals of increasing retention (51%) and confidence in anatomy (47%). Initial thematic analysis suggested that more facilitators, improved group dynamics, and some structural changes may enhance SOAR. CONCLUSIONS. Overall, students perceived that SOAR accomplished most of its goals to a certain degree, with the strongest benefits perceived as providing clinical relevance, identifying knowledge gaps, clinical application of anatomy, and connecting anatomical concepts. Rigorous thematic analysis will be completed to provide deeper insight into this new curricular format.

SCHNEIDER[1], Brandt, Gurvinder KAUR[1] , Vaughan LEE[2], Simon WILLIAMS[1], and Katie HIGGINS[1]. [1]Department of Medical Education, School of Medicine, Texas Tech University Health Sciences Center, Lubbock, TX, 79430, USA; [2]Department of Medical Education, School of Medicine, University of South Alabama, Mobile, AL, 36688, USA

Can Formative Assessments Preemptively Identify “At Risk” Medical Students?

INTRODUCTION. The Texas Tech University Health Sciences Center (TTUHSC) School of Medicine curriculum starts with the 10-week block of Clinically Oriented Anatomy (COA). During this course, first year medical students learn about human anatomy through lectures and cadaveric laboratory dissections. To improve the efficiency of anatomical education in the COA course, a collection of formative assessments for didactic and laboratory concepts are provided. These formative assessments direct the students to focus on their knowledge gap prior to taking the in-house graded exams. COA is a very rigorous course that moves at a fast pace. Thus, identifying “at risk” students early on and providing them appropriate counseling and guidance would be an ideal approach to improve the student learning experience. With this objective, we investigated the potential predictive ability of practice exams at identifying “at risk” students early in the course. METHODS. Laboratory practice exams were created using digital images from prosections that were incorporated into simple recall or clinical application questions. Didactic practice exams consisted of first, second and third order questions. Assessments were delivered through ExamSoft and were available at least 3 days prior to the Unit exams. Rationales were provided for each answer choice to provide immediate feedback. SUMMARY. Analysis of collected data revealed that formative assessments strongly correlated with graded exam performance (p values ranging from 0.01-0.001 and r values from 0.44-0.68). Furthermore, graded exam performance also correlated strongly with NBME performance (p = 0.001 and r = 0.84). CONCLUSIONS. Since the student’s perception of these formative assessments were very favorable, we propose to use formative assessments to preemptively identify “at risk” medical students for early intervention and remediation. (Sponsored by the Department of Medical Education at the TTUHSC SOM.)

continued on next page

STEVENS, Karen M., Jeffrey DAMASCHKE, and Patrick WITHROW. Department of Physical Therapy, Rosalind Franklin University of Medicine and Science, North Chicago, IL, 60064, USA.
Vertically and Horizontally Integrating Anatomy in a Doctor of Physical Therapy Curriculum.

INTRODUCTION. Horizontal and vertical integration of anatomy in physical therapy curricula may facilitate retention, application, and link foundational and applied sciences. Integrating fosters learning anatomy across time and subject matter. Introducing foundational knowledge early in learning via dissection and basic palpation may be followed by experiences involving more complex applications of clinical problem solving, diagnostic ultrasound, and joint assessment with prosections. RESOURCES. Collaboration and resources have allowed physical therapy students to dissect in interprofessional teams, and then use prosections and diagnostic ultrasound in later coursework. DESCRIPTION. During the first quarter of study physical therapy students are introduced to the three-dimensional organization of the human body in an interprofessional anatomy course, where they dissect in small interprofessional teams. At the same time, clinical correlates and hands-on simple examination skills are introduced by body region in Orientation to Physical Therapy. In the next quarter, students use prosections while they instruct and demonstrate regional structures in an interprofessional physiology course. Then, students return to the lab while they learn about joint function in a kinesiology course. A second anatomy course in the second year includes learning about surgical procedures, nerve entrapments, and imaging in the lab while they develop manual therapy skills in a clinical skills course. SIGNIFICANCE. Repeated, progressively more complex applications of anatomical structure and relationships receives favorable reviews from students and faculty, and appears to enhance both foundational and application sciences. It has been feasible because of collaboration across programs and administrative support. Horizontal and vertical integration in a curriculum is favorable for learning and applying anatomy.

SULAIMAN, Sara[1], Brandi SCHMITT[2], David M. CONLEY[2], Bobbi MORGAN[2], and Dianne PERSON[2]. [1]Centre for Applied Anatomy, University of Bristol, Bristol, BS2 8EJ, United Kingdom; [2]Anatomical Services Committee 2017-2018, American Association of Clinical Anatomists, GA 30241, USA.
Body Donor Personal Information: A Survey of AACA Members.

INTRODUCTION. Published literature argues that introducing body-donor personal information to students changes the cadaver-patient dynamics enhancing students' empathy and psychosocial intelligence. However, the nature of the donors' personal information provided to students is vastly inconsistent among body-donation programs. This study aims to explore donor personal information disclosure practices among body-donation programs and assess the variability in the type and level of information released. It also evaluates anatomist's perception to disclosing donors' personal information. METHODS. A total of 46 anatomists, of different academic position and length of career, predominantly from the USA completed a 26-item electronic survey. SUMMARY. The most common donor personal information disclosed was age at the time of death (84.8%), cause of death (82.6%), and occupation (43.5%), while, ante-mortem images (4.3%%) and last name (10.9%) was the least commonly disclosed information. 45.5% of participants indicated that their donation consent forms do not disclose the practice of releasing donor personal information. Moreover, 17.8% of participants expressed concerns about losing potential body-donors if programs disclosed the practice of releasing donor personal information for educational and research purposes. Accessing and releasing more donor personal information to students was favoured by 25.6% of participants. CONCLUSIONS. The nature of donor personal information released to students varies among body donation programs. Although anatomists generally agree that donors' consent is the central ethical value; empirical evidence is still required to assess the educational value of the release of donor personal information and its impact on student's socialization and professional formation.

TAYLOR, Megan, Shannon SAMPLE, and Alla BARRY. Missouri Southern State University, Joplin, MO, 64801, USA.
A Study of Factors Influencing Voluntary Whole-body Donation.

INTRODUCTION. The importance of whole-body donation cannot be discounted, as it contributes to the advancement of skills training for future healthcare providers. Yet awareness of whole-body donation remains scarce. Previous studies have shown that demographic factors such as gender, age, race, income, and education level have significant impacts on a person's willingness to donate their body. This study investigated a participant's willingness to become a whole-body donor among the employees at Missouri Southern State University, an undergraduate university that has been using cadavers in their anatomy courses for nine years. It sought to determine if such demographic factors exist at a campus where whole-body donation has been well-publicized. METHODS. A survey was sent to all employees on campus which included demographic questions along with Likert questions concerning awareness of and willingness to become a whole-body donor. SUMMARY. Approximately one quarter of employees across all classifications responded to the survey (n = 110). Results indicated a high awareness of the use of human cadavers on campus at 89% (n = 98). Statistical analysis revealed no significant associations among demographics such as employment classification, personal yearly income, educational level, age, and length of employment with willingness to become a whole-body donor (p=0.306, 0.351, 0.51, 0.255, and 0.732). CONCLUSIONS. Efforts to promote awareness and thoroughly investigate reservations should be sought out to potentially increase willingness toward body donation.

continued on next page

VAN NULAND, Sonya E. and Natalie R. LANGLEY. Department of Anatomy, Mayo Clinic College of Medicine and Science, Mayo Clinic, Scottsdale, AZ, 85259, USA.
'Must See' Videos? Why Educators Need Better Video Analytics to Measure Learning.

INTRODUCTION. The pervasiveness of flipped classrooms and blended learning has tasked educators with creating content targeting fundamental concepts for asynchronous learning. The visual nature of anatomy subject matter makes video technology particularly well-suited to convey important relationships. Education technology companies purport that video analytics may provide educators insights into their learners and the effectiveness of their videos. This study examines this claim using analytics recorded by a learning video platform during a 7-week human anatomy course at the Mayo Clinic Alix School of Medicine (Arizona campus). METHODS. First-year medical students (n=48) were provided with daily faculty-guided videos (n=22) of prosected cadavers. The videos highlighted structures covered during laboratory sessions. Each video was released within 24-36 hours after the associated laboratory session. Video analytic data was recorded, including the number of times a video was viewed and played, average view time and the length of time a student watched a video before closing the page or pausing the video and never restarting it (drop-off rate). Multiple linear regression analysis was conducted using JMP software to examine the relationship between these video analytic variables and laboratory practical examination performance. SUMMARY. None of the video analytic variables were significant predictors of practical exam performance ($R2 = 0.024$, $p = 0.78$). CONCLUSIONS. The results of this study are consistent with previous analyses of the educational effectiveness of videos in anatomy courses, in spite of the company's claim that "videos can improve learning results". While videos may make education more accessible and engaging, the impact on student learning is difficult to determine using the basic metrics supplied by the video learning platform. Until more sophisticated video analytics become available, such data will remain of limited use to educational researchers.

WANG-SELFRIDGE, Angela A., Karen TONG, Youjin NA, and Anthony OLINGER. Department of Anatomy, Kansas City University of Medicine and Biosciences, Kansas City, MO, 64106, USA.
A Case of Osteopathia Striata with Cranial Sclerosis in a 75-Year-Old Female, a Cadaveric Approach.

INTRODUCTION. Osteopathia striata with cranial sclerosis (OSCS) is a rare X-linked dominant disorder characterized by linear striations in long bones with cranial sclerosis. It is associated with comorbidities such as cardiac, gastrointestinal, and genitourinary malformations. RESOURCES. OSCS has been described in detail in previous case reports, however, only in living patients. This case report aims to determine the impact, if any, of OSCS in cadaveric dissections due to its pathological effect on multiple body systems. DESCRIPTION. A 75-year-old female with a history of OSCS and myelodysplastic syndrome donated her body to the Gift Body Program at Kansas City University of Medicine and Biosciences. The cause of death was listed as cardiopulmonary arrest, sepsis, pneumonia, and acute myelocytic leukemia. Routine dissection revealed a significant bony protrusion on her cranium. SIGNIFICANCE. Upon completion of delineated dissection procedures, observations were made in multiple body systems. Abdominal dissection revealed a grossly enlarged liver and spleen—an observation that can be attributed to the patient's history of AML. Dissection of the head showed that the cranium was noticeably thicker than other craniums in the anatomy lab. Remaining systems showed no observable differences to other cadavers with no OSCS history. Despite the involvement of multiple organ systems, the lack of anatomic variation in this cadaver demonstrates that the majority of anatomical instruction is unlikely to be affected by a donor's medical history. The proportion of donors with multiple comorbidities can be of concern when teaching medical students human anatomy for the first time. Future research can aim to determine whether specific medical history is highly correlated with significant anatomical variations that may impede a medical student's anatomy studies.

WARD, Peter J., and Lindsey KENT. West Virginia School of Osteopathic Medicine, Lewisburg, WV, 24901, USA.
Medical History in the Curricula of American Medical Schools.

INTRODUCTION. This study examined the degree to which medical history is present in the curricula of American Medical Schools, how those sessions, if any, are delivered, and who delivers this content. We predicted that medical history would be present in some form in most medical schools but that very little history would be present in the mandatory curricula of American Medical Schools. We further hypothesize that the presentation of this content would be very diverse. METHODS. We compiled a contact list of deans and other curricular administrators at each institution using a previously-assembled list from an unrelated project at our institution. Respondents were also recruited from online discussion boards (e.g., Dr-Ed). Respondents completed a short survey on surveymonkey.com using Likert scale and free-response questions regarding the curriculum at their home institution. The project was granted IRB exemption in July 2018. SUMMARY. We received responses from 96 of the 209 institutions that were contacted (46.0% response rate). 30% of respondents indicated that their institution had mandatory sessions on medical history. These mandatory sessions were overwhelmingly delivered via lecture (88%) by a clinical faculty member (64%) with an average time of 6.5 hours (SD 9.7). 42% of respondents indicated

continued on next page

that their school had non-mandatory medical history sessions. These were delivered in lectures (74%) and/or small groups (48%) by a clinical faculty member (50%) with an average time of 9.6 hours (SD 11.5). CONCLUSIONS. Our hypothesis that very few schools would have mandatory sessions on medical history was somewhat supported, although 30% was a larger number than anticipated. There was significant diversity in the way this material was presented, and tremendous variation in the amount of time allotted.

WARD, Peter J. West Virginia School of Osteopathic Medicine, Lewisburg, WV, 24901, USA.
Interactive Digital Histology Sessions - A Method to Improve Student Engagement.

INTRODUCTION. Histology taught using microscopes was necessarily an interactive exercise between faculty and students as it posed both mechanical and content challenges. The increased use of digital histology in the classroom has added convenience to the process but in our experience, has decreased instructor-student interaction. To mitigate this, a series of interactive hunt-and-find games were included in the digital histology sessions. RESOURCES. Students used their school-issued laptops and software (Aperio) to view digital slides. DESCRIPTION. Students are given pre-class directed studies that guide them through the process of identifying the cells, tissues, and microscopic structures on their digital slides. During the in-class application sessions, students are asked a variety of questions regarding the content that was presented in the directed studies. Several “hunt-and-find” slides were included that asked students to find a specific structure, take a screen-shot, and email it to the instructor. The instructor tallied the submissions in real time and screened them based on 1. Accuracy of the image, 2. Speed of submission. The “winners” were those who submitted the greatest number of correct images in the fastest time. They received their choice of plush cell from giantmicrobes.com ®. SIGNIFICANCE. While a small subset of the class actively participated in these hunt-and-find events, those that did enjoyed it and valued the feedback that was sent regarding the accuracy of their submissions.

WIELE, Katie M., Jenny S. KAISER, Crystal R. LEMMONS, and Alla G. BARRY. Missouri Southern State University, Joplin, MO, 64801, USA.
Fibrous Metaplasia of Smooth Muscle Tissue of the Tunica Media in Tortuous Arteries.

INTRODUCTION. Tortuosity is the phenomenon of twisting and bending of blood vessels which, in severe cases, can lead to ischemia of distal organs. Despite this being a common condition that affects a wide range of blood vessels; its etiology is not widely understood. The prevalence of tortuosity is associated with several factors including age, hypertension, and diabetes mellitus. The present study was undertaken to identify changes in tunica media associated with tortuosity. METHODS. Eight formalin-preserved adult human cadavers were dissected at the MSSU cadaver suite. Gross morphological variations of the arteries were documented prior to tissue collection for histological examination. Sixteen extracranial internal carotid arterial samples were analyzed microscopically by staining with smooth muscle actin, collagen, fibroblast, and elastin antibodies as well as hematoxylin-eosin. SUMMARY. Histologically, the arteries in cadavers with tortuosity showed a decreased thickness of tunica media with signs of fibrous metaplastic transformation. Reduction of smooth muscle cells and elastic fibers replaced by connective tissue with fibroblast-like cells in tunica media were observed in affected blood vessels. Decreased amount of smooth muscle cells was apparent in the samples stained with smooth muscle actin antibodies. Immunofluorescence microscopy was used to objectively confirm our hypothesis. CONCLUSIONS. Confirming the presence of fibrous metaplasia in tortuous arteries could provide a basis for a deeper analysis of potential causes of metaplasia. Understanding the phenomenon of metaplasia in tortuosity along with triggering factors could lead to less invasive interventions of symptomatic tortuosity and ultimately, prevention of the disease.

continued on next page



for attending the 36th Annual Meeting

of the American Association of Clinical Anatomists in Tulsa, Oklahoma

We look forward to seeing you in New York City, New York in June of 2020!

For further information, please visit www.clinical-anatomy.org

InfoSight Corporation

"We BARCODE Difficult Stuff"™

American Association of Clinical Anatomists

ANNUAL MEETING

June 11-15, 2019 Tulsa, Oklahoma

BOOTH 14









Durable identification and traceability labeling that resists chemicals, heat and abrasion.

20700 US HWY 23 ~ Chillicothe, Ohio USA 45601 ~ 740-642-3600 ~ www.infosight.com