FORTY-THIRD

AMERICAN ASSOCIATION OF CLINICAL ANATOMISTS

ANNUAL MEETING



JUNE 12–15 2026

Rochester, MN

Hosted by Mayo Clinic | Rochester, MN

www.clinical-anatomy.org

MAYO CLINIC

PLATINUM SPONSOR — AACA ANNUAL MEETING

neuRealities

Your Expert. Always On Call.

Knowledge you can trust.

At the speed you need it.

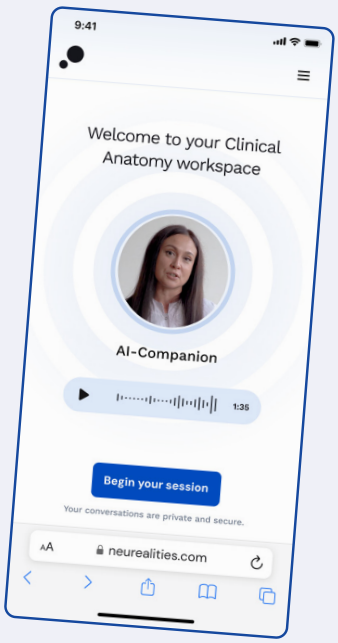

We're debuting something **new** at AACA — and we want **you** to be the first to experience it.

The Clinical Anatomy AI-Companion is a conversational AI platform that brings Mayo Clinic-verified anatomy education to life through natural dialogue. Whether you're a first-year resident or a seasoned clinician, it meets you at the point of care, adapting in real time, recalling prior conversations, and delivering accurate, evidence-based answers backed by Mayo Clinic's expertise.

- Voice-driven, natural conversation
- Delivers clinical anatomy expertise in context of clinical care
- Mayo Clinic-authenticated references and contextual media
- Available on desktop, tablet, and mobile

VISIT NEUREALITIES AT BOOTH 14

This is a preview exclusively for AACA members. Your hands-on feedback will help shape the future of this platform.

Experience it live.

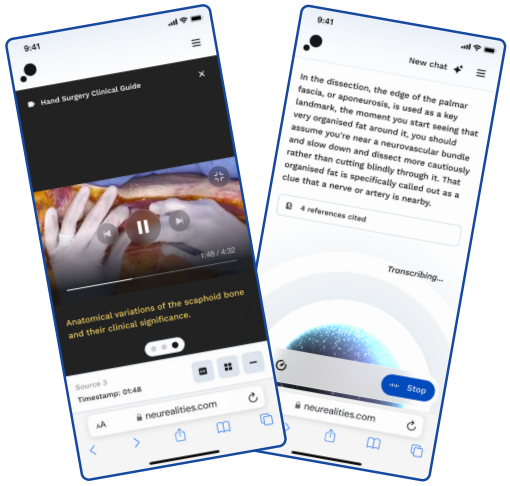

Learn more:
www.neurealities.com/AACA26

Table of Contents

President's Report 5-6
Mayo Map and Clinic Door Schedule 7-8
Annual Meeting Overview 9-10
Exhibitor Floor Plan and Exhibitors 11-13
Conference Sponsors & Member Donations 14
Conference Schedule 15-18
Honored Member – Carlos Andrés Suárez-Quian, Ph.D 19
Presidential Speaker – Charles J. Bruce, M.B., Ch.B. 20-21
Hands-On Workshop – St. George's University & Mayo Clinic 22-23
Dr.Oliver Beahrs Clinical Anatomy Masterclasses 24-26
Clinical Anatomy Fireside Discussion 27-28
Education Masterclass:
Evolving Clinical Anatomy Education: Integrating Pedagogy, Practice, and Technology 29
How Do You Deconstruct It? 30
Committee Meeting Descriptions 31-32
Committee Symposia Descriptions 33-34
Annual Business Meeting Agenda 35
Annual Business Meeting Minutes 36-40
2025-2026 AACA Council Members 41
Clinical Anatomy – the Official Journal of AACA 42-43
Committee Reports 44-54

- Anatomical Services Committee
- Ad hoc Diversity, Equity, and Inclusion Committee
- Career Development Committee
- Clinical Anatomical Terminology Committee
- Educational Affairs Committee
- Journal Committee
- Listserv Report
- Membership Committee
- MOPP Committee
- Nominating Committee

Abstract Listing by Author

- Platform Presentations 55
- TechFair Presentations 68
- Poster Presentations 73

The AACA believes that each conference attendee should be treated with respect and dignity and that any form of sexual harassment is a violation of human dignity. The AACA condemns sexual harassment and maintains a "zero - tolerance" for sexual harassment. All conference attendees have the right to participate and learn free of sexual harassment. The AACA will take all reasonable efforts to prevent and promptly correct instances of sexual harassment. Any conference attendee who believes himself or herself to be a victim of sexual harassment is encouraged to report the information to the Program Secretary.

CONNECT WITH US ON *social media*

SCAN ME

SCAN ME

SCAN ME

FACEBOOK

LINKEDIN

X "TWITTER"

STAY CONNECTED WITH AACA ON SOCIAL MEDIA FOR THE LATEST NEWS, EVENTS, NETWORKING OPPORTUNITIES, AND CONVERSATIONS WITH FELLOW MEMBERS AND PROFESSIONALS IN THE FIELD. FOLLOW US ON FACEBOOK, LINKEDIN, AND X TO ENGAGE WITH THE COMMUNITY AND STAY INFORMED YEAR-ROUND.

President's Report

June 12–15, 2026 AACA Annual Meeting

Dear Colleagues,

It is my privilege to welcome you to Mayo Clinic in Rochester, Minnesota, for the 2026 Annual Meeting of the American Association of Clinical Anatomists. In an era when travel presents no shortage of obstacles, your presence here speaks to your dedication to our discipline and to the profession we share.

This meeting carries particular significance, as the inaugural gathering of the AACA was convened here in Rochester in 1983. Mayo Clinic's enduring relationship with the AACA has been shaped by a distinguished lineage of surgeons and scientists who have served our organization with distinction: Dr. Oliver Beahrs, MD† (1983); Dr. Donald Cahill, PhD† (1993); Dr. Peter Amadio, MD (1995); and Dr. Robert Spinner, MD (2019) have each held the presidency, while Dr. Stephen Carmichael, PhD, DSc† provided many years of exemplary leadership as Editor-in-Chief of *Clinical Anatomy*. This legacy affirms the central role of clinical anatomy in patient care and its continued influence on the evolving landscape of clinical practice.

The meeting offers an exceptional opportunity for attendees to forge new connections and to experience firsthand the infrastructure Mayo Clinic has cultivated in support of innovation, discovery, and educational reform. The Department of Clinical Anatomy will host a series of open houses, together with a fresh tissue advanced clinical anatomy dissection laboratory led by Dr. Christopher Miller, MD (University of Pennsylvania), President of the American College of Mohs Surgery. In this session, clinical anatomists will observe the nuances of anatomical relevance as they manifest in everyday surgical practice. The Center for Biomedical Visualization and the 3D Printing Laboratory will demonstrate how anatomical expertise is harnessed for surgical planning and reconstruction, and attendees are warmly invited to walk the historic grounds of Saint Mary's and Mayo Clinic hospitals, where the healing ethos of a Three Shield institution—guided always by the principle that the needs of the patient come first—may be experienced at close hand.

Our Presidential Speaker, Dr. Charles Bruce, MBChB, 2023 Mayo Clinic Distinguished Inventor, serves, among many key leadership roles, as Professor of Medicine, Chief Innovation Officer, and Medical Director of the Innovation Exchange at Mayo Clinic in Florida. We eagerly anticipate Dr. Bruce's address, which promises to cultivate an innovator's mindset among us and illuminate the disciplines and dispositions required to become innovators within our own field.

In addition to the scientific presentations and hands-on biomedical visualization workshops selected from and presented by our membership, I am pleased to highlight our second Fireside Chat, led by Mr. Robert Morreale and titled *"When Trusted Knowledge Scales, Teaching Evolves: Architecting the Next Era of AI Enabled Clinical Anatomy Education,"* designed to provoke creative thinking around emerging AI tools. I am equally delighted to introduce the inaugural "*Dr. Oliver H. Beahrs Clinical Anatomy Masterclass*", a lecture series in which distinguished physicians and surgeons share practicebased advanced clinical anatomy aimed at optimizing patient care.

continued on next page

Our special education programming will further feature Dr. Roy Phitayakorn, MD MHPE MAMSE FACS speaking on "Raising a Foster Family: The Next Chapter in the Anatomist and Surgeon Relationship", Dr. Mohammed K. Khalil, DVM, M.S.Ed., Ph.D enlightening us on "Integrating Learning Theory into Competency-Based Anatomy Education" and Dr Elissa Hall Ed.D, Chair Elect Association of Medical Colleges sharing insights on curricular alignment for clinical education.

The CDC led by Dr. Ethan Snow will highlight "Benefits of Mentor-Mentee Relationships in Career Development" while Dr. Eiman Abdel Meguid, Ph.D will connect with us virtually to share insights on "Advancing EDI for Oral and Craniofacial Anatomy: Curriculum Diversification and Resource Development" . We are also pleased to welcome Pat Cichlar, who will guide an engaging discussion entitled *"The Value and Importance of Cadavers in Educational Bioskills Labs."*

This year's postgraduate course, led by neurosurgeon Dr. Maria Peris Celda, MD, PhD, will afford participants a surgeon's perspective on neuroanatomy, complemented by handson endoscopic approaches performed on Rhotonprepared skull base dissections.

I extend my sincere gratitude to every individual whose efforts have made this meeting possible, with particular appreciation to Caitlin Hyatt and the ASG team; our AACA Program Secretary, Dr. Kathleen Bubb, together with her team of meeting managers and the MOPP Committee; our 2026 Vendors and Exhibitors; Past President Dr. Shane Tubbs; Secretary Dr. Mohamed Khalil; the AACA Council; and Mr. Jacob Malwitz of Mayo Clinic, along with the Department of Clinical Anatomy Conference Planning Committee under the leadership of Mr. Jonathan Torrens-Burton.

I encourage each of you to use this opportunity to take ownership of the AACA—to engage, to contribute, and to seek opportunities to elevate the field of clinical anatomy as we continue to define our professional identity as Clinical Anatomists. It is an honor to host you at Mayo Clinic and to serve you as President of the AACA. We have much to accomplish together, and our success will be measured by the strength of our collective endeavor.

Warm Regards,



Nirusha Lachman, PhD
President, American Association of Clinical Anatomists

Mayo Map with Hotels Starred



Mayo Clinic Door Schedule

During weekdays, 8am – 5pm patient hours, attendees will be able to access the Siebens Building through the subway entrance and elevators. On street level, however, the doors are locked, so we have arranged for door attendants to staff the west entry doors. The Stabile Building is also badge-access only, so we will be asking students to help with that door.

Thursday, June 11

Noon – 4pm, Siebens Building: Door Operations Staff.

The AACA Council Meeting attendees need to be in the building by the time the meeting starts at 4pm. They can freely exit.

Noon – 4pm Stabile Building: Students.

Friday, June 12

7am – 11am, Siebens Building. Door Operations Staff.

If you leave the Siebens Building between 11am and 4pm, you will need to re-enter by entering the Mayo Building via patient access and walking to Siebens via the subway system

4pm – 8pm, Siebens Building. Door Operations Staff.

9am – 10am, 1pm – 4pm Stabile Building: Students.

Mayo Building (Judd Hall, Mayo subway): patient entrance.

Marriott Hotel: public entrance.

Saturday, June 13

7am – 5pm, Siebens Building. Door Operations Staff.

5pm – 9pm, for Geffen/Mayo/Gonda: Through Mayo Building, South Entrance. Door Operations Staff.

Noon – 5pm Stabile Building: Students.

Marriott Hotel: public entrance.

Sunday, June 14

7am – 5pm, Siebens Building. Door Operations Staff.

5pm – 9pm, Geffen/Landow/Gonda: Through Mayo Building, South Entrance. Door Operations Staff.

Marriott Hotel: public entrance.

Monday, June 15

7am – 11am, Siebens Building. Door Operations Staff.

1pm – 8pm Stabile Building: Students

2026 Annual Meeting - Mayo Clinic Rochester, MN

	Thursday, June 11	Friday, June 12		
		Registation Open 10:00 am - 5:00 pm **Registration Booth Phillips Hall**		
7:30	**Pre-Conference** **Explore Mayo & Rochester**	**Breakfast, Welcome Remarks & Presidential Speaker** **Dr. Charles Bruce** 7:30-9:15 am **Location: Phillips Hall, Siebens Building**		
7:45				
8:00			**Exhibitor Setup** 8:00 am - 12:00 pm **Location: Marriott Ballroom**	
8:15				
8:30				
8:45				
9:00				
9:15		**Open House** Radiology Integration 9:15-11:15am **Location: Stabile 9, Stabile Building**		
9:30				
9:45				
10:00				
10:15				
10:30				
10:45				
11:00				
11:15		**Student Platform Presentations** 11:15am - 12:30pm **Location: Phillips Hall, Siebens Building**		
11:30				
11:45				
12:00				
12:15				
12:30				
12:45			**CDC Lunch Meeting** 12:45-1:45 pm **Location: Phillips Hall, Siebens Building**	
1:00	**Open House** 1:00 - 4:00pm Department of Clinical Anatomy Laboratory and Studio **Location: Stabile 9, Stabile Building**	**Open House** 1:00 pm - 4:00 pm Department of Clinical Anatomy Laboratory and Studio **Location: Stabile 9, Stabile Building**		
1:15				
1:30				
1:45				
2:00	**Registration Open** 1:00 - 4:00 pm **Location: Phillips Hall Registration Booth**		**Sculpting Anatomical Relationships** 2:00-3:30 pm **Location: Phillips Hall, Siebens Building**	**Dr. Oliver H. Beahrs Clinical Anatomy Masterclass 1: Injuries and Ultrasound Guided Procedures** 2:00-3:00 pm **Location: Judd Hall, Gonda Building**
2:15				
2:30				
2:45				**Dr. Oliver H. Beahrs Clinical Anatomy Masterclass 2: Face Transplant Surgery** 3:00-3:30pm **Location: Judd Hall, Gonda Building**
3:00				**3D Slicer-BEG to ADV** 2:00-3:30 pm **Location: Leighton Auditorium**
3:15				
3:30				
3:45			**Student Poster Session A with Exhibitors** 3:45-5:00 pm **Location: Marriott Ballroom**	
4:00	**AACA Council Meeting (25 people)** 4:00 - 6:00 pm **Location: Siebens Grumman Lecture Hall**			
4:15				
4:30				
4:45				
5:00				
5:15				
5:30				
5:45				
6:00		**Welcome Reception** 6:00 pm - 7:30 pm **Location: Hage Atrium, Siebens Building**		
6:15				
6:30				
>7 pm				

2026 Annual Meeting continued

	Saturday, June 13 Registration Open 7:30 am - 5:00 pm Registration Booth Phillips Hall	Sunday, June 14 Registration Open 7:30 am - 5:00 pm Registration Booth Phillips Hall	Monday, June 15 Registration Open 7:30 am - 1:00 pm Registration Booth Phillips Hall
7:30	**CAT Breakfast Meeting** 7:30 - 8:30 am **Location: Phillips Hall**	**EAC Breakfast Meeting** 7:30 am - 8:30 am **Location: Phillips Hall**	**Croissants & Coffee with Exhibitors** 7:30 am - 9:00 am **Location: Marriott Ballroom**
7:45			
8:00			
8:15			
8:30			
8:45	**Platform Session 2** 8:45 am - 10:00 am **Location: Phillips Hall, Siebens Building**		
9:00		**Dr. Oliver H. Beahrs Clinical Anatomy Masterclass 3: Interventional Neuroradiology, Imaging and Cutaneous Surgery** 9:00 am - 10:30 am **Location: Phillips Hall** **Vendor Showcase** 9:00 am - 10:30 am **Location: Leighton Auditorium**	**Dr. Oliver H. Beahrs Clinical Anatomy Masterclass 6: Craniofacial Planning & Reconstruction, Neurosurgical Navigation** 8:45 am - 10:15 am **Location: Phillips Hall** **Education Masterclass: Evolving Clinical Anatomy Education: Integrating Pedagogy, Practice, and Technology** 8:45 am - 10:15 am **Location: Leighton Auditorium**
9:15			
9:30			
9:45			
10:00			
10:15	**Platform Session 3** 10:15 am - 11:15 am **Location: Phillips Hall**		
10:30			**How do you Reconstruct it?** 10:30 AM - 12:00 PM **Location: Phillips Hall**
10:45		**ASC Symposium - The Value & Importance of Cadavers in Educational Bio Skills Labs** 10:45 am - 12:15 pm **Loaction: Phillips Hall**	
11:00			
11:15			
11:30	**DEIC Meeting** 11:30 - 12:30pm **Location: Phillips Hall**		
11:45			
12:00	**Open House: Anatomy and Flaps for MOHS Reconstruction** 12:00 pm - 5:00 pm **Location: Stabile 9**	**Clinical Anatomy Editorial Board Meeting** 12:00 - 1:30 PM **Siebens 04-09**	**AACA New Council Meeting** 12:00 pm - 1:00 pm **Location: Siebens 04-05A** Conference Adjourns - 1:00 pm
12:15			
12:30			
12:45	**ASC Lunch Meeting** 12:45-1:45 pm **Location: Phillips Hall**	**AACA Annual Business Meeting with Lunch** 12:30-1:45 pm **Location: Phillips Hall**	
1:00			**Post Graduate Course** **Rhoton Program:** Head and Neck, Skull Base and Endoscopic Anatomy 1:00 pm - 5:00 pm **Location: Stabile 9** (Limited Spots 20-40)
1:15			
1:30			
1:45			
2:00	**Poster Session B with Exhibitors** 2:00-3:15 pm **Location: Marriott Ballroom**	**Platform Session 5** 2:00-3:15pm **Location: Phillips Hall**	
2:15			
2:30			
2:45			
3:00			
3:15			
3:30	**Platform Session 4 (Tech Fair)** 3:30 pm - 4:30 pm **Location: Phillips Hall**	**Dr. Oliver H. Beahrs Clinical Anatomy Masterclass 4: Gynecological Surgery** 3:30-4:30pm **Location: Phillips Hall**	
3:45			
4:00			
4:15			
4:30			
4:45	**EAC Symposium - Raising a Foster Family — The Next Chapter in the Anatomist and Surgeon Relationship** 4:45 pm - 6:15 pm **Location: Phillips Hall**	**Dr. Oliver H. Beahrs Clinical Anatomy Masterclass 5: Surgical Anatomy of the Supine Hip** 4:45 - 5:30 pm	
5:00			
5:15			
5:30			
5:45			
6:00		**Banquet and Awards** 6:00-9:00 pm **Reception: Chihuly Glass Atrium** **Awards: Geffen Auditorium** **Dinner: Landow Atrium (Gonda)**	
6:15			
6:30	**FIRESIDE CHAT - Driving Experiential Learning - Innovations and AI** 6:30 - 8:00 pm **Location: Geffen/ Matthews Lobby, Gonda Building**		
>7 pm			

Exhibitor Floor Plan

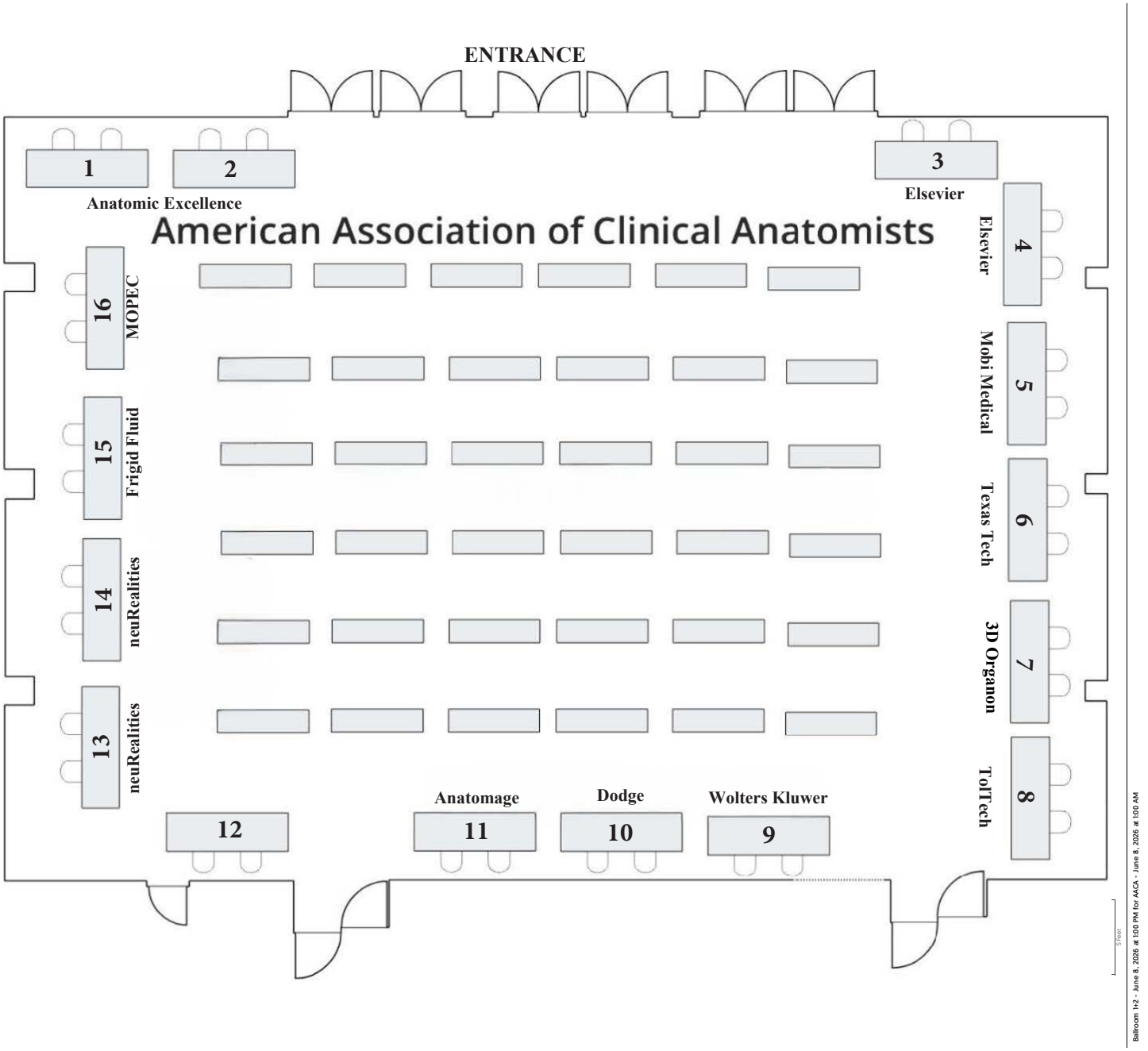

Sponsors/Commercial Exhibitors at a Glance

Generous donations and/or commercial exhibitor fees paid by the following companies and organizations have substantially reduced the Association's expenses in presenting this meeting.
You are encouraged to visit the exhibits available for viewing in Marriott Ballroom.

EXHIBIT HOURS:

FRIDAY, JUNE 12, 2026
8:00 am – 12:00 pm Exhibitor Set Up
2:30 pm – 5:00 pm Commercial Exhibits

SATURDAY, JUNE 13, 2026
1:00 pm – 5:00 pm Commercial Exhibits

SUNDAY, JUNE 14, 2026
9:00 - 10:30 am Vendor Showcase (Mayo Clinic)
1:00 - 4:30 pm Commercial Exhibits

MONDAY, JUNE 15, 2026
7:30 am – 9:00 am Croissants & Coffee with Exhibitors

TEAR DOWN is from 10:00 am – 4:00 pm on Monday, June 15, 2026 (all exhibitors must be vacated from the hall at 4:00 pm)

LIST OF EXHIBITORS (as of 4.28.2026)

3D Organon
Booth #7

One World Trade Center
New York, NY 10007
USA
www.3dorganon.com
Immersive Medical Software Education

Anatomage
Booth #11

3350 Thomas Rd. Suite 150
Santa Clara, CA 95054
USA
www.anatomage.com
Anatomage is a medical company, driving innovation through advanced solutions in hospitals and educational institutions. Our digital cadaver table, the Anatomage Table, allows a hands-on approach to learning the human body through unique visualization options, dissection tools, and quiz mode features, making it a strong asset to any anatomy class.

Anatomic Excellence, LLC | von Hagens Plastination
Booth # 1 & 2

22 Angel Oaks Dr
Savannah, GA 31410
USA
www.anatomicexcellence.com
Anatomic Excellence is the exclusive, full range agent for Dr. Gunther von Hagens. Plastinated Human Tissue Specimens in the USA, Canada, and Caribbean. Our purpose-led team is committed to working with our education colleagues in order to assist them in establishing a collection of ethically procured and prepared specimens that enhance the learning opportunities for their anatomic, medical, and healthcare professionals.

Dodge
Booth #10

9 Progress Rd.
Billerica, MA 08121
USA
www.shop.dodgeco.com
Embalming chemicals, instruments, cosmetics, and supplies

continued on next page

Elsevier
Booth # 3 & 4

1600 John F Kennedy Blvd. Suite 1600
Philadelphia, PA 19103
USA
https://www.elsevier.com/education/welcome-3d4medical
Every day, research and health professionals dedicate themselves to improving outcomes for communities, patients and society at large. Elsevier is committed to quality and innovation to improve the value we deliver to researchers, research leaders, healthcare professionals and educators in an open, inclusive and collaborative manner

Frigid Fluid
Booth #15

11631 W. Grand Ave.
Northlake, IL 60164
USA
www.frigidfluid.com
Embalming machine, embalming fluids, anatomical solutions, and casket lowering devices.

Mopec
Booth #16

800 Tech Row
Madison Heights, MI 48071
USA
www.mopec.com
Empowering pathology & anatomy professionals with the leading platform of products and solutions for the advancement of diagnostic accuracy, safety, research, education, and the treatment of disease.

MobiMedical
Booth #5

1 Mauney Court
Columbia, SC 29201
USA
www.medicalstretchers.com
Anatomy Tables, Storage Racks, Embalming Sinks, Coolers

neuRealities
Booth # 13 & 14

202 4 St SW, Suite 100
Rochester, MN 55902
USA
www.neuRealities
neuRealities is *pioneering* Al-powered medical education solutions that transform how clinicians and students learn, practice, and retain complex medical knowledge. neuRealities is proud to debut an exclusive Clinical Anatomy Al Companion proof of concept, developed with the Mayo Clinic, during the MCA Annual Meeting. MCA members are invited to interact with the Clinical Anatomy Al Companion firsthand and share feedback that will directly inform its continued development.

Toltech
Booth #8

12635 E. Montview Blvd. Suite 350
Aurora, CO 80045
USA
www.toltech.net
Learning isn't easy. But with Toltech's comprehensive, immersive platform that features true-to-life visualizations and expert-level support, anatomy education becomes more accessible, impactful, and effective.

Wolters Kluwer
Booth #9

2001 Marker Street
Philadelphia, PA 19103
USA
www.lww.com
Medical Books

2026 Annual Meeting Sponsors

Platinum Level

neuRealities

Gold Level

Anatomic Excellence

Bronze Level

Wolters Kluwer

Scan the QR code to donate.

We would like to thank our 2025 and 2026 Donors:

Ronn Wade, PhD
Robert J. Spinner, MD

Conference Schedule

Friday, June 12, 2026

TIME	ACTIVITY	LOCATION	DETAILS
7:30 – 8:00 AM	**Breakfast**	*Phillips Hall, Siebens Building*	Open to All
8:00 – 8:15 AM	**Welcome Remarks**	*Phillips Hall, Siebens Building*	Open to All
8:15 – 9:00 AM	★ **Presidential Speaker: The Anatomy of Innovation**	*Phillips Hall, Siebens Building*	Dr. Charles Bruce
8:00 AM – 12:00 PM	**Exhibitor Setup**	*Marriott Ballroom, Rochester Marriott*	*Exhibitors Only*
9:15 – 11:15 AM	**Open House: Radiology Integration**	*Stabile 9, Stabile Building*	Drs. Gavin McKenzie & Ahmad Parvinian
11:15 AM – 12:30 PM	**Student Platform Presentations**	*Phillips Hall, Siebens Building*	Open to All
11:15 AM – 3:00 PM	**Poster Setup**	*Marriott Ballroom, Rochester Marriott*	Open to All
12:45 – 1:45 PM	**CDC Lunch Meeting**	*Phillips Hall, Siebens Building*	Open to All
1:00 – 4:00 PM	**Open House**	*Stabile 9, Stabile Building*	Dept. of Clinical Anatomy Lab & Studio
2:00 – 3:00 PM	**Dr. Oliver H. Beahrs Masterclass 1: Injuries & Ultrasound-Guided Procedures**	*Judd Hall, Gonda Building*	Drs. Jacob Sellon & Brennan J. Boettcher
2:00 – 3:30 PM	**Sculpting Anatomical Relationships in Clay Workshop**	*Phillips Hall, Siebens Building*	Wes Price; Christian Hansen
2:00 – 3:30 PM	**3D Slicer – Beginner to Advanced Workshop**	*Leighton Auditorium, Siebens Building*	David Nahabedian
3:00 – 3:30 PM	**Dr. Oliver H. Beahrs Masterclass 2: Face Transplant Surgery**	*Judd Hall, Gonda Building*	Dr. Samir Mardini
3:45 – 5:00 PM	**Student Poster Session A with Exhibitors**	*Marriott Ballroom, Rochester Marriott*	Open to All
6:00 – 7:30 PM	★ **Welcome Reception**	*Hage, Siebens Building*	Dr. Nneka Comfere

continued on next page

Saturday, June 13, 2026

TIME	ACTIVITY	LOCATION	DETAILS
7:30 – 8:30 AM	**CAT Committee Breakfast Meeting**	*Phillips Hall, Siebens Building*	Open to All
8:45 – 10:00 AM	**Platform Session 2**	*Phillips Hall, Siebens Building*	Open to All
10:15 – 11:15 AM	**Platform Session 3**	*Phillips Hall, Siebens Building*	Open to All
11:30 AM – 12:30 PM	**DEIC Meeting**	*Phillips Hall, Siebens Building*	Open to All
12:00 – 1:30 PM	**Clinical Anatomy Editorial Board Meeting**	*Siebens 4-09 Conference Room*	*Invitation Only*
12:00 – 5:00 PM	**Open House** **★Advanced Anatomy for Superficial Surgery of the Face**	*Stabile 9, Stabile Building*	*Pre-registration Required*
12:45 – 1:45 PM	**ASC Lunch Meeting**	*Phillips Hall, Siebens Building*	All Invited
2:00 – 3:15 PM	**Poster Session B with Exhibitors**	*Marriott Ballroom, Rochester Marriott*	Open to All
3:30 – 5:00 PM	**Poster Tear Down**	*Marriott Ballroom, Rochester Marriott*	Open to All
3:30 – 4:30 PM	**Platform Session 4 (Tech Fair)**	*Phillips Hall, Siebens Building*	Open to All
4:45 – 6:15 PM	**EAC Symposium: Raising a Foster Family — The Next Chapter in the Anatomist and Surgeon Relationship**	*Phillips Hall, Siebens Building*	Dr. Roy Phitayakorn
6:30 – 8:00 PM	**★ Fireside Chat: Experiential Learning, Innovations & AI**	*Geffen/Matthews Lobby, Gonda Building*	Bob Morreale; Dan Donovan; Derrick Connell; Dr. Walter Greenleaf

continued on next page

Sunday, June 14, 2026

TIME	ACTIVITY	LOCATION	DETAILS
7:30 – 8:30 AM	**EAC Breakfast Meeting** **Integrating Learning Theory into Competency-Based Anatomy Education**	*Phillips Hall, Siebens Building*	Dr. Mohammed K. Khalil
9:00 – 10:30 AM	**Dr. Oliver H. Beahrs Masterclass 3: Interventional Neuroradiology, Imaging and Cutaneous Surgery**	*Phillips Hall, Siebens Building*	Drs. Waleed Brinjikji, Vance Lehman, Kevin Christensen
9:00 – 10:30 AM	**Vendor Showcase**	*Leighton Auditorium, Siebens Building*	Open to All, *Mandatory for Council Members*
10:45 AM – 12:15 PM	**ASC Symposium: The Value & Importance of Cadavers in Educational Bio Skills Labs**	*Phillips Hall, Siebens Building*	Pat Cichlar Alexander
12:30 – 1:45 PM	**AACA Annual Business Meeting with Lunch**	*Phillips Hall, Siebens Building*	Open to AACA Members
2:00 – 3:15 PM	**Platform Session 5**	*Phillips Hall, Siebens Building*	Open to All
3:30 – 4:30 PM	**Dr. Oliver H. Beahrs Masterclass 4: Gynecological Surgery**	*Phillips Hall, Siebens Building*	Drs. Anetta Madsen, Carrie Langstratt
4:45 – 5:30 PM	**Dr. Oliver H. Beahrs Masterclass 5: Supine Hip**	*Phillips Hall, Siebens Building*	Dr. Mario Hevesi
6:00 – 7:00 PM	★ **Reception**	*Chihuly Glass Atrium*	Open to All
7:00 – 9:00 PM	★ **Awards & Dinner**	*Landow Atrium, Gonda Building*	Open to All

Monday, June 15, 2026

TIME	ACTIVITY	LOCATION	DETAILS
7:30 – 9:00 AM	**Croissants & Coffee with Exhibitors**	*Marriott Ballroom, Rochester Marriott*	Open to All
8:45 – 10:15 AM	**Clinical Anatomy Masterclass 6: Craniofacial Planning & Reconstruction, Neurosurgical Navigation**	*Phillips Hall, Siebens Building*	Drs. Basel Sharaf, Waleed Gibreel, Kendall Lee
8:45 – 10:15 AM	**Education Masterclass: Integrating Pedagogy, Practice & Technology**	*Leighton Auditorium, Siebens Building*	Dr. Elissa Hall
10:30 AM – 12:00 PM	**Platform Session 6: How Would You Deconstruct It?**	*Phillips Hall, Siebens Building*	Drs. Nahid Vidal, Yolanda Salinas, Jon Christensen, Punnose Kattil, Samesh Lachman, Antonio Rivera-Perez, Joe Iwanaga, Nirusha Lachman
12:00 PM	★ **Conference Adjourns**		
12:00 – 1:00 PM	**AACA New Council Meeting**	*Siebens 4-05A Siebens Building*	*Invitation Only*
1:00 – 5:00 PM	★ **Post-Graduate Course: Rhoton Program**	*Stabile 9, Stabile Building*	*Pre-registration Required*

Honored Member 2026

The American Association of Clinical Anatomists Recognizes and Awards Honored Membership to

Carlos Andrés Suárez-Quian, PhD



Carlos A. Suárez-Quian, Ph.D., is an *Emeritus* Professor in the Department of Biochemistry and Molecular and Cellular Biology at the Georgetown University School of Medicine. His teaching expertise is in clinical gross anatomy where he served as gross anatomy discipline director of the first- and fourth-year medical school curriculum for over 20 years. He is also a published textbook author, speaker, visiting faculty member, and consultant on clinical gross anatomy programs around the world. Dr. Suárez' was a funded research scientist with a concentration in cell and molecular biology, during which time he published more than 60 papers in peer-reviewed journals, including for a technique he pioneered called "laser capture microdissection." He was a founding member and co-director of the Georgetown Medical Center Mini Medical School Program for over 25 years. Dr. Suárez-Quian served as one of 15 national judges for the annual Regeneron Science Competition (formerly Intel) that awards over 1.5 million in scholarships to high school seniors, now in its 78th year.

Dr. Suárez-Quian's teaching awards include the Golden Apple and the Geza Illes Award in Gross Anatomy, and the Kaiser-Permanente Teaching Award granted by his faculty peers. In May 2008, Dr. Suárez-Quian was inducted into the MAGIS Society of Master Teachers, the highest award Georgetown bestows on a faculty member at the Medical School. He is the author of the *Online Guided Gross Anatomy Dissector* (Oxford University Press, 2014), and co-author of *The Clinical Anatomy of the Cranial Nerves*, by J.A. Vilensky, W.M. Robertson and C.A. Suárez-Quian (Wiley, 2015). He published the eight-book series of *All-in-One Anatomy Exam Review: Image-Based Questions and Answers* with his co-author, Dr. Vilensky. He is also the co-author of *Functional Anatomy For Occupational Therapy* (Books of Discovery Press, 2022), now in over 140 programs nationwide.

A native of La Habana, Cuba, Dr. Suárez came to the United States as a political refugee when he was seven years old. He is the son of Andrés Suárez and Hortensia Quian. He grew up in Miami and Gainesville, Florida, earned his B.S. at the University of North Carolina at Chapel Hill, did his graduate work at the Harvard University Medical School, and his post-doctorate work at the National Institute of Child Health and Human Development. Despite being Cuban, he does not enjoy cigars.

Previous Honored Member Award Recipients

1984 – W. Henry Hollinshead*
1985 – Chester B. McVay*
1986 – Donald James Gray*
1987 – Russell T. Woodburne*
1988 – Oliver Beahrs*
1989 – N. Alan Green*
1990 – Frank H. Netter*
1991 – Ralph Ger*
1992 – M. Roy Schwarz
1993 – Carmine D. Clemente*
1994 – Keith L. Moore*
1995 – Ray J. Scothorne*
1996 – Robert A Chase*
1997 – Tatsuo Sato
1998 – John E. Skandalakis*
1999 – Donald R. Cahill*
2000 – Sandy C. Marks, Jr.*
2001 – David G. Whitlock*
2002 – Robert D. Acland*
2003 – Arthur F. Dalley, II
2004 – John V. Basmajian*
2005 – Ian Whitmore
2006 – Peter H. Abrahams
2007 – Gary Wind
2008 – T.V.N. (Vid) Persaud
2009 – Richard S. Snell
2010 – Raymond F. Gasser
2011 – Harold Ellis*
2012 – Ronald A. Bergman
2013 – John Hansen
2014 – Victor M. Spitzer
2015 – Carol E. Scott-Conner
2016 – Carlos Machado
2017 – James D. Collins*
2018 – Anne Agur*
2019 – Robert Anderson
2020 – Stephen W. Carmichael*
2021 – Susan Standring
2022 – Cornelius Rosse
2023 – Bernell Dalley
2024 – Michael Nolan
2025 – Robert J. Spinner

** deceased*

Presidential Speaker

Charles J. Bruce, M.B., Ch.B.



The Anatomy of Innovation

Innovation is often viewed through the lens of technology, entrepreneurship, and commercialization. Yet its origins are far more fundamental. As anatomists seek to understand the relationships between structures that enable life — through layered understanding, spatial reasoning, and precise observation — innovators seek to understand the relationships between unmet needs, observations, ideas, people, and systems that enable progress. Drawing on experiences as a cardiologist, physician-inventor, and healthcare innovation leader, this presentation explores the common principles that underpin both anatomy and innovation. Through real-world examples, attendees will examine how careful observation, layered thinking, interdisciplinary collaboration, and curiosity drive transformative advances in healthcare. The presentation will also consider how emerging technologies such as artificial intelligence and robotics are reshaping medicine — and why anatomical thinking may become even more important in the future of healthcare.

Charles J. Bruce, M.B., Ch.B., is a consultant in the Division of Cardiovascular Diseases, Department of Internal Medicine, at Mayo Clinic in Florida. Dr. Bruce is chief innovation officer at the Florida campus and medical director of the Mayo Clinic Berg Innovation Exchange in Florida. In addition, he is an associate medical director in the Department of Development. He joined the staff of Mayo Clinic in 2001 and holds the academic rank of professor of medicine at Mayo Clinic College of Medicine and Science.

Dr. Bruce completed his medical studies, as well as an internship and residency in internal medicine, at Groote Schuur Hospital, University of Cape Town, South Africa. He subsequently completed a residency in internal medicine and a fellowship in cardiology at Mayo Clinic and was a Mayo Foundation Scholar.

Dr. Bruce's early research interests centered on exploring applications for a novel ultrasound-tipped catheter developed at Mayo Clinic, as well as current and future cardiovascular applications of ultrasound technology and clinical cardiovascular

continued on next page

research employing novel ultrasound technologies. Currently, he is working on the development and integration of novel sensor technologies and the application of artificial intelligence to sensed data to create digital fingerprints of diseases, as well as developing a novel at-home dermatology AI diagnostic platform. He has served as principal investigator and co-investigator for research funded by the American Heart Association and the National Institutes of Health. Dr. Bruce, in partnership with colleagues, holds 76 issued domestic and foreign patents and was named a Distinguished Mayo Clinic Inventor in 2023.

Dr. Bruce has given invited presentations throughout the world and has authored numerous peer-reviewed articles, as well as book chapters, editorials, abstracts, and letters. In addition, he has held reviewer and editorial responsibilities for several prominent publications.

In addition to his clinical and research activities, Dr. Bruce is active in education and has provided mentorship to medical students, residents, and fellows. He has been recognized with teaching awards, including the Teacher of the Year Award. Dr. Bruce has also served on multiple committees at Mayo Clinic and is currently a member of the Executive Operations Team in Florida.

Dr. Bruce is a fellow of the American College of Cardiology, the South African College of Physicians, and the American Society of Echocardiography, where he has served on leadership committees, including the Scientific Sessions Committee, Guidelines and Standards Committee, and Bylaw and Ethics Committee. He also served as presidential consultant for the Scientific Sessions Committee. Dr. Bruce currently serves as chair of the Board of Directors of BioFlorida.

Hands-On Workshops

June 12, 2026 | 2:30PM – 3:30PM

Sculpting Anatomical Relationship in Clay Workshop with Charles "Wes" Price, MSMI, CMI, FAMI and Christian Hanson

Location: Phillips Hall
Siebens Building

This hands-on workshop is designed for anatomy professionals and learners of all skill levels—from non-artists to experienced sculptors. Led by 3D artists Christian Hanson and Wes Price, the session invites participants to step away from digital tools and reconnect with anatomy through tactile, creative exploration. Using 3D-printed patient-derived models as a foundation, attendees will sculpt in clay to better understand anatomical form, proportion, and spatial relationships.

Through guided instruction, participants will sharpen visual perception, eye-hand coordination, and anatomical awareness while adding their own creative interpretation to the model. Everyone will leave the workshop with a personalized clay-enhanced anatomical piece—along with a refreshed appreciation for hands-on learning.

(All materials are provided, and no prior sculpting experience is required.)



Charles 'Wes' Price, MSMI, CMI, FAMI
Senior Director, Division of Biomedical and Scientific Visualization
Mayo Clinic



Christian Hanson
Simulation Engineer, Special Effects Designer, Anatomical Modeling Unit, Radiology
Mayo Clinic

continued on next page

3D Slicer-Beginner to Advanced Workshop with David Nahabedian, MSMI, CMI

Location: Leighton Auditorium
Siebens Building

3D Slicer is free, open-source, and commonly used application across the medical field. It is especially useful in the process of creating 2D and 3D assets for research presentations, publications, and posters. This workshop will target members with beginner and intermediate levels of experience with 3D Slicer and showcase its capabilities. Participants will review and use the volume rendering and segmentation methods from last years' workshop and expand on these skills. Participants will learn how to make more complex segmentations and multiple-layered volume renderings. The outcome of this workshop will be to empower and guide researchers to use 3D Slicer as a tool in their research and promote its use in creating research figures for publications or even using it to teach.Before class, participants would need to download the 3D Slicer program to their laptops.The software described can be found at:https://www.slicer.org/Attendees will be provided with a 'cheat sheet' after the session that encompasses and condenses the content.

Outcomes:

- Basic understanding of a 3D model vs volume rendering
- Ability to create a simple 3D model (segmentation) and basic volume rendering
- Ability to use the segment editor and volume rendering modules



David Nahabedian, MSMI, CMI
Assistant Director and Senior Medical Illustrator
St. George's University

Dr. Oliver H. Beahrs Clinical Anatomy Masterclass 1:

Sports Medicine Injuries and Ultrasound Guided Procedures

Thursday, June 12, 2026 | 2:00 pm – 3:00 pm

Judd Hall
Ghonda Building



Jacob L. Sellon MD



Brennan J. Boettcher, D.O.

Dr. Oliver H. Beahrs Clinical Anatomy Masterclass 2:

Face Transplant and Reinnervation Surgeries

Thursday, June 12, 2026 | 3:00 pm – 3:30 pm

Judd Hall
Ghonda Building



Samir Mardini, MD

continued on next page

Dr. Oliver H. Beahrs Clinical Anatomy Masterclass 3:

Interventional Neuroradiology, Imaging and Cutaneous Surgery

Sunday, June 14, 2026 | 9:00 am – 10:30 am

Phillips Hall
Siebens Building



Vance T. Lehman, PhD



Kevin Christensen, MD



Waleed Brinjikji, MD

Dr. Oliver H. Beahrs Clinical Anatomy Masterclass 4:

Gynecological Surgery

Sunday, June 14, 2026 | 3:30 pm – 4:30 pm

Phillips Hall
Siebens Building



Annetta M. Madsen, MD



Carrie L. Langstraat, MD

continued on next page

Masterclass 5

Surgical Anatomy of the Supine Hip – Arthroscopy, Open and Beyond

Sunday, June 14, 2026 | 4:45 pm – 5:30 pm

Phillips Hall
Siebens Building



Mario Hevesi, MD, PhD

Masterclass 6

Craniofacial Planning & Reconstruction, Neurosurgical Navigation

Sunday, June 14, 2026 | 4:45 pm – 5:30 pm

Phillips Hall
Siebens Building



Waleed Gibreel, M.B.B.S.



Basel A. Sharaf, MD, D.D.S.



Kendall H. Lee, MD, PhD

Fireside Chat

Driving Experiential Learning - Innovations and AI

Saturday, June 13th | 6:30 pm - 8:00 pm

Geffen/Matthews Lobby
Ghonda Building



Bob Morreale
Senior Division Chair, Immersive and Experiential Learning, Mayo Clinic
linkedin.com/in/bobmorreale

Bob Morreale leads Immersive and Experiential Learning at Mayo Clinic and is cofounder and head of innovation at neuRealities. His work sits where emerging capabilities and intelligent systems must earn adoption in environments that demand trust. At Mayo Clinic, he integrates simulation-based learning, procedural training, clinical anatomy, biomedical and scientific visualization, and immersive technologies into a shared platform to support medical education and workforce training. He also partners to lead AI education at Mayo Clinic through the Harper Family Foundation AI Education in Medicine Program. Bob holds the academic rank of assistant professor of biomedical communications at Mayo Clinic College of Medicine and Science.

At neuRealities, Bob helps shape product strategy, evidence, and partnerships to advance AI-enabled immersive learning. Before Mayo Clinic, Bob helped build CTSNet and MedBiquitous at Johns Hopkins Medicine, two early digital platforms in medical knowledge sharing. He also held academic posts at the Cleveland Institute of Art and a joint appointment at Case Western Reserve University and Cleveland Clinic.

Bob is a board-certified medical illustrator and a fellow of the Association of Medical Illustrators. The craft of visual storytelling has shaped his career in academic medicine and venture opportunities in healthcare.



Dan Donovan
Head of AI, neuRealities
linkedin.com/in/ddonovan312

Dan Donovan serves as head of AI at neuRealities, a knowledge platform launched in collaboration with Mayo Clinic, where trusted information meets scalable AI innovation to advance how organizations learn and train. In this role he directs the technical strategy behind the company's AI applications, including the development of specialized AI agents trained in secure, explainable knowledge environments. His focus is on the infrastructure required for safe and effective AI deployment in enterprise and regulated industries, including healthcare.

Before his current role, Dan served as group chief technology officer at Mesmerise Group, where he led the development of AI systems powering digital human avatars and immersive learning environments. Earlier, as managing director and chief technology officer of EY Comply at Ernst & Young, he led the financial services regulatory reporting software platform for the firm's managed services practice, overseeing a global product organization of more than 100 professionals across the United States, Europe, South America, and India.

Dan's career spans more than two decades across enterprise software, AI architecture, and the scalable deployment of intelligent systems in regulated industries.

continued on next page



Derrick Connell
Former Corporate Vice President, Search and AI, Microsoft
linkedin.com/in/derrickc

Derrick Connell retired from Microsoft in 2020 as corporate vice president for the company's Search and AI portfolio, concluding a 28-year career during which he led worldwide product strategy, design, and engineering for Bing, Cortana, and related services used by hundreds of millions of people. He also served as a technology advisor to Microsoft chief executive officer Satya Nadella.

Derrick is the founder of an AI and human rights nonprofit initiative that he launched during an extended leave from Microsoft, exploring how artificial intelligence can advance global human rights. Since retiring, he has worked as a product and strategy advisor to companies worldwide, with an emphasis on search, artificial intelligence, and virtual reality. His active advisory portfolio includes Ocado Technology and neuRealities, where he contributes to product and technology strategy as the company develops spatial computing and AI capabilities for healthcare and enterprise customers.



Walter Greenleaf, PhD
Neuroscientist, Stanford University
linkedin.com/in/waltergreenleaf

Walter Greenleaf is a neuroscientist and medical technology developer widely regarded as a leading authority on the clinical application of virtual reality. Over more than 35 years at the intersection of neuroscience, immersive technology, and digital health, he has pioneered the use of VR for treatment and rehabilitation of post-traumatic stress, stroke, traumatic brain injury, anxiety, addiction, and autism spectrum disorders. His early work with VPL Research in the 1980s helped establish the foundation for therapeutic VR as a clinical field.

Walter serves as the Neuroscience Clinical Applications Expert at the Stanford Virtual Human Interaction Lab and directs innovation efforts at the Stanford Medical Mixed Reality Center. He has cofounded and advised numerous clinical product companies including Pear Therapeutics, Abbott Medical, and MindMaze, and chairs the International Virtual Reality Healthcare Association. He also serves as a strategic advisor to neuRealities.

Education Masterclass

Evolving Clinical Anatomy Education: Integrating Pedagogy, Practice, and Technology



Elissa Hall, EdD, MA

In clinical anatomy education, meaningful learning requires intentional design aligned with competency-based medical education (CBME), ensuring that learners progressively develop and demonstrate relevant knowledge, skills, and professional behaviors. Informed by American Association of Medical Colleges (AAMC) priorities, this interactive session explores how anatomy education can evolve within a technology- and data-enhanced learning ecosystem, with particular attention to the role of artificial intelligence (AI). Using a "now, near, and far" framing, participants will identify immediate strategies to design future-oriented learning experiences.

How Would You Deconstruct It?

Complex patient cases, innovation and re-evaluating procedures for optimizing patient care is often associated with a need for clarity in poorly understood anatomy. This session demonstrates how clinical questions can advance anatomical understanding from revisiting concepts through dissection and imaging.

Speaker 1: **Dr's Nahid Vidal and Yolanda Salinas**
(Treatment of Dermatofibrosarcoma - Advanced Anatomy of the Female Perineum)

Speaker 2: **Dr's Jon Christensen and Punnose Kattil**
(Sub-pectoral nerve block - Advanced anatomy of the Pectoral Fascial Spaces)

Speaker 3: **Dr's Samesh Lachman and Antonio Rivera**
(Neurosurgical access in anterior approach of the spine -
Advanced anatomy of structures in anterior neck)

Speaker 4: **Dr Joe Iwanaga**
(New Anatomical Insights into Nasal Morphologic Changes
Following Le Fort I Osteotomy of the Maxilla

Speaker 5: **Dr's Nirusha Lachman and Chris Miller**
(Cheek rotation flap motion - Facial Retaining Ligaments and Tack Points)

Committee Meeting Descriptions

(Open to all – not restricted to members of the committee)

Career Development Committee Meeting

Friday, June 12th from 12:45 pm – 1:45 pm
Open to All Attendees

"Benefits of Mentor-Mentee Relationships in Career Development"



Ethan L. Snow, PhD, MA

Join the Career Development Committee (CDC) for a dynamic lunch session focused on "Benefits of Mentor-Mentee Relationships in Career Development" where Dr. Ethan Snow will highlight strategies for efficient and impactful mentor-mentee communications. Participants will learn about AACA's Mentor-Mentee Program and will have the opportunity to formally join the program at the event. Near the end of the session, outgoing members of the CDC will be recognized, and session attendees will have the opportunity to nominate new committee members. Nominees will be given a moment to speak about their interests in CDC involvement, and one nominee will be elected by popular vote.

Clinical Anatomical Terminology Committee

Saturday, June 13th from 7:30 am – 8:30 am
Open to All Attendees

The CAT will host a meeting over breakfast on Saturday, June 13th, 2026 from 07:30 – 08:30am. Light breakfast will be provided. The meeting will begin with an introduction to the committee members and the goals and objectives of the CAT committee, and the various subcommittees. Subsequently, there will be a presentation on the activities of the CAT committee, and the subcommittees – Fascia, French TA2, and Pelvic Terminology. Two new members-at-large will be elected. During this breakfast meeting, members will have the opportunity to participate in an interactive panel discussion about current and potential future projects to be conducted by the CAT committee. Interested members should consider attending this interactive meeting and run for election to the CAT committee. It is also an opportunity to submit interest in joining one of the sub-committees. Meeting Overview: Introduction – committee members Overview of goals and objectives brief report from sub-committees - Fascia, French TA2, and Pelvic Terminology Nomination and voting of new members. Interactive Panel Discussion – current and future projects announcement of election of new Members-at-Large

Ad Hoc Diversity, Equity, and Inclusion Committee Meeting

Saturday, June 13th from 11:30 am – 12:45 pm
Open to All Attendees

"Advancing EDI for Oral and Craniofacial Anatomy: Curriculum Diversification and Resource Development"



Dr. Eiman Abdel Meguid, PhD

This talk will highlight the implementation of Equality, Diversity and Inclusion (EDI) in the curriculum and the development of learning resources designed to improve representation in anatomical teaching. It will also explore the importance of diversifying the oral and craniofacial anatomy curriculum, including variations and clinical presentations across different populations to better reflect the diverse patient populations that dental students will serve. The session will share practical strategies for integrating inclusive content into anatomy teaching, and reflect on how curriculum diversification can enhance equity, clinical awareness, and educational outcomes.

Anatomical Services Committee Meeting

Saturday, June 13th from 12:45 pm – 1:45 pm
Open to All Attendees

The Anatomical Services Committee invites you to join our interactive lunch meeting where anatomical services, faculty, staff, and students come together to discuss key issues in the field. Participants will engage in small-group, break out discussions amongst tables of differing topics such as donor shortage, educating potential donors, chemical exposures, and mold outbreaks. In addition, there will be 'choose your own' topic tables available as well, so bring your questions, concerns or topics of interest. All perspectives are welcome and we encourage open dialogue and collaboration! Active AACA members in attendance will also participate in the election of new committee members.

Educational Affairs Committee Meeting

Sunday, June 14th from 7:30 am – 8:30 am
Open to All Attendees

"Integrating Learning Theory into Competency-Based Anatomy Education"



Dr. Mohammed K. Khalil, DVM, M.S.Ed., PhD

Competency-based medical education (CBME) has shifted the focus of undergraduate medical training toward demonstrable performance, longitudinal progression, and clinical entrustment. Within this context, the role of the anatomical sciences has expanded beyond foundational knowledge to include direct contributions to clinical reasoning, procedural skills, and patient safety. While curricular integration and assessment reforms are well established, the theoretical foundations that support effective anatomy education in CBME are less clearly defined. This session examines how behaviorist, cognitivist, and constructivist perspectives can be used to inform the design of anatomy instruction within CBME frameworks. Attention will be given to how these perspectives support skill acquisition, organization of anatomical knowledge, and its application in clinical contexts. The session will also consider how learning theory informs assessment approaches, including structured observation, simulation, and longitudinal evaluation strategies. Examples from anatomy education will be used to illustrate how instructional design and assessment can be aligned with clinical competencies. Implications for curriculum development, faculty roles, and programmatic assessment will be discussed. Participants will leave with a clearer understanding of how learning theory can be applied to strengthen the coherence and clinical relevance of anatomy education in competency-based programs.

Committee Symposium Descriptions

Anatomical Services Committee Symposium
Sunday, June 14th from 10:45 am – 12:15 pm
Open to All Attendees

"The Value and Importance of Cadavers in Educational Bioskills Labs"

An overview of how cadaver-based bioskills labs support hands-on surgical and procedural training, with emphasis on anatomical understanding, technical skill development, and clinical decision-making. Includes considerations for teamwork, professionalism, safety, regulatory compliance, donor programs, and efficient lab design.



Pat Cichlar Alexander, R.N.
Pat Cichlar Alexander, R.N. began her career as a Clinician in Orthopaedic Surgery at Evanston Hospital. She later transitioned into the medical device industry, serving as a Distributor for Smith & Nephew Dyonics, specializing in Arthroscopic equipment and briefly worked with Mitek. Following her move to Chicago, she became the Executive Director of the Orthopaedic Learning Center (OLC), a position she held for 22 years. During her tenure, she played a key role in the development of the newest OLC facility.
Pat is also one of the three co-founders of ABLE, established 16 years ago, and currently serves on it's Board of Directors. In addition to her leadership at ABLE, she has consulted on the development of several other surgical training laboratorie.

Educational Affairs Committee Symposium
Saturday, June 13th from 4:45 pm – 6:15 pm
Open to All Attendees

"Raising a Foster Family: The Next Chapter in the Anatomist and Surgeon Relationship"
The symposium will focus on the evolving relationship between anatomists and surgeons, with particular emphasis on how this collaboration supports the education and preparation of resident physicians. It will highlight the importance of strong clinical anatomy knowledge as a foundation for safe and effective surgical practice, as well as its role in improving clinical decision-making and procedural confidence. In addition, the symposium will also explore how anatomy teaching is integrated into residency training, identify gaps in current educational approaches, and discuss the challenges residents face in applying anatomical knowledge in real clinical settings. Finally, this symposium will present strategies to better align anatomical education with clinical and surgical needs, fostering closer collaboration between basic science educators and practicing surgeons.

continued on next page

Overall, the symposium will emphasize improving resident education to enhance overall surgical competency, and ultimately advance patient outcomes through stronger and more effective partnerships between anatomists and surgeons.



Dr. Roy Phitayakorn, MD, MHPE, MAMSE, FACS

As the Vice Dean for Education, Dr. Roy Phitayakorn is responsible for integrating and managing pre-medical education, undergraduate medical education, graduate medical education, and continuing medical education at the University of Illinois College of Medicine (UI COM). Dr. Phitayakorn completed his residency training in general surgery at Case Western Reserve University in 2009 and an endocrine surgery fellowship at the Massachusetts General Hospital (MGH) in 2011. Dr. Phitayakorn is a Professor of Surgery with a practice in general surgery and endocrine surgery and adjunct faculty within the UI COM Department of Medical Education. He has a master's degree in medical education (MHPE) from UI COM, and his thesis on phone communication practices won the best thesis award in 2005. Dr. Phitayakorn was an external examination consultant for the American Board of Surgery and developed medical education content for the American College of Surgeons. Dr. Phitayakorn is also a faculty member for several national medical education courses and institutions, including the Harvard Macy Institute and the American College of Surgeons (ACS) Surgeons as Educators course. Finally, Dr. Phitayakorn serves as a Commissioner for the Accreditation Council on Colleges of Medicine and assists in accrediting medical schools in the Caribbean. He is also a site reviewer for the AAMC Liaison Committee of Medical Education.

Annual Business Meeting Agenda

Sunday, June 14th, 2026
Rochester, Minnesota

CALL TO ORDER: 12:30 pm
Approval of Minutes of 2025 Annual Business Meeting (ABM) and the 2026 ABM Agenda

1. **President's Report** – Nirusha Lachman – **10 minutes**
   a. 2026 Election Results
   b. 2027 Election – Positions open to the AACA Membership in 2027
      i. Program Secretary
      ii. Special Councilor – Anatomical Services
      iii. Councilor-at-Large (2)
   c. Presidential Committee Appointments
   d. State of the Association
2. **Treasurer's Report** – Kazzara Raeburn – **10 minutes**
3. **Membership Committee Report** – Nirusha Lachman – **5 minutes**
   a. Remembrance of Deceased Members – Mo Khalil – **5 minutes**
4. **Journal Report** from Editor-in-Chief of Clinical Anatomy – R. Shane Tubbs – **5 minutes**
5. **Meeting Organization & Program Planning Committee Report** – Kathleen Bubb – **10 minutes**
   a. Report of 2026 Annual Meeting Committee
   b. Future Meetings:
      i. 2027 AACA Annual Meeting: Texas Tech University Health Sciences Center, Lubbock, TX
      ii. 2028 AACA Annual Meeting: St. George's University, Grenada
6. **Committee Updates & Elections** – **20 minutes**

   <u>Elections & Updates</u>[1]
   a. Bylaws Committee
   b. Nominating Committee
   c. Financial Affairs Committee
   d. Journal Committee
   e. Membership Committee

   <u>Committee Updates</u>
   a. Anatomical Services Committee
   b. Career Development Committee
   c. Clinical Anatomical Terminology Committee
   d. Educational Affairs Committee
7. **Old Business** – **5 minutes**
8. **New Business** – **5 minutes**

ADJOURNMENT: 1:45 pm

[1] The Special Interest Group (SIG) Committees (Brand Promotion and Outreach, Educational Affairs, Career Development, Clinical Anatomical Terminology, and Anatomical Services) will elect members at their committee meetings.

Annual Business Meeting Minutes

Thursday, June 19th, 2025
Bellevue, Washington, USA

CALL TO ORDER: 3:30 PM

1. **Approval of Minutes of 2024 Annual Business Meeting (ABM) and 2025 ABM Agenda**
   a. 2024 Minutes: No corrections – Kazzara Raeburn made a motion to approve, seconded by Joe Iwanaga, all approved
   b. 2025 Agenda: No corrections – Joe Iwanaga made a motion to approve, seconded by Kathleen Bubb, all approved

2. **President's Report** (R. Shane Tubbs) - **3:32 PM**
   a. 2025 Election Results
      i. President Elect – Nirusha Lachman
      ii. Treasurer – Kazzara Raeburn
      iii. Special Councilor, Clinical – Joe Iwanaga
      iv. Councilor-at-Large – Arada Chaiyamoon
      v. Councilor-at-Large – Geoffroy Noel
   b. 2026 Election – Positions open to the AACA Membership in 2026
      i. Association Secretary (1)
      ii. Special Councilor, Allied Health (1)
      iii. Councilor-at-Large (2)
   c. Special Interest Group Committee Updates
      i. Anatomical Services Committee
         (1) Presidential Appointees
            (a) 2023-2026: Matthew McCracken
            (b) 2024-2027: Amberly Reynolds, Chair
            (c) 2025-2028: Evan Goldman
         (2) Members Elected at Annual SIG Meeting of Committee
            (a) 2023-2026: Jessica Immonen
            (b) 2024-2027: Malli Barremkala
            (c) 2025-2028: Ron Wilde
      ii. Brand, Promotion and Outreach Committee
         (1) Presidential Appointees
            (a) 2023-2026: Mathangi Rajaram-Gilkes
            (b) 2024-2027: Deepak Sharma, Chair
            (c) 2025-2028: Adam Lawson
         (2) Members Elected at Annual SIG Meeting of Committee
            (a) 2024-2027: Edgar Meyer

continued on next page

(b) 2024-2027: Uma Pandalai
(c) 2024-2027: Brian MacPherson

iii. Career Development Committee
(1) Presidential Appointees
(a) 2023-2026: Ewarld Marshall
(b) 2024-2027: Santosh Sangari
(c) 2025-2028: Adegbenro Fakoya
(2) Members Elected at Annual SIG Meeting of Committee
(a) 2023-2026: Jolene Harris
(b) 2024-2027: Punnose Kattil
(c) 2025-2028: Ethan Snow, Chair

iv. Clinical Anatomical Terminology Committee
(1) Presidential Appointees
(a) 2023-2026: Peter Ward
(b) 2023-2026: Alan Detton
(c) 2024-2027: Geoffroy Noel
(d) 2024-2027: Sunil Kumar Oza
(e) 2025-2028: Anthony Weinhaus, Chair
(f) 2025-2028: Rekha Kar
(2) Members Elected at Annual SIG Meeting of Committee
(a) 2023-2026: Sarah Tilden
(b) 2023-2026: Chernet Tessema
(c) 2024-2027: Heba Labib
(d) 2024-2027: Martin Lhuaire
(e) 2025-2028: Jaime Hinojosa
(f) 2025-2028: Lauren Bagian

v. Educational Affairs Committee
(1) Presidential Appointees
(a) 2023-2026: Mitesh Dave
(b) 2024-2027: Jennifer Burgoon
(c) 2025-2028: Yolana Salinas-Alvarez, Chair
(2) Members Elected at Annual SIG Meeting of Committee
(a) 2023-2026: Carolyn Meyer
(b) 2024-2027: Padma Gadepally
(c) 2025-2028: Jessica Bergden

vi. Ad Hoc Diversity, Equity, and Inclusion Committee
(1) Edgar R. Meyer, Chair
(2) Sasha Lake
(3) Sarah Greene
(4) Haley Nation
(5) Jonathan Wisco
(6) Adegbenro Fakoya
(7) Abayomi Afolabi
(8) Paul Neumann

continued on next page

(9) Amberly Reynolds
(10) Saskia Richter
(11) Rosie Santos

3. **Treasurer's Report** (Jennifer Walls on behalf of Mathangi Rajaram-Gilkes) - - - **3:36 PM**
   a. Summary of Accounts (all as of April 30, 2025)
   b. Growth Over Time
   c. Status of Accounts: total assets $1,150,388
      i. This will decrease once meeting costs have been paid
      ii. Annual Meetings – Historical review
         (1) Projected loss for the 2025 Annual Conference
      iii. Regional Meetings –
         (1) Generally have small net income but great for networking
      iv. Other Income
         (1) Membership Dues
         (2) Journal Information
   d. Issues That Can Affect Fiscal Stability
      i. Vendors/Sponsorship – Bellevue had 9 vendors
      ii. Location of annual meeting, virtual Council meetings, regional meetings, vendors/sponsorship
   e. Thanks to members of Financial Affairs Committee

4. **Membership Committee Report** (Anthony D'Antoni) - - - - - - - - - - - - - - - - - - - **3:42 PM**
   a. Reviewed Membership Committee
   b. Reviewed membership types
   c. Reviewed membership dues structure
      i. Highlighted success of new institutional membership type

5. **Remembrance of Deceased Members** (Mohammed Khalil) - - - - - - - - - - - - - - **3:46 PM**
   a. Robert A. Chase, MD

6. **State of the Journal** (R. Shane Tubbs) - **3:47 PM**
   a. Reviewed editors and structure
   b. Reviewed trend of article views – continued increase
   c. Reviewed most viewed articles in *Clinical Anatomy* (top 10)
   d. Reviewed country/region of submission
   e. Reviewed county/region of authorship
   f. Reviewed Impact Factor
      i. Anatomy/Morphology category
      ii. Have remained stable at about 2.4 over the past few years
      iii. Reviewed comparison to other journals
      iv. Reviewed articles that contributed to Impact Factor
   g. Reviewed upcoming articles of interest

continued on next page

7. **Meeting Organization & Program Planning Committee Report** (Kathleen Bubb) - - - **3:52 PM**
   a. Report of 2025 Annual Meeting
      i. Continued work on customizing Planstone
      ii. Updated submission guidelines and the post-conference survey
      iii. Developed the conference schedule:
      iv. Abstract review process: Utilized abstract reviewers' ratings to select presentation format and verified IRB when applicable
      v. Continued Trivia night (sponsored by CAT)
      vi. Additions to the program: Preconference educational technology workshops, Fireside Chat, Clinical Anatomy Symposium
      vii. Planning for future meetings
      viii. Full report in conference program/app, see pages 33-35
   b. Reviewed current and past abstract/registration statistics
      (1) 264 registrants currently
      (2) 143 post-able presentations
      (3) 7 non-post-able presentations
   c. Thanks to Special Interest Committee Chairs
   d. Thanks to Meeting Managers
      i. Brian MacPherson (2023-2025), Adam Kolatorowicz (2024-2026), Cara Fisher (2025-2027)
   e. Thanks to Others
      i. Peter Ward – Anatomy Trivia
      ii. Sue Simon – Pre Conference Workshop
      iii. Joe Iwanaga – Symposium Organizer
   f. Thanks to ASG
   g. Future Meetings:
      i. 2026 AACA Annual Meeting, June 12-15, Mayo Clinic, Rochester, MN – Nirusha Lachman & Jonathan Torrens-Burton
      ii. 2027 AACA Annual Meeting, June, Texas Tech University Health Sciences Center, Lubbock, TX – Kerry Gilbert & Keith Bishop
      iii. 2028 AACA Annual Meeting, June, St. George's University, Grenada – Kazzara Raeburn & Marios Loukas
   h. Other Future AACA Annual Meetings
      i. If interested in hosting a conference (Regional or National) – please email ASG
   i. Post-Conference Survey
      i. Please complete to help us improve future meetings

8. **Committee Updates and Voting** - **4:00 PM**
   a. Bylaws Committee
      i. Presidential Appointees
         (1) 2025-2028: Cara Fisher
         (2) 2025-2028: Adam Kolatorowicz, Chair
         (3) 2025-2028: Gurvinder Kaur
      ii. Members Elected at Annual Business Meeting

continued on next page

(1) 2025-2028: Peter Ward
(2) 2025-2028: Vacant

b. Nominating Committee
   i. Presidential Appointees
      (1) 2025-2028: Keishiro Kikuchi, Chair
      (2) 2025-2028: Hee-Jin Kim
   ii. Members Elected at Annual Business Meeting
      (1) 2025-2028: Samir Anadkat
      (2) 2025-2028: Vacant
      (3) 2025-2028: Vacant
c. Financial Affairs Committee
   i. Presidential Appointees
      (1) 2023-2026: Jennifer Brueckner-Collins
      (2) 2023-2026: Nitsa Topale
   ii. Members Elected at Annual Business Meeting
      (1) 2025-2028: Vacant
      (2) 2025-2028: Vacant
d. Journal Committee
   i. Presidential Appointees
      (1) 2023-2026: Mohammed Khalil
   ii. Other Members
e. Membership Committee
   i. Presidential Appointees
      (1) 2023-2026: Mi-Sun Hur
      (2) 2025-2028: Avelin Malyango
   ii. Members Elected at Annual Business Meeting
      (1) 2025-2028: Morgan Forston
      (2) 2025-2028: Juan Antonio Rivera Perez

9. **Old Business** - - -

2025 – 2026
AACA Council Members

Officers

President – Nirusha Lachman, PhD

Secretary – Mohammed K. Khalil, DVM, MSEd, PhD

Treasurer – Kazzara Raeburn, MD

Past President – Shane Tubbs, PhD, MS, PA-C

Program Secretary – Kathleen Bubb, MD

Councilors

Yoko Tabira, PT, PhD

Guenevere Rae, MS, PhD

Joe Iwanaga DDS, PhD

David Ezra, PhD

Ameed Raoof, MD, PhD

Mahindra Kumar Anand, MS, PhD

Marios Loukas, MD, PhD

Arada Chaiyamoon PhD

Alan Detton, PhD

Geoffroy Noel, PhD

Clinical Anatomy

The Official Journal of the American Association of Clinical Anatomists and the British Association of Clinical Anatomists

Editor-in-Chief:

R. Shane Tubbs, Tulane University, New Orleans, LA, USA

AACA Senior Editor

Robert J. Spinner, Mayo Clinic, Rochester, Minnesota, USA

AACA Co-Editors

Kathleen Bubb, Weill-Cornell Medicine, New York, New York, USA
Anthony V. D'Antoni, Rowan-Virtua School of Osteopathic Medicine, Stratford, NJ, USA
Joe Iwanaga, Tulane University, New Orleans, Louisiana, USA
Mohammad Khalil, University of South Carolina, Greenville, SC, USA
Marios Loukas, St. George's University, Grenada
Susan Standring, King's College, London, UK
Yoko Tabira, Kurume University, Kurume, Japan
Jariya Welbat, Khon Kaen University, Khon Kaen, Thailand

BACA Editor

Philip Adds, St. George's University, London, UK

Assistant BACA Editor

Jenny Clancy, University of Glasgow, Glasgow, UK

Founding Editors

Ralph Ger and R. J. Scothorne

Editorial Board Members:

Marwan F. Abu-Hijleh, Qatar University, Doha, Qatar
Mahindra Kumar Anand, Rama Medical College & Research Centre, Rama City, Pilkhuwa, Hapur, India
Robert H. Anderson, Newcastle University, Newcastle upon Tyne, UK
Miguel Angel Reina, CEU San Pablo University Faculty of Medicine, Madrid, Spain
Nihal Apaydin, Ankara University, Ankara, Turkey
Ronald L.A.W. Bleys, University Medical Center Utrecht, Utrecht, The Netherlands
Jingxing Dai, Southern Medical University, Guangzhou, China
Peter Dangerfield, Liverpool University, Liverpool, UK
Raffaele De Caro, University of Padua, Padova, Italy
Fabrice Duparc, University of Rouen-Normandy, Rouen, France
David Ezra, Academic College of Tel Aviv-Jaffa, Jaffa, Israel
Georgi P. Georgiev, University Hospital Queen Giovanna-ISUL, Medical University of Sofia, Sofia, Bulgaria
Duncan Lee Hamilton, James Cook University Hospital, Middlesbrough UK; Friarage Hospital, Northallerton, UK; University of Sunderland School of Medicine, Sunderland, UK

continued on next page

Mi-Sun Hur, Daegu Catholic University School of Medicine, Daegu, Republic of Korea
Soichiro Ibaragi, Okayama University, Okayama, Japan
Ikuo Kageyama, The Nippon Dental University, Niigata, Japan
Hee-Jin Kim, Yonsei University College of Dentistry, Seoul, Republic of Korea
Norio Kitagawa, Institute of Science Tokyo, Tokyo, Japan
Nirusha Lachman, Mayo Clinic, Rochester, MN, USA
Joanna Matthan, Newcastle University Medicine Malaysia, Iskandar Puteri, Malaysia
Garrett Moore, University of Colorado, Anschutz Medical Campus, Aurora, CO, USA
Shumpei Mori, University of California Los Angeles, Los Angeles, California, USA
Alan Moulton, Kings Mill Hospital, Nottingham, UK
Richard Newell, Cardiff University, Cardiff, UK
Roelof-Jan Oostra, Amsterdam UMC Location University of Amsterdam, Amsterdam, The Netherlands
Jun Ouyang, Southern Medical University, Guangzhou, China
Anjulata Rai, New Delhi, India
Domenico Ribatti, Università degli Studi di Bari, Bari, Italy
José Ramón Sañudo, Universidad Complutense Madrid, Madrid, Spain
Thomas Shiozawa-Bayer, Eberhard Karls Universität Tübingen, Tübingen, Germany
Hong-Jin Sui, Dalian Medical University, Dalian, China
Justin T. Tretter, Cleveland Clinic Children's and The Heart, Vascular, and Thoracic Institute, Cleveland Clinic, Cleveland, OH, USA
Jerzy Walocha, Jagiellonian University Medical College Cracow, Kraków, Poland
Zeng Tao Wang, Shandong University, Shandong, China
Koichi Watanabe, Kurume University, Kurume, Japan
Peter L.T. Willian, Keele University, Staffordshire, UK
Adam Wilson, Rush University, Chicago, Illinois, USA
Du Xinru, Beijing, China
Shengbo Yang, Zunyi Medical University, Zunyi, China
Matthew J. Zdilla, West Virginia University, Morgantown, WV, USA

Managing Editor

Isaiah Tubbs, Tulane University, New Orleans, LA, USA
Email: me.clinanatomy@gmail.com

Production Editor:

Reeni Sunder
Email: sreeni@wiley.com

Committee Reports

Anatomical Services Committee

Ad hoc Diversity, Equity, and Inclusion Committee

Career Development Committee

Clinical Anatomical Terminology Committee

Educational Affairs Committee

Journal Committee

Listserv Admin Report

Membership Committee

Meeting and Oversight Program Planning Committee

Nominating Committee

Bylaws Committee

Anatomical Services Committee Report

The Anatomical Services Committee (ASC) promotes the activities of members who administer institutional willed body donor programs; sit on state anatomical boards and committees; and/or prepare and/or utilize cadaveric materials for education and research

ASC functions to serve the AACA membership by developing symposia, special sessions, courses, and guidance documents while promoting technical and academic aspects of human anatomical tissue use in healthcare, university education, and research. In addition, the group advocates for the informed, ethical, and safe operation of body donation programs to support the human anatomical tissue requests of students, faculty, staff, and researchers who contribute to the advancement of medicine through education and research. Information about the ASC, including position statements, best practices, contact information, and links, can be accessed from the Association website: http://clinical-anatomy.org/Committees

During 2025-2026, the ASC worked to identify key issues relevant to the operation of body donation programs, including current practices, compliance, preparations, ethics, public relations; all of which inform the creation of guidance documents, contribute to discussions with membership and at the annual meeting while informing future directions and needs for the ASC. The committee continues to create resources on anatomical donors, education with donors, tissue preservation and key topics to soon be accessed through the AACA website. Current documents include “Literature on the impacts of Body Donation,” “Key points for Anatomical Service for a Willed Body Program and Cadaver Lab,” and “Best Practices for Donation Programs.”

Presidential Appointees (Two Year Term as of 2025):

2023-2026: Matthew McCracken, mmccracken006@gmail.com

2024-2027: Amberly Reynolds, Rocky Vista University, areynolds@rvu.edu, Chair

2025-2027: Evan Goldman, Penn State College of Medicine, egoldman1@pennstatehealth.psu.edu

Elected Members-at-Large (Three Year Term):

2023-2026: Jessica Immonen, University of Nevada-Las Vegas, jessica.immonen@unlv.edu

2024-2027: Malli Barremkala, OUWB School of Medicine, barremkala@oakland.edu

2025-2028: Vacant

Ex Officio: Guenevere Rae, Tulane University School of Medicine, ASC Special Councilor, grae@tulane.edu

continued on next page

Ad Hoc Diversity, Equity, and Inclusion Committee (DEIComm) Report

Members:
Edgar R. Meyer (Chair)
Yomi Afolabi
Fakoya Adegbenro
Sarah Green
Sasha Lake
Haley L. Nation
Paul Neumann
Kelsey Picha
Amberly Reynolds
Saskia Richter
Rosaysela Santos

***Note:** Members whose names are no longer present in the above list had to step down from service on the committee due to institutional obligations or due to retirement.

Mission:

Created in 2020, the Ad-Hoc Diversity, Equity, and Inclusion Committee (DEIComm), committee is charged by the AACA with promoting and fostering a culture that values diversity, equity, and inclusion in clinical anatomy. The charges of this ad hoc committee are as follows:

1. Surveying and evaluating AACA membership, statements, and activities on issues affecting diversity, equity, and inclusion in the clinical anatomy profession and
2. Identifying gaps and making recommendations to:
    a. Raise awareness and provide education on the importance of diversity and inclusion in the profession.
    b. Promote outreach and mentorship.
    c. Identify resources for training.
    d. Support a forum for discussion on diversity and inclusion.

Summary of Past and Ongoing DEIComm Activities

The committee met monthly to discuss the needs of the membership, proposed budgets, awards, and future projects. A meeting was held on the first Thursday of each month in fall semester, and for this spring semester, the committee has been meeting on a varying date and time conducive with the majority of the membership's schedules. The following bullet points outline the tasks accomplished during and/or after these meetings up until the current timepoint:

- The committee planned, scheduled, and delivered the AACA DEIC CART webinar titled "The Anatomy of Access: Making Anatomy Courses and Learning Environments Accessible for Students with Accommodated Characteristics" on Wednesday, April 29, 2026, at noon Eastern Daylight Time. This CART webinar featured panelists who discussed their perspectives as learning accommodations administrators or as anatomy educators and/or anatomy learners requiring accommodations regarding mobility, neurodivergence, Deaf or hard of hearing, and/or blindness or visual impairment needs.
- The committee sought AACA Council approval for a special guest speaker who will be presenting during the AACA DEIC meeting at the 2026 AACA Annual Meeting, and the presentation topic and speaker have been scheduled: "Advancing EDI for Oral and Craniofacial Anatomy: Curriculum Diversification and Resource Development" by Dr. Eiman Abdel Meguid, Ph.D. This talk will highlight the implementation of Equality, Diversity and Inclusion (EDI) in the curriculum and the development of learning resources designed to improve representation in anatomical teaching. It will also explore the importance of diversifying the oral and craniofacial anatomy curriculum, including variations and clinical presentations across different populations to better reflect the diverse patient populations that dental students will serve. The session will share practical strategies for integrating inclusive content into anatomy teaching, and reflect on how curriculum diversification can enhance equity, clinical awareness, and educational outcomes.
- The committee has created a running draft of questions for a membership survey for ascertaining the demographic data of the AACA membership base. Such data will allow for comparing metrics with other anatomical professional societies, and it will provide membership with an overview of the landscape of the changing membership demographics through the years. A final draft of the survey questions will be submitted to Council for review.
- The committee has also discussed opportunities for curating databases or archives for storing DEI resources that can be used by AACA members who wish to integrate DEI content into their courses and curricula.

continued on next page

Future DEIComm Activities

The committee aims to complete the following tasks prior to or during the 2026 AACA Annual Meeting:

- Facilitate the DEIC meeting special guest speaker's presentation at the 2026 Annual Meeting.
- The committee aims to have completed the draft of the membership survey items.

The committee aims to complete the following tasks in the future beyond the 2026 AACA Annual Meeting:

- Submit a membership survey draft to the AACA Council for approval.
- Initiate and/or improve relations with other national and international professional societies.
- Create a repertoire of DEI resources for membership access.

Career Development Committee Report

Ethan Snow (Chair), Jolene Harris, Punnose Kattil, Santosh Sangari, Adegbenro Fakoya, Ewarld Marshall

"The **Career Development Committee (CDC)** is committed to supporting the professional growth of clinical anatomists at all academic ranks. The Committee fosters the development of quality anatomical research and scholarly educational endeavors" (Article VIII, Section 9, Subsection B).

In their commitment to fostering a sustained culture of mentorship within the AACA, the CDC maintains a longitudinal Mentor-Mentee Program aimed at providing ongoing mentorship and professional development for its members. At this year's annual meeting, the CDC will host a dynamic lunch session focused on "Benefits of Mentor-Mentee Relationships in Career Development" which intends to communicate a strategic framework for improving existing and new mentor-mentee relationships throughout the coming year. Emphases on regular and long-term mentorship will serve to underscore the importance of professional networking, encourage AACA membership retention, and excite members for next year's CDC symposium planned to feature strategies for early-career clinical anatomy research productivity and career growth.

In their efforts to promote high quality anatomical research and educational scholarship, the CDC facilitates judging of student poster presentations and platform presentations at the AACA annual meeting and conveys the prestigious Sandy C. Marks Jr. and Ralph Ger awards. To improve judging efficacy, the CDC has decided to conduct an initial round of judging for student poster presentations this year by evaluating the digital posters and audio presentations before the conference. The CDC anticipates this action will allow more time for the CDC and volunteer judges to engage in quality interaction with student presenters. This decision also provides opportunity for AACA members who are unable to attend the AACA annual conference to serve as a judge, provide meaningful feedback to student presenters, and contribute to the success of the AACA annual conference.

If you or someone you know is interested in joining the CDC, please talk with one of the existing committee members and attend the CDC Lunch Meeting on **Friday, June 12th from 12:45 pm – 1:45 pm** where nomination and election of a new committee member will occur. Nominees will be given a moment to speak about their interests in CDC involvement, and one nominee will be elected by popular vote.

CDC Members:

Presidential Appointees (Two Year Term as of 2025)

2023-2026: Ewarld Marshall

2024-2027: Santosh Sangari

2025-2028: Adegbenro Fakoya

Members Elected at Annual SIG Meeting of Committee (Three Year Term)

2023-2026: Jolene Harris

2024-2027: Punnose Kattil

2025-2028: Ethan Snow, Chair

Clinical Anatomical Terminology Committee Report

The *Clinical Anatomical Terminology* (*CAT*) *Committee* of the AACA studies the usage of anatomical terminology in biomedical sciences and in clinical practice. It strives to disseminate its findings through free web-based resources (i.e. web-based browser TA2Viewer (ta2viewer.openanatomy.org; Halle, Kikinis & Neumann, 2024, Clin. Anat. 37:640-648) and through publications in the journal of the AACA, *Clinical Anatomy*.

The CAT Committee hosts a breakfast or lunch meeting at the annual AACA meeting, and a Symposium in alternate years. At the 2026 meeting at the Mayo Clinic, the CAT committee will host a breakfast meeting. During which, activities of the committee will be presented and two new members-at-large will be elected. In addition, there will be an interactive Panel Discussion of potential future activities of the CAT committee.

At the 2025 meeting, the CAT committee hosted a symposium focused on the topic of Fascia (structural, functional, and clinical aspects), with three guest speakers: Drs. Carla Stecco (Italy), Rebecca Pratt (USA) and Martin Lhuaire (France).

The CAT committee also forms subcommittees to work on the various projects.

continued on next page

The **Fascia subcommittee** (chaired by A. Detton) was founded in 2023 to attempt to find a consensus definition and classification of fasciae because there is a wide chasm between the narrow definition in *Terminologia Anatomica* (TA, FCAT, 1998) and the broader definition proposed by some members of the Fascia Research Society (e.g., Stecco and Schleip, 2016; Adstrum et al., 2017). The first project of the subcommittee was a Qualtrics survey to assess perceptions from anatomists to the current definitions of fascia and opinions on which structures are included in the set of fasciae in the TA. The results of the initial sample (members of the subcommittee) were presented at the 2024 AACA meeting in New York City. The results of preliminary surveys of AACA and FRS (Fascia Research Society) members were be presented at the 2025 meetings of the AACA and FRS. The subcommittee is currently seeking input from a gradually expanded community – other anatomists (e.g., BACA) and then other scientists and clinicians interested in fascia.

With the goal of finding a position that could lead to a consensus definition of fascia among anatomists, other biomedical scientists, and health practitioners with an interest in fascia, the Fascia Subcommittee, as a collaboration and authored by Paul Neumann, published in Clinical Anatomy a manuscript entitled "Fascia, eh. What is it? What is it good for?".

With the goal of investigating the nature of anatomical structures, listed mainly in TA2 , that bear the noun aponeurosis to determine whether specific aponeuroses are broad tendons or fasciae, the Fascia Subcommittee has been working to generate a manuscript, as a collaboration and authoring by Heba Labib.

The committee is greatly interested in hosting a Clinical Anatomy Round Table (CART) session on the topic of "Clinical aspects of Fascia".

A **French TA2 subcommittee** (chaired by G. Noel) was formed in 2023 to produce a translation of the second edition of *Terminologia Anatomia* (TA2; FIPAT.library.dal.ca/TA2) as a resource for the francophone medical education programs in North America and the Caribbean, and other interested individuals and organizations. The subcommittee includes members from Canada (including émigrés from France, Switzerland, Belgium, Algeria and Morocco), U.S.A, Haiti, Mauritania, and France. The goal is to present the completed translation for adoption by the AACA at its annual meeting. The plan for the French translation includes open access publication on the AACA website and incorporation into TA2viewer.

The **Pelvic Terminology subcommitte**e (chaired by S. Tilden) is charged with reviewing the nomenclature recommendations of the Society of Gynecological Surgeons Pelvic Anatomy Group, which were published in a series of three papers (2018; 2019; 2021). The goal is to publish a report of the subcommittee's review in *Clinical Anatomy*.

Councilor, ex officio:
2025-2027: Joe Iwanaga: iwanagajoeca@gmail.com

Presidential Appointees
2023-2026: Peter Ward (pward@osteo.wvsom.edu); **Secretary**
2023-2026: Alan J. Detton (adetton@hs.uci.edu)
2024-2027: Geoffroy Noel (gnoel@health.ucsd.edu)
2024-2027: Carlos Suarez-Quian (suarezc@georgetown.edu)

Members-at-Large
2023-2026: Sarah Tilden (tildensa@msu.edu); **Deputy secretary**
2023-2026: Chernet Tessema (chernet.tessema@med.und.edu)
2024-2027: Heba Labib (hlabib@wmcarey.edu)

Newly elected: (3yr terms)
2025-2028: Jaime Hinojosa (jaime.h.hinojosa@gmail.com)
2025-2028: Lauren Bagian (lauren.bagian@georgetown.edu)
2025-2027: Martin Lhuaire (martin.lhuaire@u-paris.fr)(replacement for AJW as presidential appointment)

Newly appointed
2025-2027: Anthony Weinhaus (weinh001@umn.edu); **Chair**
2025-2028: Rekha Kar (karr@uthscsa.edu)

Fascia Subcommittee
A. Detton, chair
External members:
Derek Harmon (Derek.Harmon@osumc.edu)
George Prada (gxp073@shsu.edu)

French TA2 Subcommittee
G. Noel, chair
External members:
Mina Zeroual (McGill University)
Melanie Houle (U. Ottawa)

Pelvic Terminology Subcommittee
Sarah Tilden, chair
External member:
Katherine Brakora (kbrakora@tamu.edu)

There are 4 outgoing members.
Two new members will be appointed by the President.
Two new members will be elected by the CAT membership at the annual meeting.

continued on next page

Educational Affairs Committee Report

The Educational Affairs Committee (EAC) promotes the teaching of Clinical Anatomy, tracks national and international curricular trends and changes, and develops educational initiatives that will benefit the Association's members, health care professionals, the education community, and the public.

The Committee disseminates data and recommendations on best practices across all aspects of anatomical education as they relate to clinical practice. The Committee also plans and implements the Educational Affairs Symposium when scheduled by the Meeting Oversight and Program Planning Committee.

The Committee consists of six (6) members. The President-Elect appoints one (1) member during the second year of their term, and the President appoints one (1) member during the first year of their term, each serving a two-year term. One (1) additional member is nominated and elected by the Active Members in attendance at the annual open meeting and serves a three-year term.

Monthly EAC meetings, discussions continued to focus on several key themes relevant to contemporary anatomy education, building upon prior initiatives and expanding the committee's educational mission.

During the 2025–2026 cycle, a central objective of the committee was to further establish the EAC as a professional platform for clinical anatomists with a strong interest in education and training in anatomy education research. The committee aimed to support members in developing educational knowledge, practical teaching skills, and competencies in educational research, including the ability to design, evaluate, and critically appraise anatomy education studies, to enhance the training of learners across the health professions. Committee discussions emphasized that effective anatomy education extends beyond content expertise and should be grounded in foundational educational theories, evidence-based educational approaches, and sound instructional and didactic strategies. Particular emphasis was placed on strengthening members' understanding of educational research principles, including study design, assessment methods, and interpretation of educational outcomes, as well as on aligning instructional methods, assessment practices, and feedback strategies with clearly defined learning objectives.

In addition, the committee recognized that learner anatomy preparation and educational needs vary substantially depending on training level and professional context. As a result, the EAC emphasized the importance of adapting instructional strategies and curricular approaches to meet the specific needs of different learner groups, including undergraduate, graduate, and postgraduate trainees. This learner-centered perspective, supported by strong educational and educational research foundations, continues to guide the committee's educational initiatives, programming, and faculty development efforts.

1) **EAC Symposium: "Raising a Foster Family: The Next Chapter in the Anatomist and Surgeon Relationship"**
   Dr. Roy Phitayakorn, MD MHPE MAMSE FACS. Scheduled for Saturday, June 13 (4:45 pm – 6:15 pm). The symposium will explore collaboration between clinical anatomists and surgeons to strengthen anatomy education in residency, enhance surgical decision-making and competency, and ultimately improve patient outcomes.
2) **EAC Breakfast meeting: "Integrating Learning Theory into Competency-Based Anatomy Education"**
   Dr. Mohammed K. Khalil, DVM, M.S.Ed., Ph.D. Scheduled for Sunday, June 14 (7:30 am – 8:30 am). This session will explore how learning theory informs competency-based anatomy education, using interactive discussion to highlight instructional and assessment strategies that support clinical skills and reasoning. This session will also include the selection of a new committee member and recognition of outgoing member.

Educational Affairs Committee Members:

Presidential Appointees (Two Year Term as of 2025)

- 2023-2026: Mitesh Dave
- 2024-2027: Jennifer Burgoon
- 2025-2027: Yolanda Salinas-Alvarez, Chair

Members Elected at Annual SIG Meeting of Committee (Three Year Term)

- 2023-2026: Carolyn Meyer
- 2024-2027: Padma Gadepally
- 2025-2028: Jessica Bergden

Journal Committee Report

Committee Members: Marios Loukas, Anthony D'Antoni, Tom Gest, Avriel Licciardi (Wiley editor), Phil Adds (ex officio; Editor BACA), Shane Tubbs (Editor-in-Chief), and Kazzara Raeburn (Presidential Appointee).

The Journal has continued to thrive this year with high quality submissions on clinical anatomy from around the world. Published articles in the Journal continue to have large numbers of downloads and citations. Our impact factor and placement among similar journals are the highest in their history. Please consider submitting your best work to the Journal and continue to follow us online, or on your mobile device with the *Clinical Anatomy* app for Android or iPhone users.

continued on next page

Listserv Admin Report

AACA's Education Issues Listserv was moved from the mail server at Einstein to being hosted on Google Groups in February of 2016. There are currently 1,091 subscribers to AACA's Listserv. From May 2, 2025 to April 27, 2026 there were 9 subjects posted. To the right of this report is a table of those posts that received the most responses.

AACA Education List

Total Subscribers (as of 4/27/26) = 1,091

June 2025 – April 2026 Monthly Email Activity

June '25 = 7

July '25 = 0

August '25 = 1

September '25 = 1

October '25 = 2

November '25 = 0

December '25 = 1

January '26 = 0

February '26 = 1

March '26 = 0

April '26 = 2

Total Emails = 15

Membership Committee Report

The Membership Committee is pleased to report that 167 new members have joined the AACA from May 2, 2025 – April 27, 2026. This includes 90 Associate Members and 77 Regular Members. The total number of active members in the AACA is 723.

From 2025–2026, the AACA Membership Committee remained actively engaged in supporting the organization's membership process. The committee's primary responsibilities include reviewing and approving new membership applications to ensure timely onboarding of prospective members and continued growth of the association. In addition, the committee collaborated on the review and refinement of the membership application process and website materials, with the goal of improving clarity, accessibility, and user experience for current and prospective members. These ongoing efforts aim to support member engagement and enhance the overall efficiency of membership operations within the organization.

Looking ahead, the committee identified several key priorities to further strengthen recruitment, engagement, and member visibility within the AACA. Areas of continued development include strategies to attract additional residents and clinicians through targeted outreach to residency programs and clinical faculty, expansion of member engagement opportunities such as CART sessions, virtual networking, and professional development activities, and increased promotion of member achievements, grants, awards, and collaborative opportunities beyond the annual conference. The committee also discussed enhancing the organization's social media presence through member spotlights and regular communications, as well as improving the consistency and organization of membership categories and database records. Additionally, the committee proposes that members submit professional photos and brief biographies to support outreach, member spotlights, and community-building initiatives within the organization.

2025-2026 Membership Committee Members:

Nirusha Lachman (lachman.nirusha@mayo.edu)

Mi-Sun Hur (mshur10@gmail.com)

Morgan Forston (forston.morgan@mayo.edu)

Antonio Rivera-Perez (riveraperez.juanantonio@mayo.edu)

New AACA Members:

ASSOCIATE

Gabriella Torres Irizarry
Jessica Paola Loaiza Giraldo
Doulton Chinen
Mark Labib
Fares Abdallah
Tianna Helgeson
Sarah Rubinstein
William Brausch
Caden Johnson
Sarah Knutson
Brett Norris
Nora Smestad
Gregory Schwing
Vivin Chrysostor Albert Santhappa
Cade Kartchner
William Gardner
Melissa Nelson
Lorena Paz Barrientos
Cerna
Grzegorz Fibiger
Hyunji Ji
Donghui Tai
Madeline Bogard
Hunter Grimes
Shweta Koul
Jacob Aspaas
Akshita Mehta
Michelle Wang
Iman Vatanpoor
Brian Rushforth
Madison Cowdrey
Mary Kyle Jones

continued on next page

Caleb Thomas
Natcha Chaiburanont
Katherine Avila
Lauren Fell
Ji-Young Son
Maya Jarolem
Ameer Zurob
Jennifer Weil
Emma Dougherty
Jakub Batko
Nicole Derosia
Carson Black
Sera Guevara
Funiba Ngwa
Sorasit Karapanon
Andrew Peace
Keira Prince
Taylor Bradley
Kayla Crawford
Revin Jose Kingsly Jose
Thornton Mardis
Jenny Perez Bruno
Mika Matteo
Kamil Mozdzen
Hope Bae
Eric Becker
Evan McMahan
William Sexton
Evan Feeldy
Ignacy Jastrzebski
Kim Su-Jeong
Allison Anderson
Daniella Ghafari
Trey Heiderscheidt
Maxwell Rost
Wenwen Guo
Arnaud Lucas Menard
Caylee Weber
Jessica Hensley
Peter Chmiel
Kaitlyn Turner
Seth Nance
Honora Armfield
Travis Bentley
Hannah Stadler
Srosha Khanijou
Olivia Hartz
Willson Durbin
Manuel De Jesus Uribe Miranda
Eric Jin
Pichapa Lipisuwanchote
Katie Hawthorne
McKenzie Boyd
Rachaphol Suriha
Rebecca Brewer
Kaitlin Savage
Kyle Bergfalk

REGULAR
David Moyer
Sarah Stevens
Ashima Nag
Juan Jose Valenzuela Fuenzalida
Maresa Mc Dowell
Hetal Rathod
Ashleigh Skaalen
Nasnass Nassir
Martin Javier Mazzoglio y Nabar
Tracy Cassagnol
Abraham Hernandez
Elizabeth Whitney
Kathleen Galloway
Melinda Johnson
Ahmedou Moulaye Idriss
Derek Talbot
Eduardo Rosa-Molinar
Kathryn Jespersen
Ye Liu
Helen Ryals
Fengyu Song
Geoffery Fernquist
Eryn Milian
Hana Abualadas
Samantha Solecki
Bobbi Morgan
Kristen Platt
Jeffrey Wilder
Oheneba Boadum
Kumar Satish Ravi
Derek Harmon
Jonathan Torrens-Burton
Amanda Cobb
Caitlin Sachsenmeier
Joanna Appel
Abduraheem Farah
Helen Kaiser
Kristina Zarenko
Adam Lawson
Dino Soriano
Atasi Chatterjee
Duncan Kirby
Brett Beuning
Brittney Tatchell
Nadeira Mumin
Nicole Griffin
Hisashi Nakamura
Austin Alexander
Madison Brown
Jasmyn Lopez
Lynne Hughes
Ayse Gamze Ozcan
Julianna Santos
Tiffany Barrett
Nathan Short
Katherine Brakora
Kelly Jennings
Amanda Collins
Ahmed Khamas
Mehri Fayazi
Niazur Rahman
Wilson Veras
Christina Drakos
Lori McGrew
Rebecca Scopa-Kelso
Alison McKenzie
James Demetrious
Mario Loomis
Jamie Wikenheiser
Schuyler Connell
Kimberly Steffen
Edgar Meyer
Shayla Yoachim
Li'Anna Drossos
Ashley Hibbitts
Thomas Nathaniel
David Pettigrew

Meeting Organization & Program Planning (MOPP) Committee Annual Report

Kathleen Bubb, MD, MSc
Program Secretary and MOPP Chair, AACA

This report reflects the work of the MOPP Committee during the 2025-2026 academic year and the planning of the upcoming 2026 Annual Meeting of the American Association of clinical Anatomists, hosted at Mayo Clinic. Planning for this year's meeting began immediately after the close of the Seattle meeting and has been guided by member feedback, changes in anatomy and medical education, and ongoing discussions about the role of clinical anatomy in healthcare and training.

This year's meeting has been intentionally designed around several core priorities: applied clinical anatomy, innovation in education, experiential learning, accessibility, and professional connection. Across the program, we have sought to highlight anatomy as something actively used in patient care, procedural decision-making, imaging, and education.

Members:

Special Interest Committee Chairs		**Executive Committee**
Amberly Reynolds, Anatomical Services Committee (**ASC**)		Nirusha Lachman, President
Ethan Snow, Career Development Committee (**CDC**)		R. Shane Tubbs, Past President
Anthony Weinhause, Clinical Anatomical Terminology Committee (**CAT**)		Mohammed Khalil, Association Secretary
Yolanda Salinas-Alvarez - Educational Affairs Committee (**EAC**)		Kazzara Raeburn, Treasurer

continued on next page

Meeting Managers		Local Hosts
Abayomi G Afolabi **(2026-2028)**		Nirusha Lachman & Jonathan Torrens-Burton (2026)
Cara Fisher **(2025-2027)**		Kerry Gilbert & Keith Bishop (2027)
Adam Kolatorowicz **(2024-2026)**		Kazzara Raeburn & Marios Loukas (2028)

ASG Representatives		Non-Voting Members
Caitlin Hyatt, Executive Director		Edgar Meyer, Diversity, Equity, and Inclusion (Special Interest) Committee (DEIC)
Megan Latulippe, Program Coordinator		Sue Simon, Education Technology Workshop Coordinator
Rhonda Freeman, Meeting Specialist		

Acknowledgements & Planning Process

The MOPP Committee has met monthly throughout the year and has worked collaboratively to shape a meeting that balances scientific rigor with inclusivity, creativity, and community.

I am deeply grateful to our phenomenal Meeting Managers, Adam Kolatorowicz, Cara Fisher, and Abayomi Afolabi, whose organization, fairness, and steady leadership have been essential throughout the abstract review and planning process. I also extend sincere thanks to Caitlin Hyatt, Megan Latulippe, and Rhonda Freeman at ASG for their outstanding operational support and partnership behind the scenes.

Special recognition must be given to our local hosts, Drs. Nirusha Lachman and Jonathan Torrens-Burton, whose vision, generosity, and leadership have helped shape many of the meeting's most distinctive features. Beyond serving as exceptional hosts, they have been instrumental in developing and supporting several major initiatives, including the expansion of the Fireside Chat concept and the creation and sponsorship of the inaugural **Oliver H. Beahrs Clinical Anatomy Masterclass Series**. Their efforts have helped create a meeting environment that is both academically outstanding and deeply welcoming.

I would also like to thank our standing committee chairs, workshop coordinators, presenters, exhibitors, and volunteers whose contributions continue to strengthen every aspect of this year's meeting.

Meeting Statistics & Scholarly Engagement

The 2026 meeting continues to demonstrate strong member engagement and scholarly participation across multiple presentation formats. Continued growth in poster presentations, workshops, and TechFair participation reflects increasing interest in educational innovation, translational anatomy, and technology-enhanced learning within the AACA community.

The meeting program includes:

- Platform presentations
- Student scientific sessions
- Poster presentations
- TechFair demonstrations
- Interactive workshops
- Clinical masterclasses
- Educational technology programming

Student-centered programming remains an important priority, with presentations scheduled early in the meeting to maximize visibility, participation, and mentorship opportunities.

Meeting Statistics	2026 Rochester	2025 Seattle	2024 New York	2023 Orlando	2022 Fort Worth	2021 Virtual	2020 Virtual	2019 Tulsa	2018 Atlanta
Initial Abstract Submission	126	126	132	96	97	78	141	97	147
Late-Breaking Submission	25	30	27	35	15	18	15	11	15
Returned for Format	57	21	7	1	32	0	15	16	13
Total Rejections	2	2	0	6	7	9	6	3	2
Registrants*	247	166	130	289	282	338	437	290	350
Platform Presentations	20	15	16	16	17	12	27	20	24
Tech Fair Presentations	7	6	8	5	7	0**	0**	0**	7
Publishable/ Postable	144	143	124	58	65	51	104	63	98
Non-Publishable/ Non-Postable	1	7	10	45	5	17	19	11	29

**Registration for the 2026 AACA Annual Meeting is ongoing, and these numbers will be finalized post-conference.*
*** No Tech Fairs were held from 2019–2021 due to low submissions and virtual format limitations, which did not support the hands-on nature of the event.*

continued on next page

Initiatives and Program Innovation

Oliver H. Beahrs Clinical Anatomy Masterclass Series

One of the most significant additions to this year's meeting is the inaugural **Oliver H. Beahrs Clinical Anatomy Masterclass Series**, developed in collaboration with Mayo Clinic physicians and surgeons. These sessions are designed to demonstrate how anatomical knowledge directly informs surgical planning, procedural innovation, imaging interpretation, and patient-centered care across multiple specialties including orthopedic surgery, interventional radiology, gynecologic surgery, neurosurgery, plastic surgery, and sports medicine. The series reflects a broader strategic goal of positioning clinical anatomy not only as foundational knowledge, but also as an active driver of clinical problem-solving and innovation. The Department of Clinical Anatomy will also host open-house visits, giving members an opportunity to see firsthand how anatomy supports clinical practice, procedural education, and patient-centered care at Mayo Clinic.

Fireside Chat: Experiential Learning, Innovation and AI

This year's reimagined Fireside Chat brings together leaders in immersive learning, artificial intelligence, healthcare innovation, and clinical education from Mayo Clinic, Stanford, Microsoft, and industry. The discussion will focus on trust, responsible innovation, experiential learning, workforce development, and the future of anatomy education within rapidly evolving technological environments. We also hope the session encourages discussion across disciplines and career stages.

"How Would You Deconstruct It?"

A new session introduced this year, *How Would You Deconstruct It?* highlights how complex clinical questions can advance anatomical understanding through dissection, imaging, and interdisciplinary collaboration. Topics include reconstructive surgery, regional anesthesia, neurosurgical access, craniofacial procedures, and advanced fascial anatomy. The session emphasizes anatomy as an evolving investigative discipline closely tied to patient care, procedural refinement, and innovation.

Innovation in Anatomy Education

Innovation in anatomy education remains a major focus throughout this year's meeting. *Interactive workshops in clay modeling, anatomical visualization, and DICOM-based reconstruction using 3D Slicer* reflect the meeting's commitment to active learning, spatial reasoning, creativity, and technological fluency in anatomy education. These workshops encourage participants to engage anatomy through tactile, visual, and digital modalities while supporting applications in teaching, imaging, and procedural education. The continued success of the *TechFair* reflects strong member interest in sharing practical educational tools and innovations.

Accessibility, Inclusion and Community

The meeting continues to prioritize accessibility and inclusive participation through:

- Pro-rated student registration
- Day-pass
- Early student programming
- Virtual access to presentations through Planstone
- Expanded opportunities for networking and mentorship

Breakfast, lunches, and multiple receptions including an awards dinner are also included with registration to encourage conversation, networking, mentorship, and community-building throughout the meeting. These efforts are intentionally designed to reduce barriers to participation while supporting trainees, educators, clinicians, and early-career anatomists across diverse institutional and professional backgrounds.

Equally important is the continued emphasis on collegiality and community-building through receptions, committee events, collaborative workshops, and interactive sessions that foster professional connection. New this year, the meeting will also include a dedicated *Vendor Showcase* designed to encourage direct interaction between members and industry partners. These sessions will give attendees an opportunity to explore new products and technologies, ask questions, provide feedback, and discuss practical applications in anatomy education, research, and clinical practice.

Looking Ahead

As the field of clinical anatomy continues to evolve, the Annual Meeting serves as more than a traditional scientific meeting and provides a space to define where clinical anatomy is heading as a discipline.

This year's program intentionally emphasizes:

- Translational and patient-centered anatomy
- Interdisciplinary collaboration to improve patient outcomes
- Educational innovation
- Experiential learning
- Technology integration
- Professional identity and mentorship

continued on next page

The Meeting Organization and Program Planning (MOPP) Committee remains committed to continuing this momentum while preserving the collegiality, rigor, and sense of community that define the AACA. The continued growth of the Annual Meeting depends heavily on the ideas, energy, and engagement of our members. We encourage you to share ideas for workshops, scientific sessions, educational programming, and new meeting initiatives, and to consider opportunities to become involved in meeting leadership, including serving as future local hosts.

Some of the most meaningful additions to recent meetings have come directly from member suggestions and collaboration. *We also encourage all attendees to complete the post-conference survey*, as member feedback continues to play an important role in helping MOPP refine and shape future meetings for the evolving needs of the clinical anatomy community.

Confirmed future Annual Meetings include:

2027 - Texas Tech University Health Sciences Center, Lubbock, Texas

2028 - St. George's University, Grenada, West Indies

Finally, I would like to thank every member of the MOPP Committee, our local hosts, standing committee chairs, workshop coordinators, presenters, exhibitors, and attendees for their contributions to this year's meeting. The continued growth of the AACA reflects the generosity, creativity, and shared purpose of its members.

Additional details about committee activities and initiatives will be included in each committee's individual report. We encourage members to attend committee meetings, get involved, and consider opportunities to serve, as several committee positions remain open. Please feel free to reach out to MOPP Committee members with questions, suggestions, or ideas for future meetings and programming.

It has been an honor to serve as Program Secretary and MOPP Chair, and I hope this year's meeting offers inspiration, professional connection, and continued excitement for where clinical anatomy can grow as a discipline and community.

Nominating Committee Report

The 2026 Nominating Committee consisted of Members-at-Large Samir Anadkat, Erika Blanck (Chair), and Jessica Immonen, along with Presidential Appointees Keishiro Kikuchi and Hee-Jin Kim. The Committee met to review its role and responsibilities and to identify potential candidates for the open Council positions for 2026: Secretary, Special Councilor–Allied Health, and Councilor-at-Large. Throughout December and January, the Committee met to discuss and evaluate prospective candidates. In assembling the slate, the Committee was intentional in selecting individuals representing a broad range of career stages, professional roles, and areas of expertise within the AACA. The Chair contacted potential candidates to confirm their interest in standing for election. Those who agreed were included on the final slate, which was submitted to Association Secretary Mohammed Khalil and Executive Director Caitlin Hyatt. Candidates were then asked to provide a curriculum vitae, brief biography, and statement of interest.

Bylaws Committee Report for 2026 Annual Meeting

The Bylaws Committee makes recommendations to the Council on amendments to the Association's Bylaws. Over the past year, the Committee met monthly via videoconference meetings to review the Bylaws and make edits. It submitted its version of AACA Bylaws revisions that will be up for a vote at the 2026 meeting.

The proposed amendments were undertaken to better align the Bylaws with both actual and best practices, as well as to reflect important changes that have occurred in our AACA organizational structure. At the Council's request, the Committee examined specific aspects of the document where practice and policy has diverged. Updating the Bylaws is necessary to ensure that our governing document accurately reflects the Association's values, operations, and intended procedures.

continued on next page

What's changed?

Voting procedures for Special Interest Committees (Article VIII, Section 9) were revised so that nominations and voting could take place outside of the annual scientific meeting. This change will save time during the annual meeting, ensure that individuals interested in joining the committee will be invested in the work, and give the membership the opportunity to get to know the nominees prior to voting. Other areas of the Bylaws that referenced Special Interest Committees were updated to reflect this revision.

Affiliate Membership has been deleted from the Bylaws (Article II, Section 2, Subsection D). This type of membership revolved around subscriptions to the journal *Clinical Anatomy*. Paper subscriptions are no longer available.

Descriptions for the *Program Secretary* (Article V, Section 6) and *Meeting Managers* (Article VIII, Section 5, Subsection B) roles were updated to reflect current work performed by individuals in those positions.

The *Journal Committee* was deleted (Article VIII, Section 6) as it is no longer an active committee within the Association.

The *Brand Promotion and Outreach Committee* was deleted from the Bylaws (Article VIII, Section 9, Subsection E). Concerns were raised regarding recent inactivity of this committee and its ability to fulfill its designated responsibilities.

The *Committee for Community Building and Collaboration* (formerly known as the Diversity, Equity, and Inclusion Committee) was added as a standing Special Interest Committee (Article VIII, Section 9, Subsection E). Committee Chair Edgar Meyer provided a description to the Bylaws Committee for inclusion in the document.

Miscellaneous minor edits in formatting to make the document internally consistent and a few grammatical corrections were made.

Other Work

The Committee reviewed and updated its committee description, member roster, and roles and responsibilities. Goals and priorities for the next two years were created. This updated information will be posted on the Association's new website to improve transparency, strengthen member engagement, and support future recruitment efforts.

The Committee has been investigating the possibility of adding a Student Member position to several standing committees to broaden participation and develop future leaders. Conversation with Council and individual committees is ongoing.

The Committee remains actively engaged in reviewing the Bylaws available on the AACA website. Members interested in serving or learning more about the Association's operations are encouraged to attend the annual business meeting, where they can meet and interact with current committee members. Working with the Bylaws provides members with an inside look as to how the Association runs. Questions about the Bylaws or recommendations for amendments may be sent to aaca@clinical-anatomy.org.

Bylaws Committee Members

Presidential Appointees

2025-2027: Adam Kolatorowicz, Chair

2025-2027: Cara Fisher

2025-2027: Gurvinder Kaur

Elected Members-at-Large

2025-2028: Peter Ward

2025-2028: Vacant

American Association of Clinical Anatomists
Donor Statement

The AACA would like to thank the individuals who have donated their bodies and tissues for the purpose of advancing medical education and research.

Abstracts – Platform Presentations

***Tentatively Accepted for Electronic Posting on *Clinical Anatomy* Site**
(Listed by Presentation Time in Chronological Order)

PLATFORM SESSION 1 (STUDENTS) - FRIDAY, JUNE 12 FROM 11:15 AM - 12:45 PM

Friday, June 12 at 11:15 AM

* LIPISUWANCHOTE, Pichapa[1], Suphatsorn HATHAIDECHADUSADEE[2], and Jiraroch MEEVASSANA[3]. [1]Faculty of Medicine, Chulalongkorn University, Bangkok, 10330, Thailand; [2]Department of Anatomy, Faculty of Medicine, Chulalongkorn University, Bangkok, 10330, Thailand; [3]Division of Plastic and Reconstructive Surgery, Department of Surgery, Faculty of Medicine, Chulalongkorn University, Bangkok, 10330, Thailand.

Clinical Anatomy of Frontalis Borders and Variations: Implications for Botulinum Toxin Injection.

INTRODUCTION. Optimizing botulinum toxin (BoNT) efficacy in upper facial rejuvenation requires a precise understanding of frontalis muscle morphology. Inaccurate dosing across the medial and lateral borders often precipitates the "Mephisto sign" or "Samurai eyebrow." To improve clinical outcomes, this study provides a comprehensive morphometric analysis of the frontalis to establish anatomical landmarks for safer injection protocols. METHODS. Researchers examined 43 embalmed cadavers, categorizing both static forehead lines and frontalis muscle morphology into four distinct patterns (Types A–D). Lateral extension of the muscle beyond the superior temporal line (STL) was measured at 1-cm intervals (0–5 cm) superiorly from the frontalis-orbicularis oculi junction. Medial border dehiscence and angulation were assessed relative to the forehead midline and superior orbital rim. SUMMARY. A significant "line-muscle mismatch" was observed; while static lines were predominantly Type A (full form; 53.5%) or Type C (central; 37.2%), the muscle morphology was most frequently Type B (V-shaped; 72.1%). Significant correlation between lines and muscle structure was restricted to Type A ($P = 0.014$). The lateral border extended beyond the STL in 84.3% of specimens, showing progressive superior widening $5.78^{\pm}2.46$ to $12.13^{\pm}3.18$ mm in males; $5.33^{\pm}3.66$ to $12.07^{\pm}4.20$ mm in females. Medially, the mean dehiscence height was 4.60 cm in males and 3.69 cm in females, with total angulations of 69.26^{o} and 71.11^{o}, respectively. CONCLUSIONS. Static lines are poor predictors of underlying muscle anatomy. To optimize results, practitioners should define injection zones using bony landmarks. Lateral injections should follow the STL to account for muscle extension, while a toxin-free midline zone (Approx. 3.7–4.6 cm) should be maintained in cases of suspected bifurcation. Male patients generally require higher dosages and superiorly expanded treatment areas due to higher decussation points.

Friday, June 12 at 11:30 AM

* CHAIBURANONT, Natcha[1], Suphatsorn HATHAIDECHADUSADEE[2], Sorasit KARAPANON[1], Ratchathorn NAKABUT[1], and Jiraroch MEEVASSANA[3]. [1]Faculty of Medicine, Chulalongkorn University, Bangkok, 10330, Thailand; [2]Department of Anatomy, Faculty of Medicine, Chulalongkorn University, Bangkok, 10330, Thailand; [3]Division of Plastic and Reconstructive Surgery, Department of Surgery, Faculty of Medicine, Chulalongkorn University, Bangkok, 10330, Thailand.

Defining the Surgical Safety Corridor in TMJ Surgery: A Five-Landmark Anatomical Study.

INTRODUCTION. Temporomandibular joint (TMJ) surgery carries serious complications, including hemorrhage from middle meningeal artery (MMA) injury and skull base perforation during arthroscopic or peritemporal approaches. These procedures commonly rely on bony landmarks rather than direct vascular visualization, yet

continued on next page

their spatial relationship to TMJ surgical landmarks has not been well defined, particularly in Southeast Asian populations. This study therefore aimed to establish Thai morphometric data to define anatomical relationships and define predictable safety boundaries for TMJ surgery. METHODS. 128 human skulls (64 males, 64 females) were analyzed using calibrated photography and Pixit Pro a4 software. Linear distances from the foramen spinosum (FS) to the articular eminence (AE) and petrotympanic fissure (PF), along with perpendicular distances to a baseline connecting the deepest points of the bilateral glenoid fossae (GF), were measured. Statistical analysis evaluated differences by sex and sides. SUMMARY. The average distance between the AE and the FS in females and males are left (Lt.) 27.99±2.09 mm, right (Rt.) 27.65±2.35 mm, and Lt. 29.20±1.93 mm, Rt. 29.02±2.10 mm, respectively. The average FS to PF distances in females are Lt. 23.12±1.77 mm, Rt. 23.41±1.89 mm, and males are Lt. 23.81±1.92 mm, Rt. 24.31±1.68 mm. The average distance between the GF and FS in females are Lt. 3.93±1.66 mm, Rt. 4.24±1.69 mm, and in males are Lt. 4.00±1.58 mm, Rt. 4.23±1.53 mm. The average GF to PF distances in females are Lt. 5.38±1.17 mm, Rt. 5.11±0.88 mm, and in males are Lt. 5.90±1.09 mm, Rt. 5.50±0.92 mm. Males exhibited significantly greater distances than females for FS to AE (both sides $p<0.001$), FS to PF (Lt. $p=0.037$, Rt. $p=0.003$), and GF to PF (Lt. $p=0.010$, Rt. $p=0.016$). The measurements show significant asymmetry. While FS to PF is longer on the right ($p=0.003$), FS to AE and GF to PF is longer on the left ($p=0.038$ and <0.001, respectively). CONCLUSIONS. This study defines a reproducible five-landmark osseous corridor in Thai populations. Observed side- and sex-specific variation emphasizes the need for anatomical guidance to enhance TMJ-related surgical precision and safety, with side- and parameter-specific asymmetrical measurements and accounting that females generally have smaller safety margins.

Friday, June 12 at 11:45 AM

* JASTRZĘBSKI, Ignacy [1], Grzegorz FIBIGER[1], Kamil MOŻDŻEŃ[1], Michał MALCZAK[2], Maciej TOPA[1], Krzysztof KAWIAK[1], Jerzy A. WALOCHA[3] and Przemysław A. PĘKALA[3]. [1]Jagiellonian University Medical College, Faculty of Medicine, Kraków, Poland; [2]Department of Orthopedics and Traumatology, Jagiellonian University Medical College, Kraków,Poland; [3]Department of Anatomy, Jagiellonian University Medical College, Kraków, Poland.

Gracilis Tendon Morphometry and Its Clinical Anatomy: A Systematic Review and Meta-Analysis.

INTRODUCTION. The gracilis tendon is commonly used as an autograft in anterior cruciate ligament reconstruction. Accurate knowledge of its total usable length, distal tendon morphology, and muscle-tendon proportions is important for graft planning, preparation, and prediction of final construct configuration. This study synthesized available evidence to define pooled morphometric values of the gracilis muscle-tendon unit and provide an anatomical reference for surgical practice. METHODS. A systematic review and meta-analysis were performed using a comprehensive search of six databases. After screening 5839 records, eligible studies were assessed for methodological quality with a standardized anatomical quality appraisal tool. Random-effects meta-analysis was used to calculate pooled mean values with 95% confidence intervals (CI). SUMMARY. Forty-three studies were included in the quantitative synthesis. The pooled mean total usable length of the distal gracilis tendon available for graft preparation was 24.12 cm (95% CI: 21.82-26.42). The pooled mean intramuscular portion of the distal tendon was 10.66 cm (95% CI: 6.19-15.13), the visible free distal tendon from the end of the muscle belly to the pes anserinus insertion was 12.92 cm (95% CI: 11.73-14.11), and the pooled mean muscle belly length was 28.82 cm (95% CI: 28.04-29.50). These findings support the general suitability of the gracilis tendon for reconstruction while highlighting clinically relevant variation in distal tendon morphology that may affect graft harvest and preparation. CONCLUSIONS. The gracilis tendon is generally suitable for anterior cruciate ligament reconstruction on the basis of length parameters, although meaningful anatomical variation

continued on next page

exists. Pooled morphometric reference values may improve preoperative planning, intraoperative decision-making, and anticipation of graft insufficiency. (This research was funded by the Ministry of Science and Higher Education (Republic of Poland) under the program “Support for students in enhancing their competitions and skills” (Konkurs pn. Wsparcie studentów w zakresie podniesienia ich kompetencji i umiejętności), grant number [MNiSW/2025/DPI/648]. The funding supported the data analysis, manuscript preparation, and dissemination of results).

Friday, June 12 at 12:00 PM

* SHEARER, Jake[1], Sofia GIROTTI[2], Tayla MCDONALD[2], Teresia PERKINS[3], and Jonathan WISCO[1]. [1]Department of Anatomy and Neurobiology, Aram V. Chobanian & Edward Avedisian School of Medicine, Boston University, Boston, MA, 02118, USA; [2]College of Arts and Sciences, Boston University, Boston, MA, 02215, USA; [3]Aram V. Chobanian & Edward Avedisian School of Medicine, Boston University, Boston, MA, 02118, USA.

Documenting a Lateral Approach Basal Ganglia Dissection Protocol Using Surface Scanning Technology.

INTRODUCTION. The basal ganglia are a collection of deep, interconnected subcortical nuclei. They function as a crucial integrative region for neurocircuitry involved in motor control, learning, reflexes, and behavior. Traditional reference materials rely on schematics or dissection photographs. These fail to convey spatial relationships such as volume, depth, and adjacency, which define the functional connectivity of these structures. This architectural complexity can be challenging for trainees to understand. RESOURCES. Ten craniotomies were performed on body donors at Boston University. One brain was selected for its degree of fixation, lack of damage, and structural integrity. The specimen was dissected using a modified Klingler technique. This approach leverages the material contrast between white and gray matter. DESCRIPTION. A lateral-to-medial dissection protocol was performed, proceeding through the following layers: 1) Removal of cortical gray matter; 2) Removal of the insular cortex to expose the extreme capsule and claustrum; 3) Dissection of the claustrum and external capsule to reveal the putamen; 4) Delineation of the putamen and dissection of the external medullary lamina to expose the globus pallidus; 5) Exposure of the internal capsule and the caudate nucleus; 6) Exposure of the thalamus. Each step of the dissection was surface scanned in duplicate using an Artec Space Spider and RealityScan. SIGNIFICANCE. This stepwise dissection and imaging protocol provides a means to create robust, effective pedagogical tools for studying spatial relationships. Dissection is necessarily a one-way process; you cannot replace the tissue you remove. By cataloging the steps in 3D, these become robust assets that provide a clear topological narrative of the anatomy. The assets can be reused after the donor’s remains have been returned.

Friday, June 12 at 12:15 PM

* JOSE, Revin J. K.[1], Juan CHOI[1], Sayed Aheed SHAH[1], Shwe Yee WIN MOHT MOHT[1], Vivin C. A. SANTHAPPA[1],Michael ADENIYI[1], Nansak DASHE[1], and Sadia JAVAID[1]. [1]St. George’s International School of Medicine, Northumbria University, Newcastle, NE1 8ST, United Kingdom.

Interobserver Reliability of Ultrasound Identification and Measurement of Berrettini Anastomosis.

INTRODUCTION. Accurate morphometric characterization of the Berrettini anastomosis (BA) requires reliable ultrasonographic identification and measurement. Despite growing interest in the in-vivo anatomy of palmar digital nerve communications, no study has assessed interobserver reliability for independent ultrasound acquisition and measurement of the BA. This study aimed to determine the interobserver reliability of ultrasound-

continued on next page

based detection and measurement of the BA. METHODS. Fifteen participants (30 hands) were independently scanned by two blinded observers using high-frequency linear transverse-plane ultrasound. Each observer independently acquired images with a technician, identified the BA, and measured width, length, and depth from the skin. Detection agreement was assessed using Cohen's kappa and prevalence-adjusted bias-adjusted kappa (PABAK). Reliability was evaluated using ICC(2,1) with 95% CIs. Bland-Altman analysis assessed systematic and proportional bias. Standard error of measurement, smallest detectable change, and coefficient of variation (CV%) were computed. SUMMARY. Detection agreement was 96.7% (kappa=0.783; PABAK=0.933). McNemar's test confirmed no systematic detection bias (p=1.000). ICC(2,1) values were: width 0.092 (95% CI: -0.300 to 0.460), length -0.233 (-0.580 to 0.170), and depth 0.447 (0.100 to 0.700). Bland-Altman analysis revealed no systematic bias (width: -0.003mm; length: -0.005mm; depth: -0.019mm; all p>0.05) and no proportional bias (all p>0.05). CV% ranged 12.5-15.2%. Variance component analysis attributed low ICCs to restricted biological range rather than measurement imprecision. CONCLUSIONS. Ultrasound detection of the BA demonstrated substantial interobserver agreement. Morphometric measurements showed acceptable precision with no systematic or proportional bias. These findings support high-frequency ultrasound as a reproducible tool for in vivo BA research and establish the first interobserver benchmarks for this structure.

Friday, June 12 at 12:30 PM

* ANTHONY, Lauren[1], Christine VO[2], Jason WAGNER[3], Avery RICHARDSON[1], and Mary MOON[4]. [1]College of Medicine, University of Oklahoma Health Center, Oklahoma City, OK, 73104, USA; [2]Department of Anesthesiology, OU Health, Oklahoma City, OK, 73104, USA; [3]Department of Radiologic Sciences, OU Health, Oklahoma City, OK, 73104, USA; [4]Department of Cell Biology, University of Oklahoma Health Center, Oklahoma City, OK, 73104, USA.

Direct Hepatic Ultrasound to Reinforce Portal System Spatial Relationships in Anatomy Education.

INTRODUCTION. Donor dissection remains foundational in anatomy education, promoting tactile learning, psychomotor skill development, and professional formation. Trainees must also develop ultrasound competency, translating 2D sonographic images into 3D anatomical understanding. Although ultrasound improves spatial reasoning and clinical correlation, direct donor imaging is limited by postmortem gas artifact. While extremity musculoskeletal ultrasound has been described in donors, this approach has not been applied to layered abdominal dissection. This study evaluates the feasibility of direct ultrasound application to the exposed liver to enhance visualization of the portal vein, hepatic artery, and bile duct while strengthening 2D–3D integration. RESOURCES. A soft-fixed donor underwent layered anterior abdominal wall dissection. Imaging was performed using a GE Logiq V2 ultrasound machine with an L12-6 linear transducer. Water-soluble gel was applied directly to the hepatic capsule to optimize acoustic coupling and eliminate air artifact. DESCRIPTION. The abdominal wall was dissected in layers with preservation of fascial planes for reapproximation. After liver exposure, the L12-6 transducer was placed directly on the hepatic surface. Longitudinal and transverse imaging of the hepatic parenchyma and porta hepatis identified the portal triad. The abdominal wall was then reapproximated to reconnect surface landmarks with internal sonographic orientation, reinforcing probe-to-structure relationships. Direct probe placement minimized gas artifact and clarified portal triad orientation relative to surface anatomy, strengthening translation between dissection and real-time imaging. SIGNIFICANCE. This accessible model enhances integration of donor dissection and ultrasound while addressing known imaging limitations. By linking probe mechanics, 2D acquisition, and 3D structure, it supports competency-based imaging education across disciplines.

continued on next page

PLATFORM SESSION 2 (TRANSLATIONAL AND CLINICAL ANATOMY) - SATURDAY, JUNE 13 FROM 8:45 AM - 10:00 AM

Saturday, June 13 at 8:45 AM

* MAZZOGLIO Y NABAR, Martín[1,2,3,4], Elba Beatriz TORNESE[1,3,4], and Rubén Daniel ALGIERI[1,2,4]. [1]Faculty of Medical Sciences, University of Buenos Aires, Buenos Aires, C1414DQJ, Argentina; [2]Argentine Society of Applied Morphological Sciences, Buenos Aires, C1414DQJ, Argentina; [3]APSA Neuroscience Chapter, Buenos Aires, C1021,AAO, Argentina; [4]Interdisciplinary Center for Forensic Research, National Academy of Sciences of Buenos Aires, Buenos Aires, C1021AAO, Argentina.

Neurocognitive Impairment in HIV: Anatomo-clinical Correlation through Functional Neuroimaging.

INTRODUCTION. HIV-associated neurocognitive disorders (HAND) persist despite sustained viral suppression with highly active antiretroviral therapy (HAART). Although severe dementia has declined, milder forms remain prevalent. Neuropathological evidence identifies basal ganglia and cortical regions as central nervous system reservoirs. Early detection is clinically relevant to guide cognitive rehabilitation strategies. This study aimed to characterize neurofunctional alterations in cortical and subcortical structures in people living with HIV (PLWH) with HAND and to correlate imaging findings with clinical stage. METHODS. Seventy-two male PLWH aged 24–72 years (mean 46.3 ± 12.6), on HAART for more than 5 years with undetectable viral load (<40 RNA copies/mL) and neurocognitive symptoms, were included. HAND was classified according to American Academy of Neurology (2007) criteria. Exclusion criteria comprised central neurological disease, psychotropic medication (antipsychotics or mood stabilizers), recent substance use, traumatic brain injury, or neurosurgery. Participants underwent standardized neuropsychological and neuropsychiatric assessments. Functional neuroimaging was performed using 99mTc-ECD SPECT with attenuation correction and semiquantitative perfusion analysis. SUMMARY. Functional abnormalities were frequent and stage-dependent. Significant hypoperfusion involved the anterior cingulate gyrus, left dorsolateral prefrontal cortex, basal ganglia (predominantly left-sided), and left anterior insula, correlating with ipsilateral caudate and cingulate regions. Perfusion deficits were proportional to cognitive severity, particularly in patients with prominent apathy. CONCLUSIONS. HAND demonstrates consistent neurofunctional patterns correlating with clinical stage, supporting the utility of functional neuroimaging in comprehensive assessment.

Saturday, June 13 at 9:00 AM

* KIKUCHI, Keishiro[1], Kosuke TABUCHI[1], Seiichi INOUE[2], Akihiro YAMASHITA[1], Shotaro KINOUCHI[1], Ryuki HASHIDA[1], Yoko TABIRA[2], Joe IWANAGA[3], R. Shane TUBBS[3], Koji HIRAOKA[1], and Koichi WATANABE[2]. [1]Department of Orthopaedic Surgery, Kurume University School of Medicine, Kurume, Fukuoka, 8300011, Japan; [2]Department of Anatomy, Kurume University School of Medicine, Kurume, Fukuoka, 8300011, Japan; [3]Department of Neurosurgery, Tulane Center for Clinical Neurosciences, Tulane University School of Medicine, New Orleans, LA, 70112, USA.

Ethnic Differences of the Superficial Tibial Collateral Ligament Distal Tibial Attachment.

INTRODUCTION. During anatomical reconstruction techniques for the tibial collateral ligament (TCL), the distance from joint line to superficial TCL distal tibial attachment (sTCL-dTA) is a significant landmark. Although recent anatomical studies have suggested a potential ethnic difference in this distance, a precise comparative evaluation has not yet been conducted. Therefore, the purpose of the present study was to compare the distance from joint

continued on next page

line to the sTCL-dTA between ethnic groups. METHODS. Forty unpaired formalin-fixed cadaveric knees were used in this study, including twenty knees each from Japanese and Caucasian cadavers. The tibia and superficial tibial collateral ligament (sTCL) were divided into two sections in the paracoronal plane along the midline of the sTCL. In the paracoronal section, the sTCL-dTA was identified. The distance from the medial edge of the tibial plateau to the proximal margin, center, and distal margin of the sTCL-dTA and the length of the sTCL-dTA were measured. Each measurement was compared between the Japanese and Caucasian groups using Wilcoxon rank sum test. SUMMARY. The distance from the medial edge of the tibial plateau to the proximal margin, center, and distal margin of the sTCL-dTA were 38.5 (IQR: 35.2–40.0), 49.2 (IQR: 46.7–52.3), and 60.6 (IQR: 58.4–64.7) mm in the Japanese group and 47.4 (IQR: 44.2–50.3), 62.7 (IQR: 55.7–64.5), and 75.5 (IQR: 66.7–78.1) mm in the Caucasian group, respectively. The length of the sTCL-dTA was 23.7 (IQR: 21.0–25.0) mm in the Japanese group and 25.6 (IQR: 23.2–27.8) mm in the Caucasian group. All measurements were significantly shorter in Japanese group than in Caucasian group ($p<0.05$). CONCLUSIONS. The distance from the joint line to the sTCL-dTA differs among ethnic groups and should be recognized during anatomical reconstruction of the TCL..

Saturday, June 13 at 9:15 AM

* MAZZOGLIO Y NABAR, Martín[1,2,3,4], Agustín Daniel ALGIERI[1,2], Soledad FERRANTE[1,2], Rubén Daniel ALGIERI[1,2,4], and Elba Beatriz TORNESE[1,3,4].[1]Faculty of Medical Sciences, University of Buenos Aires, Buenos Aires, C1414DQJ, Argentina; [2]Argentine Society of Applied Morphological Sciences, Buenos Aires, C1414DQJ, Argentina; [3]APSA Neuroscience Chapter, Buenos Aires, C1021,AAO, Argentina; [4]Interdisciplinary Center for Forensic Research, National Academy of Sciences of Buenos Aires, Buenos Aires, C1021AAO, Argentina.

Differential Gyrus Rectus Neuroanatomy in Antisocial Disorder: Correlations with MRI, SPECT and PET.

INTRODUCTION. The gyrus rectus, within the medial orbitofrontal circuit, is implicated in behavioral inhibition, moral reasoning, and impulse control. Structural abnormalities in this region have been associated with impulse-control disorders, psychopathy, frontotemporal degeneration, and violent behavior. Although PET studies have reported functional alterations in antisocial personality disorder (ASPD), synaptic density in this region has not been specifically examined. We aimed to characterize structural and functional alterations and quantify differential synaptic density of the gyrus rectus in ASPD with and without psychopathy. METHODS. Forty-three adults (26–52 years; mean 40.1±7.4) diagnosed with ASPD (ICD-10 F60.2; DSM-5 301.7), with and without psychopathic traits, were evaluated. Exclusion criteria included neurological disorders and traumatic brain injury. Assessments comprised psychiatric and neuropsychological testing, 1.5T morphometric MRI, 99mTc-ECD SPECT, and 18F-SynVesT-1 PET for synaptic density analysis. Statistical testing was performed under ethical approval. SUMMARY. Significant morphometric and functional reductions were observed in ASPD without psychopathy (volume –18.4%; perfusion –12.7%) and with psychopathy (volume –11.5%; perfusion –6.1%) ($p<0.001$; $p<0.05$). Synaptic density reduction was smaller in ASPD without psychopathy (–4.9%, $p<0.05$) than in ASPD with psychopathy (–9.6%, $p<0.01$). CONCLUSIONS. ASPD shows focal structural and functional reduction of the gyrus rectus. Although macrostructural deficits were greater in non-psychopathic cases, synaptic loss was more pronounced in psychopathy. Findings suggest microstructural dysfunction affecting inhibitory–excitatory balance in circuits regulating fear conditioning, punishment learning, moral decision-making, and cognitive empathy. These results support a neurodevelopmental GABA/glutamate imbalance model and have potential implications for neurolaw and criminal responsibility.

continued on next page

PLATFORM SESSION 3 (EDUCATION) - SATURDAY, JUNE 13 FROM 10:15 AM - 11:15 AM

Saturday, June 13 at 10:15 AM

* IDRISS Ahmedou M[1]., Aboubacry SOW[1], Elhaj ADDE[1], Sid'A. LIMAM[1], Tfeil YAHYA[1], Juan ALZOLA[2], Gabor FISHTINGER[3], Sonia PUJOL[4], Ron KIKINIS[4], and Mike HALLE[4]. [1]Clinical Anatomy Research Unit, Anatomy Lab., FMPOS / EN3S, Nouakchott University, Nouakchott, BP 380, Mauritania; [2]University of Las Palmas de Gran Canarias Las Palmas, 35016, Spain; [3]Perk's Lab., Queen's University, 25 Union St, Kingston,Canada; [4]Brigham and Women's Hospital, Harvard Medical School, Boston, MA, 02115, USA.

Interactive Digital Imaging Tools for Active Anatomy Learning in Resource-Limited Settings.

INTRODUCTION. Many anatomy courses still ask students to learn largely by looking at textbook figures, slides, or cadaver photographs. This can make it hard to build strong 3D understanding or connect anatomy to the way clinicians actually see the body on imaging. We tested a curriculum that turns students into "image investigators," working directly with real CT/MRI data. METHODS. First-year medical and dental students in the intervention group (n=80) completed a semester module using the open-source platform 3D Slicer and anonymized patient CT/MRI scans. Step-by-step virtual dissection activities included navigating cross-sectional planes, manually segmenting organs and vessels, and building 3D reconstructions. Tasks were scaffolded from basic identification to higher-level analysis and creation. A comparison group (n=80) learned with traditional resources (textbook images, lectures, cadaveric photographs). Outcomes included pre/post spatial anatomy tests, practical 3D identification and segmentation on unfamiliar datasets, and engagement surveys. SUMMARY**.** Intervention students scored higher on spatial anatomy tests (84.2%±8.1 vs 71.5%±9.3; $p<0.01$). They also segmented structures more accurately (Dice 0.89±0.05 vs 0.74±0.10; $p<0.01$). Survey ratings favoured the intervention for engagement (4.6 vs 3.8), understanding (4.4 vs 3.7), and confidence (4.3 vs 3.5); 90% agreed that working with authentic imaging improved their spatial understanding. CONCLUSIONS. Giving students hands-on control of real medical imaging culminating in their own segmentations and 3D models improves spatial learning, practical imaging-based anatomy skills, and engagement compared with passive instruction, while using accessible open-source tools.

Saturday, June 13 at 10:30 AM

* TABIRA, Yoko[1], Joe IWANAGA[1,2], Hisashi NAKAMURA[1], Seiichi INOUE[1], Tatsuya HARANO[1], Keigo SHIMIZU[1], Mitsuru TANAKA[1], Tsuyoshi SAGA[3], R. Shane TUBBS[2], and Koichi WATANABE[1]. [1]Department of Anatomy, Kurume University School of Medicine, Kurume, Fukuoka, 8300011, Japan; [2]Department of Neurosurgery, Tulane University School of Medicine, New Orleans, LA 70112, USA; [3]Domain of Anatomy, Kurume University School of Nursing, Kurume, Fukuoka, 8300003, Japan.

Impact of a Best Ethical Practice in Anatomy (BEPA) Curriculum on Students' Professional Identity.

INTRODUCTION. An anatomical dissection course represents the first structured encounter with death in medical education and significantly influences early Professional Identity Formation (PIF). The Best Ethical Practice in Anatomy (BEPA) framework promotes donor-centered terminology and respectful conduct; however, its differential impact across varying baseline levels of ethical awareness remains unclear. This study examined whether a BEPA-aligned anatomy curriculum demonstrates stratified patterns of ethical development. METHODS. In 2025, a longitudinal pre-post survey was conducted among 132 second-year medical students. Ethical

continued on next page

awareness was assessed using a 35-item instrument addressing empathy and responsibility. Additionally, in line with established medical education learning outcomes, self-evaluations of achievement were collected across the cognitive, psychomotor, and affective domains. Students were stratified into higher- and lower-baseline awareness groups for comparative analysis. SUMMARY. Overall, ethical development was observed across the cohort. Students with higher baseline awareness maintained elevated levels, suggesting a ceiling pattern. In contrast, students with lower baseline awareness demonstrated clear upward trends, converging toward the cohort mean by the end of the course. Notably, self-evaluation scores for achievements in cognitive, psychomotor, and affective domains showed significant increases post-intervention compared to pre-course baselines ($p < 0.05$). CONCLUSIONS. A BEPA-based anatomy curriculum may function as a leveling-up mechanism that supports professional attitudes regardless of initial background. Respectful terminology and recognition of body donation as a meaningful contribution provide a foundational framework for achieving core competencies and reducing variability in early PIF.

Saturday, June 13 at 10:45 AM

* MEHRABAN, Amir R.[1], Elias VILLARREAL[2], Nassim IDOURAINE[2], Jahanzeb KHAN[2], and Edreece TAEB[2]. [1]Division of Medical Education, University of California San Diego School of Medicine, La Jolla, CA, 92093, USA; [2]Atkinson Physician Assistant Education Program, University of California San Diego School of Medicine, La Jolla, CA, 92093, USA.

Intuition and Presence: Reimagining Surgical Anatomy through Immersive Tech and Compassion Practice.

INTRODUCTION. With the growing reliance on technology in medical training, anatomy instruction must deliberately advance both technical intuition and humanistic presence. The purpose of this project was to design and implement an innovative surgical anatomy laboratory that integrates immersive technology with structured compassion cultivation training to enhance spatial understanding, clinical judgement, and compassionate capacity. RESOURCES. The laboratory incorporates annotated 360-degree operative footage delivered through virtual reality headsets, activity protocols designed for facilitated completion using a virtual dissection table, and evidence-informed compassion cultivation training that includes guided contemplative exercises and facilitated reflective discussion prompts. DESCRIPTION. Students begin with structured compassion cultivation training sessions that frame compassion as a transferable life skill as well as a clinical competency, equipping them to cultivate resilience, self awareness, and empathic presence in their own lives and future patient care. Learners then engage in immersive virtual reality sessions presenting operative procedures from the surgeon's perspective, emphasizing aspects such as dynamic anatomy, intraoperative decision making, spatial orientation, instrument handling, and operating room team interactions. Finally, students translate observation into applied anatomical understanding through facilitated virtual dissection table activities such as three-dimensional exploration of regional anatomy, critical structures, and surgical landmarks; procedural planning exercises such as laparoscopic port placement; and correlation of cross sectional imaging with operative views. SIGNIFICANCE. This multimodal model bridges immersive operative visualization, digital simulation-based anatomy application, and compassion cultivation pedagogy within a single educational environment. By uniting these elements, the laboratory provides a scalable framework for clinical anatomy education that prepares learners to become technically proficient, reflective, and humane providers of care capable of navigating complex medical and interpersonal landscapes.

continued on next page

Saturday, June 13 at 11:00 AM

* FORSTON, Morgan J.[1], Tatum SCHULZ-FISCHBACH[2], Punnose KATTIL[1], and Nirusha LACHMAN[1].[1]Department of Clinical Anatomy, Mayo Clinic, Rochester, MN, 55902, USA; [2]Surgical First Assistant Program, Mayo Clinic School of Health Sciences, Mayo Clinic, Rochester, MN, 55902, USA.

Integrating Surgical Videos into the Anatomy Laboratory for Surgical First Assistant Students.

INTRODUCTION. Surgical first assistants (SFAs) play a critical intraoperative role, supporting exposure, retraction, hemostasis, and protection of vital structures. Anatomical competency enables SFAs to apply knowledge safely during real-time operative decisions. The Mayo Clinic SFA Program includes a 6-week cadaver based Applied Surgical Anatomy course. The quick transition into practice requires significant opportunity for simulation-based learning to reduce the steep learning curve. Historically, cadaveric laboratory sessions were enhanced by surgical video assignments that required students to view surgical videos and answer anatomical questions. However, these were separate activities, limiting opportunity to connect learning constructs. We hypothesized that bridging 2D operative videos with 3D cadaveric exploration through Integrated Sessions would enhance confidence and support professional identity formation. METHODS. Across 7 anatomical regions, 20 students viewed a surgical video and completed a pre-session 10-point Likert survey assessing confidence in identifying landmarks, anticipating at-risk structures, and interpreting operative anatomy. The following day, students engaged in small-group discussions at the cadaver table with the video displayed bedside. Groups were audio-recorded, transcribed, and de-identified and students completed a parallel post-session survey. Guided by a constructivist framework, a mixed thematic analysis was conducted on transcripts to explore changes in technical and non-technical skills. SUMMARY. Across sessions, students demonstrated pre–post gains in confidence and self-efficacy with moderate effect sizes, measured by paired t-tests and repeated measures ANOVA. Thematic analysis revealed improved spatial reasoning, anticipation of at-risk structures, and development of non-technical skills such as collaborative construction and reduced hesitation. CONCLUSIONS. These findings suggest simulation-based integration enhances students' confidence in applying anatomy and supports professional readiness for the surgical practice environment.

continued on next page

PLATFORM SESSION 5 (TRANSLATIONAL) - SUNDAY, JUNE 14 FROM 2:00 PM – 3:00 PM

Tentatively Accepted for Electronic Posting on Clinical Anatomy Site
(Listed Chronologically by Presentation Time)

Sunday, June 14 at 2:00 PM

* WATANABE, Koichi[1], Mizuho TAKAYA[2], Eiko INOUE[1], Hisashi NAKAMURA[1], Seiichi INOUE[1], Yoko TABIRA[1], Joe IWANAGA[3], and Tsuyoshi SAGA[4]. [1]Division of Gross and Clinical Anatomy, Department of Anatomy, Kurume University School of Medicine, Kurume, Fukuoka, 8300011, Japan; [2]Kurume University School of Medicine, Kurume, Fukuoka, 8300011, Japan; [3]Department of Neurosurgery, Tulane University School of Medicine, New Orleans, LA, 70112, USA; [4]Domain of Anatomy, Kurume University School of Nursing, Kurume, Fukuoka, 8300003, Japan.

Identifying The Cause of Upward Gaze Limitation in Orbital Floor Fractures.

INTRODUCTION. Limitation of upward gaze following orbital floor fractures has traditionally been attributed primarily to entrapment of the inferior rectus muscle. However, it is well recognized that factors other than direct muscle entrapment—particularly entrapment of orbital fat—may also contribute to impaired ocular motility. The objective of this study was to anatomically examine the relationship between the inferior rectus muscle and orbital fat to elucidate the mechanism underlying the limitation of upward gaze. METHODS. Orbital tissues were harvested from 13 sides of 13 formalin-fixed cadavers. On three sides, the inferior rectus muscle, inferior oblique muscle, orbital fat, orbital wall, and lower eyelid were excised en-bloc and macroscopically dissected under magnification. In addition, histological sections were prepared from these three specimens and examined using light microscopy. Micro-CT scans were performed on seven sides, including the inferior orbital wall, to analyze the three-dimensional spatial relationship between the inferior rectus muscle and orbital fat. SUMMARY. Macroscopic dissection revealed fibrous extensions originating from the inferior rectus muscle toward the medial and central fat pads of the lower eyelid. These findings were confirmed in histological sections and micro-CT imaging. Furthermore, micro-CT demonstrated that not only the inferior rectus muscle, but also orbital fat pads are located medial to the inferior orbital fissure, a region where orbital floor fractures frequently occur, thereby identifying this area as a potential site of fat entrapment. CONCLUSIONS. Because the medial and central fat pads of the lower eyelid are fibrously connected to the inferior rectus muscle, entrapment of orbital fat at the fracture site may restrict relaxation of the muscle and result in limitation of upward gaze. Therefore, careful evaluation and adequate release of entrapped orbital fat should be considered during surgical repair.

Sunday, June 14 at 2:15 PM

* IMMONEN, Jessica A, Nasser ABDELHADY, Makayla BOEKES, Jared CLOUSE, Zach LARSON, Grace SCHMITT, Lucia ZHANG, Jyoti MAGO and Sung KIM. School of Dental Medicine University of Nevada Las Vegas, Las Vegas, NV, 89106, USA.

Improving Diagnosis and Management of TMJ Osteoarthritis with Cadaveric CBCT-Acquired Data.

INTRODUCTION. Temporomandibular joint (TMJ) disorders, including TMJ osteoarthritis (OA), are the second most common musculoskeletal condition and may affect 5-12% of the population. The objective of this study was to assess osseous changes and flatness ratios in TMJ CBCT scans (N=8) and compare findings to paired dissections. METHODS. Disarticulated cadaver heads were imaged using an i-CAT scanner at three dosages. Flatness ratios were measured and osteoarthritic indicators (OAIs) were evaluated to determine thresholds for

continued on next page

diagnostic clarity and reviewer confidence in Invivo Workspace. After imaging and dissection, a disease severity score (Grade 0-4) was awarded to each specimen. SUMMARY. Inter-reviewer discrepancy in diagnosing OAIs was greatest with the low-dose protocol; the highest disagreement occurred in detecting erosions, followed by surface irregularity, and then flattening of the condyle. Assessment of OAIs suggest progressive changes from Grade 2 to 3. Grade 3 specimens radiologically demonstrated greater structural variability and pronounced pathology. Radiology flatness ratios (mean = 0.28) and gross flatness ratios (mean = 0.26) were statistically comparable (p = 0.20). Radiological flatness ratios for the low-angled variants (mean = 0.23; n=8) were consistently smaller than that of high-angled variants (mean = 0.42; n=3). CONCLUSIONS. Collectively, three assessments have improved the field's understanding of radiographic interpretation of TMJ OA. Findings suggest that osseous changes are more difficult to evaluate using lower dose imaging. The variability of OAIs within Grade 3 joints emphasizes the need for multi-parameter evaluation when assessing disease severity and correlating structural findings with functional outcomes. There may be predictive value in CBCT-acquired flatness ratios for TMJ OA; use of this technique may lead to earlier detection of OA and implementation of conservative therapies.

Sunday, June 14 at 2:30 PM

* KITAGAWA, Norio[1] and Joe IWANAGA[2]. [1]Department of Oral and Maxillofacial Anatomy, Graduate School of Medical and Dental Sciences, Institute of Science Tokyo, Tokyo, 1138510, Japan; [2]Department of Neurosurgery, Tulane Center for Clinical Neurosciences, Tulane University School of Medicine, New Orleans, LA, 70112, USA.

Coordinate-Based Map of the Greater Palatine Artery: Defining a Predictable Grafting Safe Zone.

INTRODUCTION. In periodontal plastic surgery, the palatal mucosa is a primary donor site for soft tissue grafts. During harvesting, preventing injury to the greater palatine artery (GPA) is essential to avoid complications. While previous studies focused on the distance from the cementoenamel junction (CEJ) to the GPA, they did not account for arterial depth within the mucosa or its angular relationship to the gingival margin. This study aimed to provide standardized anatomical data to enhance harvesting safety through a more stable reference system. METHODS. Coronal sections were obtained from formalin-fixed cadaver palates. To ensure accurate vessel identification, paraffin-embedded sections were stained with Masson's Trichrome and overlaid with corresponding unstained macroscopic images. Using ImageJ, clinically relevant landmarks, including the gingival margin, were identified on molar specimens. In each specimen, distances and angles between these landmarks and the GPA were quantified within a specialized coordinate system to normalize anatomical variations. SUMMARY. The average mucosal thickness overlying the GPA main trunk was 5.3 $\pm$ 1.7 mm. Within the y-axis (depth), the GPA was absent in the superficial 43.0% of the mucosal thickness, with a median depth at 73.0%. Along the x-axis (lateral), the GPA was absent up to 45.2% of the distance from the midline, with a median location at 70.4%. The average angle of the GPA relative to the gingival margin was $60.8^{o} \pm 9.7^{o}$. CONCLUSIONS. This study establishes an anatomical basis for preventing GPA injury by introducing a coordinate system accounting for variations in palatal size and shape. By normalizing these locations within a coordinate framework, we identified a predictable "safe area" within the superficial 40% of the mucosal thickness. These quantitative findings offer a precise guide to minimize vascular complications, independent of variable dental landmarks like the CEJ.

continued on next page

Sunday, June 14 at 2:45 PM

* BISHOP, Keith[1], Chris R. RIGGS[2], Austin A. ALEXANDER[2], Mariam A. IBRAHIM[3], Kerry K. GILBERT[4], and Jean-Michel BRISMÉE[3].[1]Department of Medical Education, Texas Tech University Health Sciences Center, Lubbock, TX, 79430, USA; [2]College of Health and Clinical Professions, Tarleton State University, Stephenville, TX, 76402, USA; [3]Center for Rehabilitation Research, Department of Rehabilitation Sciences, Texas Tech University Health Sciences Center, Lubbock, TX, 79430, USA. [4]Institute of Anatomical Sciences, Texas Tech University Health Sciences Center, Lubbock, TX, 79430, USA.

Ultrasound vs Palpation-Guided First CMC Joint Injection Accuracy and Learning Curve.

INTRODUCTION. First carpometacarpal (CMC) joint osteoarthritis is common and frequently managed with intra-articular corticosteroid injection. Intra-articular placement produces superior pain and functional outcomes compared to extra-articular injection, making accuracy clinically meaningful. This study compared injection accuracy between ultrasound-guided and palpation-guided technique in physical therapists without prior injection training and examined the effect of structured anatomical feedback on learning. METHODS. Eight un-embalmed cadaveric specimens (16 hands; mean age 81.0±10.5 years; 5 male, 3 female) were used. Two physical therapists without injection experience each performed all injections for one technique: one used a GE Totus ultrasound system; the other used palpation landmarks. Each hand received both techniques (22-gauge needle, 1mL dye) with randomized dye color and injection order to blind two experienced anatomists who independently scored each injection as intra-articular (hit) or extra-articular (miss). Structured anatomical feedback was provided once after the first four injections. Chi-square analysis compared overall accuracy. SUMMARY. Overall accuracy was 81% (13/16) for ultrasound-guided and 38% (6/16) for palpation-guided technique (χ^2=6.35, φ=0.45, p=0.012). Both techniques achieved 25% accuracy pre-feedback. Post-feedback, ultrasound-guided accuracy improved to 100% (12/12) while palpation-guided reached 42% (5/12), demonstrating a marked learning curve advantage for the ultrasound-guided approach. CONCLUSIONS. Ultrasound guidance significantly improved first CMC joint injection accuracy and accelerated skill acquisition following anatomical feedback, achieving 100% accuracy. These findings support integrating ultrasound guidance into physical therapist injection training curricula.

Sunday, June 14 at 3:00 PM

* NOEL, Geoffroy PJC[1], Austin NGUYEN[2], Nathaniel M SCHUSTER[2]. [1]Division of Anatomy, Department of Surgery, University of California San Diego, La Jolla, CA, 92093, USA; [2]Department of Anesthesiology, University of California San Diego, La Jolla, CA, 92093, USA.

Ultrasound-Guided Injection Improves Accuracy of Lateral Pterygoid Injections.

INTRODUCTION. As temporomandibular disorders (TMDs) are often a common cause of physical pain and decreased quality of life, treatment options for patients with TMDs refractory to standard of care may include botulinum toxin (BTX-A) injections. These injections are most often localized to the masseter, and sometimes also the lateral pterygoid muscle (LPM). However, little research has assessed the relative accuracy of ultrasound (US)-guided versus landmark-guided injections of the LPM and masseter. We therefore conducted a cadaveric study to measure the accuracy of landmark-guided versus US-guided injections for extra-orally injecting the LPM and masseter. METHODS. Six human anatomical specimens were injected with a 0.1-0.2 ml of 0.25% methylene blue

continued on next page

dye into the masseter and lateral pterygoid muscles. Injection was performed either with or without US guidance. Following injections, dissection were completed to isolate the muscles and examine the location of the dye. SUMMARY. All US-guided lateral pterygoid injections were successful, with 25% demonstrating partially intra-arterial injections into the maxillary artery, while only 33% suurface landmark-guided lateral pterygoid injections were successful. Furthermore, all masseter injections were successful, which included with US guidance and with landmark guidance. CONCLUSIONS. US guidance improves the accuracy of LPM injections while masseters can be accurately injected with or without US guidance. 25% of US guided injections resulted in intra-arterial maxillary artery injection, demonstrating the importance of vigilance for the maxillary artery during injections involving the LPM. These results reproduce the findings of the prior technical note on US-guided LPM injection and calls into question the accuracy of landmark-guided percutaneous LPM injections. Future clinical trials studying the benefit of botulinum toxin injections for TMD should include cadaver training for injectors and US guidance if the LPM is to be targeted.

continued on next page

Abstracts – TechFair Presentations

***Tentatively Accepted for Electronic Posting on *Clinical Anatomy* site**
(Listed Chronologically by Presentation Time)

SESSION 4 TECHFAIR - SATURDAY, JUNE 13 FROM 3:30 PM - 4:30 PM

Saturday, June 13 at 3:30 PM

* HENSLEY, Jessica L., Gavin SMITH, and Ethan L. SNOW. College of Natural Sciences, South Dakota State University, Brookings, SD, 57007, USA.

Improving Anatomy Preparedness and Learning Outcomes with Virtual Reality Pre-Lab Sessions.

INTRODUCTION. Virtual reality (VR) has become a widely utilized teaching tool, particularly in disciplines where immersive visuospatial learning is emphasized (e.g., anatomy). Where students may be limited to intermittent use of VR resources, studies suggest VR may be especially effective before formal instruction. The purpose of this study is to evaluate student preparedness and academic performance after voluntary involvement in VR pre-lab sessions implemented throughout a high-enrollment human anatomy curriculum. METHODS. Before each scheduled laboratory (n=12), VR pre-lab sessions were offered to undergraduate students (n=312) enrolled in a Fall 2025 cadaver-based human anatomy laboratory curriculum. Pre-recorded instructional videos were disseminated to ensure participants were equipped with effective VR navigation skills. The in-person sessions utilized human anatomy software in VR head-mounted displays, and asynchronous sessions utilized pre-recorded VR videos. Post-session surveys were conducted to gauge student perceptions, and course grades were evaluated for impact from participation. SUMMARY. Most of the students (91.6%) indicated the VR pre-lab sessions made them feel prepared (4/5) or very prepared (5/5) for subsequent laboratory sessions. Students who participated in the VR pre-lab sessions achieved a higher mean final course grade (79.6%) compared to non-participants (70.8%; Welch's t-test, $p<0.01$). A multiple linear regression analysis accounted for potential confounding variables, including year in college, declared major, prior VR and anatomy experience ($p>0.01$), and use of other course resources ($p<0.01$). CONCLUSIONS. This study demonstrates how integrating VR as pre-lab sessions can improve student preparedness and academic performance in undergraduate human anatomy curricula. Translational applications of this study may help educators effectively incorporate intermittent VR use in both synchronous and asynchronous learning environments.

Saturday, June 13 at 3:35 PM

* NELSON, Melissa K.[1], Dylan M. BAUMGARTNER[1], Rylan M. WILLIS[2], Stephen GENT[1], Erik RITTER[3], and Ethan L. SNOW[4]. [1]Jerome J. Lohr College of Engineering, South Dakota State University, Brookings, SD, 57007, USA; [2]Sanford School of Medicine, University of South Dakota, Vermillion, SD, 57069, USA; [3]School of Design, South Dakota State University, Brookings, SD, 57007, USA; [4]College of Natural Sciences, South Dakota State University, Brookings, SD, 57007, USA.

Development of a Mandibuloglossolaryngectomy 3D Printed Model for Learning Upper Airway Anatomy.

INTRODUCTION. Learning anatomy of the upper airway can be challenging due to its obstructed views. Models demonstrating piecemeal anatomy of the maxilla, mandible, tongue, pharynx, and larynx make it challenging for students to learn spatial and functional relationships. Authors of this study formerly developed a mandibuloglossolaryngectomy (MGL) dissection protocol to produce a corresponding cadaveric prosection. The purpose of this study is to develop a complementary 3D printed model of the MGL. RESOURCES. The

continued on next page

MGL anatomy was configured from an open-source 3D digital anatomy model (Z-Anatomy). The epiglottis was printed using thermoplastic polyurethane filament for flexibility, while the rest of the model was printed in Blu resin (Siraya Tech) for durability. Impact resistance tests were conducted to identify and reinforce potential breaking points. Neodymium magnets were embedded in the model to hold the pieces together and allow for easy disarticulation, and an artist was commissioned to illustrate anatomical accuracy. DESCRIPTION. The model consists of eight composite subassemblies: 1) the maxilla, palatine bones, soft palate, and maxillary teeth; 2) the mandible, mandibular teeth, and lateral and medial pterygoid; 3 & 4) the temporalis and masseter; 5) the pharynx, esophagus, larynx, and trachea; 6) the tongue; 7) the epiglottis; and 8) the inferior pharyngeal constrictor. The palatine bones and lateral pterygoids were identified as weak points before their connections were reinforced. Target user feedback indicates the MGL model valuably complements the cadaveric prosection and would benefit teaching and learning. SIGNIFICANCE. The MGL model provides a more intuitive product for teaching and learning upper airway anatomy and its clinical applications (e.g., intubation). Translationally, this study exemplifies how collaborative skills and resources can be leveraged to develop customized teaching and learning resources for specific program and curricular needs.

Saturday, June 13 at 3:40 PM

* SCHWING, Gregory J.[1] and Patrick J. SCHWING[2]. [1]Wayne State University School of Medicine, Detroit, MI, 48201, USA; [2]LSU Health New Orleans School of Medicine, New Orleans, LA, 70112, USA.

Harnessing Algorithmic Disagreement for Automated Lumbosacral Transitional Vertebrae Detection.

INTRODUCTION. Using a reverse translational approach, we leveraged a surgical complication—wrong-level spine surgery due to lumbosacral transitional vertebrae (LSTV)—to drive research. LSTV affects up to 35% of patients, yet most AI segmenters force fixed L1–L5 labels onto anomalous anatomy. We propose an ensemble strategy treating spatial labeling disagreement between independent models (TotalSpineSeg [TSS] and SPINEPS) as a biomarker for LSTV. METHODS. We analyzed 282 lumbar MRIs from the RSNA 2024 Lumbar Spine challenge. TSS functions as a strict template, always assigning five lumbar labels (L1–L5), while SPINEPS acts as an anatomical sensor, labeling segments by local morphology and often detecting a transitional L6. To detect labeling failures, we developed a sequence-level alignment algorithm that maximizes 3D volumetric overlap between model outputs while "sliding" label sets across integer offsets (–2 to +2) to find the best fit. By anchoring consistent cranial levels (L1–L3), discordance is isolated to the lumbosacral junction. Disagreement regarding the lowest mobile segment (e.g., TSS labeling L5 vs. SPINEPS labeling transitional L6) triggers automated morphometry: calculating transverse process (TP) height, TP-sacral distance, and axial signal intensity to distinguish pseudo-articulation from fusion. RESULTS. Perfect alignment (offset=0) occurred in 232 studies (82.3%). True sequence shifts of +1 (lumbarization) occurred in 19 (6.7%) and –1 (sacralization) in 24 (8.5%). Of 30 cases where SPINEPS identified L6, 21 (67.7%) were confirmed shifts; 9 (29.0%) were rejected as false positives via cranial anchoring. Mean alignment Dice was 0.857 ± 0.028. Overall, LSTV was detected in 111 studies (39.2%). CONCLUSIONS. Treating algorithmic disagreement as signal rather than error creates a failsafe for LSTV detection. This framework enables systematic morphometric cataloging and provides surgeons a critical preoperative safeguard against wrong-level surgery.

continued on next page

Saturday, June 13 at 3:45 PM

* Rushforth, Brian P.[1,] Jehan Shawkat1, Shahlaa Al Wakeel[2], and Joanne L. Peterson[1]. [1]Arkansas College of Health Education, Fort Smith, AR, 72916, USA; [2]School of Engineering, St. Martin's University, Lacey, WA, 98503, USA.

Extraocular Eye Muscles: An Educational Teaching Aid.

INTRODUCTION. Many anatomy students struggle to comprehend the intricacies of extraocular eye muscles. Some struggle with understanding how the muscles attach to the eye, while others struggle with understanding the action of the muscles on the eyes. Current 3-D models can help with visualizing the attachments of the muscles, but without any moving parts it is difficult to translate muscle action in a model. Simulation models can help with understanding eye movement, but students still struggle with association of muscle attachment with those actions. METHODS. We developed a 3-D moveable eye model to assist students in comprehension of muscle action on the eye. To evaluate the model, first year medical students and masters students at Arkansas College of Health Education were recruited to participate in the study. After a pre-assessment, participants were assigned to a control or experimental group and provided 2.5 weeks to study the subject matter. Participants used either current library resources (control group) or library resources plus eye model (experimental group) while keeping a log of their study time and resources used. A post-assessment was then administered. SUMMARY. A total of 14 students completed all project requirements. The control group average on the assessment increased from 5.7 to 8.4 while the model group average increased from 5.6 to 9. While the experimental group showed a greater improvement in scores, it was not statistically significant. CONCLUSIONS. While not significant, the trend of increased scores when using the model is encouraging. Given the small size of the groups, further investigation with a larger population of participants may reveal more significance. This project was deemed to be exempt by the ACHE IRB with project number ACHE-2025-0052.

Saturday, June 13 at 3:50 PM

* CASSAGNOL, Tracy, Brianna ROSNER, Angela SLAYBE, and Brianna SANTIAGO. Department of Medical Education, Herbert Wertheim College of Medicine, Florida International University, Miami, FL 33199, USA.

The Role of 3D Printing and History in Neuroanatomy Medical Education: Phineas Gage Reimagined.

INTRODUCTION. 3D printing allows for the incorporation of visual learning to neuroanatomy. 3D printing allows for the replication of historical pathologies, such as the injury of Phineas Gage. We took advantage of 3D printing technology to replicate Gage's injury as a method to teach neuroanatomy and reflect on a historical case. METHODS. A workshop entitled "Phineas Gage Reimagined: An Anatomical and Historical Analysis" was prepared and executed by an anatomy educator at FIU Herbert Wertheim College of Medicine. Thirty-nine medical students attended the lunch session, sponsored by the Medical History and Neurosurgery Interest Groups. The workshop focused on the historical event of the injury of Gage using 3D printed models of his injury. Students were split into groups that each focused on a specific aspect of the neuroanatomy and pathology of Gage's injury including determining injury extent, hemorrhagic risk, infection, and localization of functional deficits. Each group was given a 3D printed model of Gage's brain or skull, along with excerpts from Dr. Harlow MD, Gage's physician. The workshop concluded with a group discussion and feedback survey. SUMMARY. The feedback survey yielded a total of 31 responses for a total of five Likert-scale style items. Of these measures, interest and engagement, anatomical understanding, and desire for more historical and 3D printed model activities, all yielded positive feedback, with all respondents rating these measures 5/5 (Mean = 5.00). Overall learning of brain anatomy was

continued on next page

also perceived to be of strong learning benefit with a mean score of 4.90. CONCLUSIONS. To conclude, the use of 3D printed models combined with Gage's historical injury provides the potential to be of high learning benefit and well received by students. 3D printed models in neuroanatomy teaching may have the potential to engage students and provide an in-depth understanding while providing the opportunity to replicate historical pathologies.

Saturday, June 13 at 3:55 PM

* FELL, Lauren V.[1], Madison B. COWDREY[1], Michael J. BOUCHOUKIAN[2], Reut REINA[3], Robert W. RICE[4], and Jailenne I. QUIÑONES-RODRÍGUEZ[4]. [1]College of Osteopathic Medicine, Sam Houston State University, Conroe, TX, 77304, USA; [2]Department of Library Science and Technology, Sam Houston State University, Conroe, TX, 77304, USA; [3]Medical, Stratasys LTD, Rehovot, 7670401, Israel; [4]Department of Clinical Anatomy, College of Osteopathic Medicine, Sam Houston State University, Conroe, TX, 77304, USA.

Human Neurulation in Three Dimensions: Development of 3D-Printed Models for Anatomy Education.

INTRODUCTION. Human neurulation represents a critical period in early central nervous system development; however, its complex three-dimensional morphogenesis and rapid temporal progression pose instructional challenges in traditional two-dimensional teaching environments. Effective instruction requires visualization of coordinated spatial transformations, including neural plate formation, neural fold elevation, neural tube closure, and neural crest cell migration. This project describes the development of a staged, tactile neurulation model set designed to enhance spatial comprehension and support active learning in undergraduate medical education. RESOURCES. Model development was informed by established references in human embryology and guided by principles of computer-aided design. Additive manufacturing techniques were used to generate a series of 3D-printed models representing sequential developmental milestones from days 15-28 of embryogenesis. DESCRIPTION. Seven staged models were produced depicting: trilaminar germ disc formation; notochord induction and neural plate development; neural groove and fold formation; initiation of neural tube closure; neural crest cell migration; progressive neural tube closure with somite formation; and closed neural tube with early brain vesicle development. Sequential shading strategies were incorporated to visually reinforce tissue continuity across stages. SIGNIFICANCE. This staged model sequence transforms neurulation from a static representation into a tactile, spatially coherent progression, enabling learners to compare developmental transitions and integrate structure with clinical implications such as neural tube defects. The models are designed for small-group, case-based learning and longitudinal curricular integration.

Saturday, June 13 at 4:00 PM

* URIBE, Manuel[1], Andrea MARTÍNEZ[1], Lidia HERNÁNDEZ[2], [1]Department of Anatomy, Cuauhtemoc University, San Luis Potosí, 78290, México; [2]University of the Valley of México, San Luis Potosí, 78220, México.

Low-Cost Simulator for Studying the Anatomy of the Cerebral Ventricles Using Flexible Endoscopy.

INTRODUCTION. Currently, there is limited information on 3D models that allow observation of the internal configuration of the cerebral ventricles, the performance of a ventriculostomy, and the obtaining of biopsies. On the other hand, various models exist, including those manufactured with 3D printers, ventricular injection with silicone, and models based on bovine brains. However, these models do not represent primary anatomical structures such as the interventricular foramen, the caudate nucleus, the thalamostriate veins, the superior

continued on next page

choroidal veins, the anterior sepal veins, the mesencephalic aqueduct, the mammillary bodies, the premammillary membrane, and the suprachiasmatic recess, all of which are part of the third ventricle. RESOURCES. This project was carried out in the Department of Anatomy at Cuauhtémoc University, San Luis Potosí Campus, Mexico. The 3D skulls were printed with polyvinyl chloride filament. The 3D anatomy of the cerebral ventricles was created using Rhoton's book, Cranial Anatomy and Surgical Approaches, and each structure was manually detailed using Casbel® moldable silicone, Politec® acrylic paint in various colors, a Mindray® flexible endoscope with a laparoscopy tower, and a Dremel 2000® tool to create the trephine in the right precoronal region. DESCRIPTION. To design and present a low-cost 3D anatomical model for studying the anatomy of the cerebral ventricles, performing a ventriculostomy, and obtaining biopsies using flexible endoscopy. SIGNIFICANCE. Studying the anatomy of the cerebral ventricles using flexible endoscopy requires manual dexterity and a thorough knowledge of the adjacent anatomical structures. Similarly, this model could become a valuable resource for illustrating the relationship between the ventricular system and the subarachnoid space at the base of the skull in university education.



continued on next page

Abstracts – Poster Presentations

***Tentatively Accepted for Electronic Posting on *Clinical Anatomy* site**
(Listed Chronologically by Poster Number)

POSTER SESSION 1 – FRIDAY, JUNE 12 FROM 3:45 PM - 5:00 PM

1.
*ZUROB, Ameer, Maya THOMPSON, Isra ELDOSOUGI, Alex AYOUB, Johnny HAN, Andrew OWENS, and Manuel CEVALLOS. School of Medicine, Creighton University, Phoenix, AZ, 85012, USA.

Asymmetrical Bilateral Ureteral Duplication: A Rare Anatomical Variant with Clinical Implications.

INTRODUCTION. Congenital anomalies of the kidney and urinary tract (CAKUT) are rare anatomical variations that occur in 0.2–1% of live births and account for 20–30% of prenatally detected anomalies. Ureteral duplication has an incidence of 0.7–5%, with incomplete duplication occurring approximately three times more frequently than complete duplication. RESOURCES. During the anatomy course at Creighton University-Phoenix, 30 donors preserved in 3–4% formaldehyde were dissected. An 84-year-old female donor presented with a bilateral ureteral duplication. DESCRIPTION. Anatomical dissection revealed an incomplete duplication in the left kidney (L=9.4 cm X W=4.3 cm), with two ureters originating from the renal pelvis and fusing before entering the bladder, consistent with a bifid ureter, where each ureter had an external diameter of 0.7 cm and 0.4 cm, and a common ureter of 0.6 cm The right kidney (L=8.7 cm X W=4.2 cm) demonstrated complete duplication, with two distinct ureters arising separately from the renal pelvis and draining to independent ureteral orifices in the bladder (double ureter); each ureter had an external diameter of 0.2 cm. Clinical history was unavailable to assess functional implications. SIGNIFICANCE. Bilateral ureteral duplications are exceptionally rare, occurring approximately six times less frequently than unilateral duplications, with an estimated prevalence of 0.16–0.32%. CAKUT contributes to 30–50% of chronic kidney disease (CKD) cases. Recognition of infrequent anatomical variants is important, as these anomalies may predispose affected individuals to complications including vesicoureteral reflux, hydronephrosis, ureteral lithiasis, and recurrent urinary tract infections. Awareness of such variations underscores the importance of anatomical knowledge in clinical evaluation, diagnosis, and long-term management of renal health.

2.
*HARTZ, Olivia M., Paola ARIZA-STORCH, Megan C. BALLE, and Sumathilatha SAKTHI-VELAVAN. Department of Anatomy and Pathology, Marian University Wood College of Osteopathic Medicine, Indianapolis, IN, 46222, USA.

Intraluminal Fibrous Cord Associated with Bicarotid Trunk and Dissection of the Aorta.

INTRODUCTION. Intraluminal cord of the aortic arch is a rare variation and has been reported as an incidental clinical finding. While variant branching of the aortic arch is common, its association with an intraluminal cord has never been reported. The purpose of this study is to explore the intraluminal cord, found concurrently with a variant aortic arch and aortic dissection; a combination not previously described in the literature. RESOURCES. During routine dissection, a cord was found within the aortic arch of a 90-year-old female donor. The external and internal features of the aorta were examined and photographed. A biopsy and histopathological examination of the cord and aorta were performed. DESCRIPTION. A type II bicarotid trunk was found on the aorta, in which the brachiocephalic trunk and left common carotid artery arose from a shared trunk, and the left subclavian artery originated independently. A fibrous intraluminal cord was found just distal to the origin of the shared trunk. Histopathology showed it as an extension of the tunica intima and part of the tunica media. The aorta had an intimal tear and a calcified and dilated wall near the origin of the left subclavian artery. A dissection of the aortic arch and descending aorta distal to the tear was confirmed by histopathology. SIGNIFICANCE. An

continued on next page

intraluminal cord in the region of the aorta derived from the left fourth aortic arch, coupled with a bicarotid trunk, suggests a possible defect in shared neural crest–dependent arch remodeling. While aortic pathologies are most consistent with the hemodynamic consequences of the bicarotid trunk, the fibrous cord may have exacerbated regional hemodynamic stress. The fibrous cord also poses a diagnostic challenge by mimicking an intimal flap on imaging. Accurate recognition of the intraluminal cord and the bicarotid trunk is clinically significant to avoid misdiagnosis and to appropriately contextualize associated aortic remodeling and pathology.

3.

*DURBIN, Willson K[1], Chase NOWACZYK[1], Tommy NOONAN[1], Ivan JUAREZ[1], and John HUBBARD[1]. [1]Department of Neuroscience and Experimental Therapeutics, Texas A&M University Health Science Center, College Station, TX, 77807, USA.

Rotator Cuff Quality and Repair in a Central Texas Cadaveric Population.

INTRODUCTION. Rotator cuff degeneration, identified through fatty infiltration and muscle atrophy, is a prevalent condition and major contributor to shoulder dysfunction in the elderly. While clinical imaging studies have extensively described the degenerative changes, cadaveric investigations allow for a unique opportunity to directly analyze the gross pathological changes associated with rotator cuff degeneration. Furthermore, we are able to examine the prevalence of rotator cuff repair in a cadaver population. METHODS. Using a deltoid reflecting technique, we examined the humeral head and muscle bellies of the rotator cuff muscles of 30 donor cadaver specimens. We looked for evidence of rotator cuff repair and graded each muscle belly for atrophy (0-3 scale) and fatty infiltration (0-4 scale). Pearson correlation coefficients assessed linear relationships between age and average scores. Point-biserial correlations evaluated gender differences. SUMMARY. Of the 60 shoulders dissected 3 had evidence of rotator cuff repair. Weak positive correlations were found between age and average fatty infiltration and atrophy. Gender showed weak negative correlation with fatty infiltration but moderate positive with atrophy ($r=0.57$, $p=0.004$; females higher: 1.55 vs males 0.88). Findings suggest gender-specific atrophy patterns in elderly cadavers, warranting larger studies.CONCLUSIONS. Prior rotator cuff repair was identified in 5% of dissected shoulders. Age showed weak associations with fatty infiltration and atrophy, while female donors demonstrated significantly greater muscle atrophy alongside lower fatty infiltration. The findings suggest statistically significant ($p<0.05$) sex-specific patterns of rotator cuff muscle degeneration and indicate the need for large scale studies to better define prevalence and clinical relevance.

4.

*KHANIJOU, Srosha, Yasamin F. SABERI, Anatrita A. LIBBEY, Haider HILAL, Kristna THOMPSON, and Tarek ALMABROUK. School of Medicine, St. George's University, St. George's, Grenada.

Inter-Examiner Reliability of Liver Ultrasound: Most Reliable Landmark for Novice Training.

INTRODUCTION. Ultrasound is widely used to assess liver size, but measurements are operator-dependent and may vary according to the anatomical landmark selected. This study aimed to evaluate inter-examiner reliability in ultrasound-based liver measurements and to identify the most reliable anatomical landmark for novice training. METHODS. Ultrasound liver measurements were performed in 33 participants by two examiners with different levels of experience: a novice (a first-year medical student) and an experienced ultrasound technician (a consultant). Two planes, the midclavicular (longitudinal) and midaxillary (transverse) lines, were used with two anatomical landmarks (hilum and vessels) along the anteroposterior axis. Examiners recorded liver length (cm) and acquisition time (s) independently without access to each other's recordings. Inter-observer agreement was assessed using intraclass correlation coefficients (ICC), and differences were analysed using paired t-tests. SUMMARY. Transverse liver measurements using the vessel as a landmark demonstrated moderate inter-examiner

continued on next page

reliability (ICC = 0.595), compared to alternative landmarks. Although novice examiners overestimated liver size compared to experienced examiners (p = 0.006) and required a statistically significant longer acquisition time, there may still be a suggested acceptable agreement in using the transverse plane with the vessel as a landmark to teach novices. Furthermore, it was noted that the experienced examiner's measured times decreased across sequential landmarks within the same patient, whereas the novice's time remained relatively constant, potentially reflecting increased spatial familiarity associated with experience. CONCLUSIONS. Ultrasound-based liver measurements can be performed reliably by novices following proper instruction. Further studies with larger cohorts and comparisons with CT measurements are warranted to improve measurement concordance.

5.
*ARMFIELD, Honora, Nicholas JURIGA, Chika UWANDU, Jacob ARENZ, Faraaz QURAISHI, and Malli BARREMKALA. Department of Anatomy, Oakland University William Beaumont School of Medicine, Rochester, MI, 48309, USA.

Cadaveric Observation of a Chiari Network: Incidence and Morphologic Characterization.

INTRODUCTION. Venous blood typically enters the right atrium via the superior vena cava and through the Eustachian and Thebesian valves, from the inferior vena cava and coronary sinus, respectively. Rare embryonic remnants of the sinus venosus septum may persist over these valve openings as a fenestrated, web-like structure known as a Chiari network. This report describes the identification of a large, right atrial structure consistent with a Chiari network and documents its low frequency among human donors. RESOURCES. Dissection of the thoracic cavity and heart was performed as part of a medical student gross anatomy lab course. Anatomical variation within the right atrium was documented photographically. The incidence of this finding was assessed across a total of 22 donor hearts. DESCRIPTION. A web-like filamentous structure with multiple fenestrations was identified within the right atrium. The structure measured 5.5 cm in length and 0.25 cm in width, exceeding the commonly reported average length of approximately 3 cm. The morphology was consistent with a Chiari network, representing incomplete regression of an embryonic remnant. This variation was observed in one of 22 donors (4.5%), a frequency comparable to the reported population prevalence of approximately 2%. SIGNIFICANCE. Chiari networks are uncommon anatomical variations that may complicate interventional cardiac procedures, including right atrial catheter placement, central venous access, and other intracardiac procedures. Although typically benign, Chiari networks have been associated with patent foramen ovale and atrial septal aneurysm. While many individuals remain asymptomatic, the presence of a Chiari network may increase the risk of procedural complications and, in rare cases, contribute to life-threatening cardiac events.

6.
*BENTLEY, Travis S., Wenwen GUO, Yun TAN, and Daniel T. DALY. Center for Anatomical Science and Education (CASE), Department of Surgery, Saint Louis University School of Medicine, Saint Louis, MO, 63104, USA.

Bilateral Absence of Flexor Carpi Radialis: A Novel Finding of a Rare Anatomical Anomaly.

INTRODUCTION. The flexor carpi radialis (FCR) muscle flexes the hand and acts with the radial extensors in radial deviation of the hand. Absence of this muscle is rare in the general population and has only been reported as a unilateral anomaly. This case presents the bilateral absence of the FCR muscle along with a left-sided unilateral missing 5th tendon slip of the flexor digitorum superficialis (FDS) and palmaris longus (PL). RESOURCES. This case was identified in an 85-year-old female cadaver, which was obtained through Saint Louis University School of Medicine (SLUSOM) Gift Body Program in the Center for Anatomical Science and Education (CASE), with informed consent from the donors. Dissection was carried out as a part of SLUSOM curriculum. DESCRIPTION. This presents the bilateral missing FCR muscle and tendon as a novel case that has not previously been reported

continued on next page

in the literature. SIGNIFICANCE. The FCR tendon is commonly used as a landmark, autograft, and in tendon transfers in various hand and forearm surgical procedures. The absence of the FCR muscle may also have an etiology that is similar to that of the PL muscle, which is much more commonly absent in the general population. Understanding the cause and possibility of the absence of FCR has surgical planning and procedural implications, and surgeons should be aware of this possibility when intending to use this muscle in an operation.

7.

*THOMAS, Caleb W., Emily A. SHORES, Karihn J. HANDY, Gabe SCHILLER, and Alla BARRY. Department of Biology and Environmental Health, Missouri Southern State University, Joplin, MO, 64801, USA.

Right-Sided Aortic Arch, Aberrant Left Subclavian Artery and Recurrent Laryngeal Nerve Variation.

INTRODUCTION. Anatomical variations of the aortic arch are clinically significant because they affect thoracic surgery, vascular interventions, airway management, and radiologic interpretation. RESOURCES. During routine cadaveric dissection of a 90-year-old female in an undergraduate gross anatomy laboratory, we identified a right-sided aortic arch (RSAA) with a right-sided descending thoracic aorta (RSDTA), associated with an aberrant left subclavian artery (ALSA) and an altered recurrent laryngeal nerve (RLN) branching pattern. DESCRIPTION. The aortic arch coursed to the right of the trachea, continuing as an RSDTA. The left and right common carotid arteries and the right subclavian artery branched directly from the RSAA. The ALSA originated from the descending aorta, travelling posterior to the esophagus toward the left upper limb. The ligamentum arteriosum was observed to the left of the esophagus, connecting the ALSA to the pulmonary trunk and contributing to the formation of a vascular ring. While the right RLN was observed looping beneath the right-sided aortic arch, no distinct RLN was observed ascending along the left side of the trachea. These findings reflect embryologic persistence of the right fourth aortic arch, with regression of the corresponding left sided segments, resulting in a modified pattern of RLN looping. SIGNIFICANCE. Awareness of right-sided aortic arch variants and their impact on RLN anatomy is essential in preventing iatrogenic RLN injury during thyroidectomy, esophageal surgery, and mediastinal procedures. Moreover, discovering anatomical variations through cadaveric dissection underscores the irreplaceable role of hands-on gross anatomy in pre-medical and medical education, which reinforces developmental principles and cultivates the ability to anticipate deviations from textbook anatomy that may alter surgical landmarks and radiologic interpretation.

8.

*ASPAAS, Jacob D.[1], Connor J. GROEN[1], Timothy ROBINSON[2], Joseph X. ANDERS[1], and Ethan L. SNOW[1]. [1]College of Natural Sciences, South Dakota State University, Brookings, SD, 57007, USA; [2]College of Medicine, University of Nebraska Medical Center, Omaha, NE, 68198, USA.

Histological Analysis of the Chiari Network with Corresponding Clinical Implications.

INTRODUCTION. Chiari network (CN) is a net-like embryological remnant that infrequently persists at the junction of the inferior vena cava (IVC) and right atrium (RA) after incomplete involution of the right valve of the sinus venosus. While CNs are well documented, histological analyses are missing from the literature. The purpose of this study is to report histological analysis of a CN with corresponding clinical discussion. RESOURCES. A large CN was discovered during routine human cadaver dissection, and the structure was photographed in situ with scale. The apico-basal (AB) and septal-lateral (SL) diameters of the RA were measured in septuplicate using a digital caliper. The CN was then freed from its attachments to the RA, processed for histology, sectioned (5 µm), stained (H&E, McLetchie trichrome), and scanned for examination via digital light microscopy. DESCRIPTION. The CN presented as a 3.5 cm x 3.0 cm x 0.2 mm reticular structure spanning from the Eustachian valve to the lateral wall of the RA and the crista terminalis. Hematological elements were adhered to its endothelial lining,

continued on next page

and myocardial tissue was histologically evident among the collagenous matrix. The mean AB and SL diameters of the RA were 6.25 cm and 5.99 cm respectively. The pectinate muscles were remarkably cavernous, and history of a trans-catheter aortic valve replacement (TAVR) was evident. The body donor also self-reported a history of atrial fibrillation, hypertension, and chronic kidney disease. SIGNIFICANCE. CNs are relatively rare findings (~2% prevalence). While they are most often benign and discovered incidentally via echocardiography, there is correlational evidence between CNs and cardiac arrhythmias, infective endocarditis, thromboembolism, patent foramen ovale (PFO), and atrial septal defects. As CNs have not been well-defined histologically, the histological analyses and imaging reported in this study may provide important insight to the etiology of CN comorbidities.

9.

*JIN, Eric[1], Majid ALIMOHAMMADI[2], and Majid DOROUDI[2]. [1]School of Kinesiology, University of British Columbia, Vancouver, British Columbia, V6T 1Z4, Canada; [2]Department of Cellular and Physiological Sciences, Faculty of Medicine, University of British Columbia, Vancouver, British Columbia, V6T 1Z4, Canada.

Condylar Morphology and Disc Degeneration in Cadavers with Temporomandibular Joint Osteoarthritis.

INTRODUCTION. The temporomandibular joint (TMJ) is a bilateral synovial joint with an articular disc between the mandibular condyle and the mandibular fossa. It is a site for osteoarthritis (OA), whose etiology remains inconclusive and likely multifactorial. A thorough understanding of the morphological changes of the TMJ can provide insight into osteoarthritis development. The purpose of this study is to explore condylar morphology and its association with disc degeneration and TMJ OA patterns. METHODS. 42 TMJs from 38 embalmed adult cadavers (ages 55-105) were dissected. Condylar OA was graded using a validated five-point disease severity scale based on surface degeneration. Condylar morphology was classified as convex, flat, round, or angled, while articular discs were assessed as normal, slightly thin, thin, or perforated. Patterns of degeneration were qualitatively compared across OA severity grades. SUMMARY. Osteoarthritic signs were identified in 98% of specimens, with the mandibular fossa displaying greater degeneration than the condyle. Condylar morphology was most frequently convex or flat, while round and angled morphologies were less common but disproportionately represented in TMJs with severe OA. Perforations of the articular disc consistently coincided with the most irregular or protruded regions of the underlying condyle. CONCLUSIONS. Angular and rounded condylar morphologies, along with disc perforation were associated with more severe OA. This underscores the importance of joint surface-disc interaction in TMJ OA. Findings suggest morphological assessment of the condyle and disc degeneration can enhance TMJ OA diagnosis. Clinically, recognizing these structural relationships may support earlier identification of TMJ OA and inform joint degeneration mitigation strategies.

10.

*JOHNSON, Caden T., Robyn E. DAYTON, Darci M. FINK, and Ethan L. SNOW. College of Natural Sciences, South Dakota State University, Brookings, SD, 57007, USA.

Translational Analysis of Human vs. Mouse Lymphatic and Lymphovenous Valves.

INTRODUCTION. Despite its critical fluid and immune regulatory functions, the lymphatic system remains understudied at the gross, cellular, and molecular levels. Murine models allow for in vivo genetic manipulation and studies of lymphatic development, signaling, and disease mechanisms. Human cadavers allow educators and researchers to grossly and histologically examine lymphatic structures and disease outcomes. Despite their complementarity, few studies have involved both models. Here we aimed to comparatively investigate human and mouse lymphatic valves to generate clinically translational insights. METHODS. The thoracic duct was dissected in situ in two anatomically embalmed human cadavers. Grossly evident lymphovenous valves were

continued on next page

photographed, excised, and processed for histology (H&E, McLetchie trichrome). Comparable valves in transgenic mice expressing GFP in lymphatic endothelial cells (PROX1-GFP) were examined via in situ GFP fluorescence. Cre-lox-mediated lymphatic-specific deletion of IFT74 tested the hypothesis that primary cilia govern valve formation. Various microscopy methods, including immunofluorescence, were used to characterize mouse valve architecture. SUMMARY. Cadaveric dissections revealed multiple bileaflet valves flanking the thoracic duct at the lymphovenous angle and others intermittently along the thoracic duct. Imaging of murine valves illustrated microscopic structural elements essential for valve integrity and function, consistent with histological findings of cadaveric valves. Genetic knock-out of IFT74 caused loss of mature lymphatic valves. CONCLUSIONS. This study provides translational insights into the structural anatomy of human vs. mouse lymphatic valves that may guide treatment development for diseases such as lymphedema. This work reinforces the utility of mouse models for genetic studies of lymphatic valve formation, while highlighting considerations for translation of mouse-based findings to the large, upright human anatomy.

11.

*ANDERS, Isabela C.[1], Hagan R. WESTERMEYER1, Alexis E. HOPP1, Mandy R. ORTH[1], Susan P. BARE[2], Mohammed P. AKHTER[2], and Ethan L. SNOW[1]. [1]College of Natural Sciences, South Dakota State University, Brookings, SD, 57007, USA; [2]Osteoporosis Research Center, Creighton University, Omaha, NE, 68122, USA.

Dental Implications from Extracting Permanent Teeth to Maintain Deciduous Teeth: A Case Analysis.

INTRODUCTION. Permanent teeth naturally initiate physiological exfoliation of deciduous teeth to make way for eruption and locational maturation. Permanent teeth occasionally become impacted during this process and require surgical extraction. In these cases, patients may opt to maintain the corresponding deciduous teeth rather than plan for prosthetics; however, long-term clinical implications and tissue analyses from such cases are lacking in the literature. This study therefore aims to provide comprehensive pre- and post-operative analyses on a case that involves death of the maintained deciduous tooth after 47 years. RESOURCES. A dental patient provided informed consent for their records and tissues to be included in this study. The patient's dental history, recent panoramic dental x-rays, and pre-surgical three-dimensional computed tomography (3DCT) imaging of the dying deciduous tooth were clinically analyzed. Gross anatomical and x-ray micro-computed tomography (μCT) analyses were performed on the extracted deciduous tooth. DESCRIPTION. At 13 years old, the patient had an impacted right permanent maxillary canine tooth surgically extracted to maintain the associated healthy deciduous tooth. The deciduous tooth then died 34 years later, necessitating its extraction. Digital implant overlay in the 3DCT highlighted iatrogenic maxillary bone resorption where the permanent tooth was previously extracted, justifying the need for a cadaveric bone graft. Gross and μCT analyses of the extracted deciduous tooth indicated dental degradation on the occlusal surface, near the gumline, and within the pulp cavity. SIGNIFICANCE. While preserving deciduous teeth may offer conservative treatment for maintaining natural dental appearance and masticatory function when primary teeth extractions are necessary, it may not be a viable long-term solution. This research suggests additional study about the long-term physiological impacts on preserved deciduous teeth is warranted.

continued on next page

12.

*WEBER, Caylee A.[1], Shayla S. RUNDBERG[1], Maureen E. HURLEY[2], and Ethan L. SNOW[1]. [1]College of Natural Sciences, South Dakota State University, Brookings, SD, 57007, USA; [2]Sanford School of Medicine, University of South Dakota, Sioux Falls, SD, 57105, USA.

Anatomical and Histopathological Analysis of Paraovarian Cysts.

INTRODUCTION. Paraovarian cysts (POCs) are fluid-filled sacs that can develop within the broad ligament from vestiges of the paramesonephric (Müllerian) or mesonephric (Wolffian) ducts. POCs are often discovered incidentally, and their symptoms are frequently mistaken for menstruation or other gynecologic or gastrointestinal conditions. The purpose of this study is to perform an anatomical and histopathological analysis of POCs and provide a corresponding literature-based clinical discussion. RESOURCES. During a routine academic dissection of a post-menopausal human cadaver, numerous cyst-like adnexal masses were identified adjacent to each ovary. The masses were carefully cleaned, photographed in situ with scale, and grossly sectioned perpendicularly and parallel to the corresponding uterine (fallopian) tubes. A ~3 mm3 sample from each section (n = 4) was collected, processed for histology (paraffin -embedded), sectioned (5 µm), stained (H&E and McLetchie trichrome), and scanned for examination via digital light microscopy. DESCRIPTION. Histopathology revealed mass envelopment by the broad ligament, a well-defined flattened epithelium, and localized proximity without connection to the ovaries, thus confirming the masses were POCs. As apparent from the perpendicular cross-sections, the POCs exhibited serous morphology and compressed the uterine tubes. The largest POC on the left measured 7.7 mm x 3.4 mm, and the largest POC on the right measured 9.3 mm x 6.9 mm. Numerous smaller POCs were contiguous to each large POC. SIGNIFICANCE. Though they are often benign, POCs can instigate ovarian torsion, infertility, and other serious issues. Surgical treatment may become necessary if severe sequelae persist. This study supplements existing anatomical and histopathological resources with complementary analyses and insights that may valuably inform clinical anatomists and physicians about the presentation of POCs when analyzing, diagnosing, or treating related cases.

13.

*JAROLEM, Maya B. and Patrick W. FRANK. Department of Neurobiology and Anatomy, Drexel University College of Medicine, Philadelphia, PA, 19104, USA.

Pisi-Palmaris Muscle: Cadaveric Study and an Anatomical Look at Its Origin and Clinical Significance.

INTRODUCTION. Anomalous muscles of the hand occur in approximately 22–35% of individuals and may have clinical implications, particularly when located near neurovascular structures. During a routine cadaveric dissection of a 72-year-old male donor, a novel hypothenar variant muscle, the pisi-palmaris, was identified unilaterally on the left hand and characterized. RESOURCES. A detailed cadaveric dissection was performed to expose the muscle's origin, insertion, and anatomical relationships; a targeted literature review was conducted to contextualize the finding within existing anatomical knowledge. DESCRIPTION. The pisi-palmaris muscle was found to originate from the pisiform bone, deep to the tendon of the flexor carpi ulnaris and the volar carpal ligament; it inserted onto the transverse carpal ligament and merged with fibers of the abductor and flexor digiti minimi muscles. Notably, the muscle lay superficially to the deep part of the ulnar neurovascular bundle as they pass through Guyon's canal. SIGNIFICANCE. Due to its close anatomical relationship to the ulnar nerve and vascular structures within Guyon's canal, the presence of a pisi-palmaris muscle may increase the likelihood for ulnar nerve entrapment if hypertrophied. If unrecognized, this variant may increase the risk of diagnostic error and iatrogenic injury during nonoperative treatments or surgical decompression. Awareness of muscular variants is critical to minimizing procedural complications and improving clinical outcomes.

continued on next page

14.
*BOYD, McKenzie R.[1], Katie R. HAWTHORNE[1], Dennis C. WOOTEN2, Sefik T. GOKASLAN[2], and Jailenne I. QUIÑONES-RODRÍGUEZ[2]. [1]College of Osteopathic Medicine, Sam Houston State University, Conroe, TX, 77304, USA; [2]Department of Clinical Anatomy, College of Osteopathic Medicine, Sam Houston State University, Conroe, TX, 77304, USA.

Adult Morgagni Hernia with Concurrent Abdominal Wall and Inguinal Hernias: A Cadaveric Case Report.

INTRODUCTION. Congenital diaphragmatic hernias in adults are uncommon, with Morgagni hernias representing a rare anterior defect of the diaphragm. Existing reports primarily emphasize clinical presentation and surgical management, often without detailed anatomical characterization. Additionally, concurrent hernias in affected individuals are infrequently documented. This report describes the anatomical findings of an adult Morgagni hernia identified during routine cadaveric dissection, with coexisting abdominal wall and inguinal defects. RESOURCES. A formal thoracoabdominal dissection was performed on a 64-year-old female donor during routine gross anatomy laboratory instruction. Systematic exploration of the diaphragm, abdominal wall, and associated viscera was conducted. Morphometric measurements of each defect were obtained using digital calipers, and photographic documentation was performed to characterize defect size, anatomical location, and herniated contents. DESCRIPTION. Dissection revealed a 7.5 cm x 7.0 cm anterior diaphragmatic defect consistent with a Morgagni hernia at the sternocostal triangle. Approximately 6.5 cm of gastric tissue was observed herniating into the thoracic cavity. Two midline umbilical hernias were identified, along with a right inguinal hernia. Additional incidental findings included bilateral chronic pyelonephritis with hydronephrosis and nephrolithiasis, atrophy of the pancreas, and hepatic bile stasis. SIGNIFICANCE. This case provides detailed anatomical and morphometric documentation of a rare adult Morgagni hernia with multiple concurrent abdominal wall hernias. The coexistence of diaphragmatic and abdominal wall defects is well documented in anatomical literature and underscores the importance of comprehensive regional dissection. Such findings enhance anatomical education by strengthening clinical-anatomical correlations relevant to general surgery, thoracic surgery, and hernia repair.

15.
*ANDERSON, Allison B. and Chernet B. TESSEMA. University of North Dakota School of Medicine and Health Sciences, Grand Forks, ND, 58202, USA.

Complex Unilateral Brachial Plexus Variation and a Novel Common Trunk for Three Pectoral Nerves.

INTRODUCTION. The brachial plexus (BP) innervates the skin and the musculature of the upper extremity. The classic description includes five roots, three trunks, six divisions, three cords, and five terminal branches. The medial and lateral pectoral nerves (PNs) originate from the medial and lateral cords, respectively, and are often connected by the ansa pectoralis. While the classic description represents the most common configuration of the BP, many variations exist. There is a paucity of research on PN variations involving a common pectoral trunk and few reports describing four-trunk BP configurations. RESOURCES. The full-body dissection of an 87-year-old male donor with consent for education, research, and publication, was performed to identify anatomical variations. DESCRIPTION. During dissection of the right axilla and root of the neck, we identified a four-trunk BP, with the four trunks derived from C5, C6, C6 & C7, and C8 & T1, respectively. Each trunk gave a pair of divisions, which formed four cords (lateral, anterior, medial, and posterior). A common pectoral trunk arose from the lateral and anterior cords and divided into superior, middle, and inferior PNs. The superior and middle PNs entered the pectoralis major, while the inferior PN terminated in both the pectoralis minor and major muscles. SIGNIFICANCE. We identified a BP with four trunks, four paired divisions, and four cords with an unusual PN variation in a cadaveric dissection. While many studies describe variations in trunk contributions, most describe additional

continued on next page

contributions from C4 or T2, rather than variations within the C5-T1 region itself. A common pectoral trunk with three distinct PNs is a novel finding. Describing BP variations is crucial to minimize unintended consequences, including surgical complications, incomplete nerve blocks, and misdiagnosis of traumatic injuries, and to explore potential donor nerve candidates for neurotization procedures.

16.

*HAWTHORNE, Katie R.[1], McKenzie R. BOYD[1], Jessica K. NGUYEN[1], Dennis C. WOOTEN[2], Sefik T. GOKASLAN[2], and Jailenne I. QUIÑONES-RODRÍGUEZ[2] .[1]College of Osteopathic Medicine, Sam Houston State University, Conroe, TX, 77304, USA; [2]Department of Clinical Anatomy, College of Osteopathic Medicine, Sam Houston State University, Conroe, TX, 77304.

Adult Diaphragmatic Hernias: Anatomical Patterns and Demographic Variability in Modern Literature.

INTRODUCTION. Adult diaphragmatic hernias are uncommon pathologic entities resulting from congenital or acquired defects of diaphragmatic integrity. While congenital diaphragmatic hernias are extensively studied in neonates, adult presentations are comparatively underreported and often described primarily in clinical or surgical contexts. Detailed characterization of anatomical presentation and demographic distribution in adult populations remains limited. RESOURCES. A structured literature synthesis was conducted across three databases for studies published between 2000 and 2025. Inclusion criteria required documentation of demographic variables and anatomical or pathological characterization of diaphragmatic defects in adult patients. Studies lacking anatomical detail or demographic data were excluded. A total of 44 studies met eligibility criteria for analysis. DESCRIPTION. Posterolateral defects were more frequently described than anterior defects in adult congenital cases, whereas acquired hernias were commonly associated with traumatic or iatrogenic etiologies. Variability was noted in defect size, laterality, and herniated contents, most commonly involving stomach, colon, or small intestine. Demographic reporting demonstrated differences across age groups and sex; however, ethnicity was inconsistently documented. Anatomical characterization varied considerably across studies, with limited standardized morphometric reporting. SIGNIFICANCE. This synthesis highlights substantial variability in the anatomical presentation of adult diaphragmatic hernias and reveals inconsistent demographic documentation within the literature. The predominance of neonatal research contrasts with the limited anatomical characterization of adult cases. Standardized reporting of defect morphology and inclusion of demographic sampling may improve understanding of patterns in adult diaphragmatic hernias and support anatomical education, imaging interpretation, and surgical planning.

17.

*HEIDERSCHEIDT, Trey W., Gavin T. SANNES, Walker W. VANDEVELDE, Tyler J. GROEN, and Ethan L. SNOW. College of Natural Sciences, South Dakota State University, Brookings, SD, 57007, USA.

Angular Biomechanics and Clinical Implications of a Biceps Brachii Accessory Head.

INTRODUCTION. The biceps brachii long head (BBLH) originates from the supraglenoid tubercle, and the short head (BBSH) originates from the coracoid process. Both biarticulate heads insert on the radial tuberosity to supinate and flex the forearm. A uniarticulate accessory head (BBAH) infrequently develops (9.6% prevalence) and anchors the common biceps muscle to the humeral shaft. Reports of BBAHs are mostly limited to gross analyses. The objective of this study is to report the angular biomechanics of BBAH with a literature-based clinical discussion. RESOURCES. Bilateral BBAHs were discovered during routine dissection of an adult human cadaver. The muscles were photographed in situ and ex situ with scale. Observable parameters for each BBLH,

continued on next page

BBSH, and BBAH were grossly measured, and mean fixed sarcomere lengths were examined via digital light microscopy to calculate the normalized maximal isometric forces (Fmax) for each head. Changes in BBLH, BBSH, and BBAH torque at every 15° of forearm flexion were calculated from digital modeling. Intermuscular architectural comparability indices (δ2,1) were also calculated to reveal structural similarities between each head. DESCRIPTION. While the left and right BBAH produced considerably different Fmax (20.78 N and 10.05 N, respectively), they were architecturally indifferent (0.30 < δ2,1 < 0.80). The BBAHs originated on the humeral shaft 15.2 cm proximal to the humeroradial joint, and the biceps collectively inserted on the radial tuberosity 3.0 cm distal to the same joint. As influenced by their proximal attachment locations, the heads achieved maximal torque (defined at 90° to radius) in succession of BBSH, BBLH, then BBAH. SIGNIFICANCE. BBAHs may offer strength advantages in progressive flexion of the forearm, but their persistence risks neurovascular impingement. Comparably weaker structure (e.g., smaller mass, shorter fascicles) also increases the likelihood for BBAHs to tear indistinctly of BBLH or BBSH involvement.

18.

*AVILA, Katherine E.[1], Hannah E. STADLER[1], Mario G. LOOMIS[2], Jamie WIKENHEISER[2], Guillermo GONZALEZ[3], Andrea LOPEZ[3], Gilberto RUIZ-DEYÁ[3] and Jailenne I. QUIÑONES-RODRÍGUEZ[2]. [1]College of Osteopathic Medicine, Sam Houston State University, Conroe, TX, 77304, USA; [2]Department of Clinical Anatomy, College of Osteopathic Medicine, Sam Houston State University, Conroe, TX, 77304, USA; [3]Department of Urology, Ponce Health Sciences University, Ponce, PR 00716-2347, USA.

Cadaveric Morphometric Analysis of Prostatic Artery–Neurovascular Relationships.

INTRODUCTION. Anatomical variation of the prostatic artery (PA) and its relationship to the neurovascular bundle (NVB) influence surgical dissection planes during radical prostatectomy and other prostate-directed procedures. Most published data derive from procedural cohorts, particularly prostatic artery embolization studies, rather than population-based anatomical samples, and demographic stratification is rarely reported. This pilot study characterizes morphometric relationships between the PA, NVB, and prostate landmarks in a population-based adult Caucasian cadaveric cohort. METHODS: Eighteen cadaveric specimens were analyzed for laterality testing. Measurements were recorded per side and included PA-to-apex distance, PA-to-NVB distance at mid-gland, PA-to-base distance, PA diameter, and prostate dimensions (length × width). Paired t-tests evaluated left–right differences. SUMMARY: Primary surgical proximity endpoints showed no statistically significant laterality differences. Mean paired differences (R–L) were 0.81 mm for PA–apex distance (95% CI –7.96 to 9.58; p=0.8459) and –0.34 mm for PA–NVB distance (95% CI –8.02 to 7.34; p=0.9255), indicating symmetry in critical neurovascular relationships. PA diameter also showed no significant asymmetry (–0.085 mm; p=0.5990). PA–base distance showed the largest difference (–7.80 mm) but did not reach significance (p=0.0629). Prostate width showed no laterality difference, while length demonstrated a non-significant trend (p=0.0764). Effect sizes were small, supporting overall bilateral morphometric symmetry. CONCLUSIONS: In this cadaveric-based Caucasian cohort, PA relationships to the NVB and prostate landmarks demonstrate relative bilateral symmetry with measurable inter-individual variability. These quantitative anatomical findings provide foundational morphometric data relevant to nerve-sparing and vessel-preserving surgical approaches and support future comparative investigations across diverse populations.

continued on next page

19.

*FEELDY, Evan M.[1], Joseph P. OSMUNDSON1, Connor J. SINGREY[1], Robert E. VAN DEMARK JR[2], and Ethan L. SNOW[1]. [1]College of Natural Sciences, South Dakota State University, Brookings, SD, 57007, USA; 2Sanford School of Medicine, University of South Dakota, Vermillion, SD,57069, USA.

Bilateral Pronator Quadratus Muscles Exhibiting Twisted Morphology: A Kinematic Case Analysis.

INTRODUCTION. Located deep in the distal aspect of the anterior forearm, the pronator quadratus (PQ) pronates the forearm and stabilizes the radioulnar joint. Non-typical morphologies of the PQ have been described; however, those involving biomechanical and kinematic analyses are scarce. The objectives of this study are to calculate the maximal isometric forces produced by morphologically twisted PQs and extrapolate those forces in a kinematic torque analysis model. RESOURCES. PQ muscle variations were discovered during routine dissection of an adult human cadaver. The aberrations were photographed in situ with scale, and gross parameters of each muscle component (n = 3 per PQ) were measured. Mean postmortem fixed sarcomere lengths were determined via histology (paraffin embedding; 5 µm sectioning, H&E staining) and digital light microscopy, and normalized maximal isometric forces (Fmax) were calculated. Cross-sectional kinematic models were constructed to determine attachment angles, Fmax force vectors, and torque at every 10° of pronation. DESCRIPTION. The left main PQ (LPQ1, Fmax = 34.62 N) presented with two accessory heads (LPQ2, Fmax = 3.87 N; LPQ3, Fmax = 3.01 N) which appeared twisted between the radius and ulna. The right PQ was comparable in form and function (RPQ1, Fmax = 30.81 N; RPQ2, Fmax = 2.95 N; RPQ3, Fmax = 2.67 N). As the radius pronates around the ulna, each PQ head achieves its greatest torque efficiencies in different positions. SIGNIFICANCE. Kinematic analysis of the twisted PQ accessory heads highlights potential effects on pronation mechanics and distal radioulnar joint stability. This study thereby demonstrates functional and clinical implications that can be translationally applied to other non-typical musculoskeletal morphologies. Findings from this report may particularly aid clinicians who encounter the PQ during diagnostic evaluation or operative procedures where anatomical variations may influence assessment or surgical approach.

20.

*JONES, Mary K.[1], Seth K. NANCE[1], Mario G. LOOMIS[2], and Jailenne I. QUIÑONES-RODRÍGUEZ[2]. [1]College of Osteopathic Medicine, Sam Houston State University, Conroe, TX, 77304, USA; [2]Department of Clinical Anatomy, College of Osteopathic Medicine, Sam Houston State University, Conroe, TX, 77304, USA.

Morphometric Analysis of Third Division Axillary Artery Branching Relative to Surgical Landmarks.

INTRODUCTION. Variations of the third division of the axillary artery have important implications for axillary, breast, and upper extremity procedures, including lymph node dissection, reconstruction, and fracture fixation. Classical descriptions identify the subscapular, posterior circumflex humeral, and anterior circumflex humeral arteries as terminal branches, but their relationships to reproducible surgical landmarks remain incompletely defined. This study evaluated branching patterns and landmark-based morphometrics in a cadaveric cohort. METHODS. Thirty-two axillae from male and female Caucasian donors were dissected at a single anatomy laboratory. Branching configuration, side, sex, and specimen data were recorded. Measurements included distances from each branch origin to the lateral border of pectoralis minor, inferior border of teres major, and coracoid process, as well as branch diameters. Statistical analysis assessed the effects of side and branch type and evaluated inter-individual variability. SUMMARY. No significant effect of side was observed relative to pectoralis minor (P=0.987), teres major (P=0.152), or coracoid process(P=0.636). Bilateral differences were minimal across landmarks (≤0.674 cm), with confidence intervals including zero. No significant differences among branch types were detected at any landmark (P>0.90), and no branch-by-side interactions were identified.

continued on next page

Cadaver identity contributed significantly to overall variance (P<0.0001), with between-subject variability exceeding variance attributable to laterality or branch classification. CONCLUSIONS. Laterality and branch type showed relative morphometric symmetry, but substantial inter-individual variability characterized third-division axillary artery anatomy. These findings support individualized anatomical assessment and highlight the clinical value of landmark-based morphometric characterization in surgical planning.

21.

*NANCE, Seth K.[1], Mary K. JONES[1], Mario G. LOOMIS[2], and Jailenne I. QUIÑONES-RODRÍGUEZ[2]. [1]College of Osteopathic Medicine, Sam Houston State University, Conroe, TX, 77304, USA; [2]Department of Clinical Anatomy, College of Osteopathic Medicine, Sam Houston State University, Conroe, TX, 77304, USA.

Demographic Disparities in Third-Division Axillary Artery Branching.

INTRODUCTION. Anatomical variation of the third division of the axillary artery has significant clinical implications involving the shoulder and upper extremity. However, considerable variation in branching configuration and morphometric relationships has been reported. Prior investigations have yielded inconsistent findings and often lack demographic stratification, limiting comparative anatomical analyses across populations. METHODS. A structured literature synthesis was conducted in accordance with PRISMA guidelines to identify human anatomical studies published between 2005 and 2025. After removing duplicates and screening for eligibility, 25 studies were included. Extracted variables included branching configuration, variant origins (e.g., common trunks, aberrant origins), vessel diameter and length measurements, laterality, sex, and reported population background. SUMMARY. Considerable variability in third-division branching patterns was identified, including common trunk formation between the subscapular and anterior and posterior circumflex humeral arteries, atypical origins from the second division, and differences in vessel caliber and distance from anatomical landmarks. Morphometric parameters demonstrated inter-study variability, and demographic reporting was inconsistent, limiting direct comparisons of populations. Available data suggest potential population-related differences in branching frequency; however, Hispanic populations remain markedly underrepresented. CONCLUSIONS. Substantial variation exists in both branching configuration and morphometric parameters of the third division of the axillary artery. Limited demographic stratification restricts the ability to assess population-specific risk profiles. Standardized, demographically inclusive anatomical investigations may enhance preoperative planning, improve interpretation of imaging, and reduce vascular complications during axillary and upper extremity procedures.

22.

*COWDREY, Madison B[1], Lauren V FELL[1] , Michael J. BOUCHOUKIAN[2], Robert W. RICE[3], and Jailenne I. QUIÑONES-RODRÍGUEZ[3]. [1]College of Osteopathic Medicine, Sam Houston State University, Conroe, TX, 77304, USA; [2]Department of Library Science and Technology, Sam Houston State University, Conroe, TX, 77304, USA; [3]Department of Clinical Anatomy, College of Osteopathic Medicine, Sam Houston State University, Conroe, TX, 77304, USA.

Emerging Technologies in Embryology Education: An Analysis of Educational Applications and Outcomes.

INTRODUCTION. Embryonic development is difficult to teach due to its spatiotemporal complexity, including morphogenesis, cellular migration, and tissue differentiation, often leading to customary two-dimensional resources failing to convey these multidimensional processes completely. Emerging technologies, including virtual reality (VR), extended reality (XR), three-dimensional (3D) digital modeling, and 3D printing, have been proposed as tools to enhance spatial and conceptual integration in anatomy education. This study synthesized current evidence on the use and educational impact of these modalities on embryological

continued on next page

education. RESOURCES. A comprehensive search across five databases identified peer-reviewed studies evaluating emerging technologies in embryology education across undergraduate medical education (UME), graduate medical education (GME), and related health professions programs. Of 2,843 studies screened, 30 met inclusion criteria. Data included learner level, modality, embryologic focus, and outcomes related to knowledge gains, spatial understanding, learner perceptions, and retention. DESCRIPTION. Most studies were conducted in UME settings and focused on cardiac development and congenital heart defects. Reported outcomes frequently showed improvements in learner satisfaction and self-perceived understanding. Objective learning outcomes varied by technological modality and the complexity of the embryologic concept addressed. Limited research was identified on neurulation, body cavity formation, and peritoneal development. SIGNIFICANCE. Emerging technologies show promise in enhancing embryology education, but current applications remain concentrated in select developmental domains and frequently rely on perception-based metrics. Gaps persist in content coverage and rigorous evaluation. These findings inform the development of technology-integrated, embryology curriculum and highlight the need for controlled studies to evaluate performance outcomes.

23.

*STADLER, Hannah E.[1], Katherine AVILA[1], Mario G. LOOMIS[2], Jamie WIKENHEISER[2], Guillermo GONZALEZ [3], Andrea LOPEZ [3], Gilberto RUIZ-DEYÁ[3] and Jailenne I. QUIÑONES-RODRÍGUEZ[2]. [1]College of Osteopathic Medicine, Sam Houston State University, Conroe, TX, 77304, USA; [2]Department of Clinical Anatomy, College of Osteopathic Medicine, Sam Houston State University, Conroe, TX, 77304, USA; [3]Department of Urology, Ponce Health Sciences University, Ponce, PR 00716-2347, USA.

Prostatic Vascular and Neurovascular Bundle Variants: Implications for Nerve-Sparing Prostatectomy.

INTRODUCTION. Preservation of erectile function after radical prostatectomy depends on accurate identification of the cavernous plexus, neurovascular bundle (NVB), and periprostatic vasculature. Although nerve-sparing techniques have advanced, variability in prostatic arterial anatomy and its spatial relationship to the NVB may influence dissection planes, bleeding risk, and postoperative functional outcomes. Despite its clinical importance, detailed characterization of vascular-neural variation, including potential ethnic differences, remains limited. METHODS. A structured literature synthesis was conducted using Web of Science and Scopus to identify peer-reviewed studies (2000–2025) addressing anatomical variation in the prostatic arterial supply and its relationship to periprostatic neurovascular structures. Inclusion criteria were human male anatomical studies published in English. Articles were screened using predefined eligibility criteria. SUMMARY. Studies demonstrate substantial variability in the origin, number, and branching patterns of prostatic arteries, including contributions from the inferior vesical, internal pudendal, and obturator arteries, as well as accessory pudendal arteries. Variation in the topographic relationship between arterial branches and the NVB has been reported, affecting identification of safe dissection planes during nerve-sparing procedures. However, few studies provide detailed spatial mapping of vascular-neural relationships, and comparative analyses across ethnic populations, including Hispanic cohorts, are scarce. CONCLUSIONS. Marked variability in prostatic arterial anatomy and its relationship to the NVB may alter safe dissection planes and increase the risk of vascular or neural injury if unrecognized. Limited data on ethnic variability restrict efforts to tailor surgical approaches. Focused anatomical investigation is needed to improve operative planning, reduce complications, and optimize functional preservation.

continued on next page

24.

*KIM, Su-Jeong, Kyu-Lim LEE, Jiong-Zhen Piao, Kyung-Seok Hu, and Hee-Jin Kim. Division in Anatomy and Developmental Biology, Department of Oral Biology, Human Identification Research Institute, BK21 FOUR Project, Yonsei University College of Dentistry, Seoul, 03722, South Korea.

Validity and Reliability of Intraoral Ultrasonography for the Assessment of Periodontal Structures.

INTRODUCTION. Recent advances in intraoral ultrasonography (US) have enabled quantitative assessment of periodontal tissues; however, limitations remain regarding applicable measurement sites and structural visualization. This study aimed to investigate the anatomical accuracy and measurement reproducibility of intraoral US imaging for soft and hard periodontal tissues, comprising buccal and lingual (or palatal) surfaces, as well as dental calculus. METHODS. US images were obtained from the gingival margin (GM), alveolar bone crest (ABC), and cementoenamel junction (CEJ) of 108 teeth from fixed human cadavers. These regions were then sectioned and scanned to generate reference images. Three parameters were measured: (1) the distance between the ABC and GM, (2) the distance between the ABC and CEJ, and (3) the linear length of dental calculus on the tooth surface. All measurements were conducted twice by the same examiner for reliability analysis. SUMMARY. The results revealed that US images clearly delineated the gingiva, CEJ, alveolar bone, and calculus according to their echogenic characteristics. No statistically significant differences were found between ultrasound and reference measurements ($p > .05$). Intraclass correlation coefficients ranged from 0.68 to 0.91, and Bland–Altman analysis revealed 95% limits of agreement within ±1.46 mm for ABC–GM and ABC–CEJ, and ±0.47 mm for calculus length. These findings confirm that intraoral US reliably reflects anatomical structures with high fidelity. Conclusion. The study indicates the potential of US as a valid and reproducible modality for comprehensive periodontal evaluation, overcoming previous limitations that focused solely on individual components. (The funding for this research was provided by the National Research Foundation of Korea (NRF) grant funded by the Korea government [grant number MSIP, NRF-RS-2024-00406281].)

25.

*FIBIGER Grzegorz[1,2], Kamil MOŻDŻEŃ[1,2], Ignacy JASTRZĘBSKI[1], Michał MALCZAK[4], Agnieszka MURAWSKA[1], Wiktoria BŁACHUT[1], Tomasz Kozioł[2], Arseniya BIAZHKO[1], Karol JASZEWSKI[1], Kacper Stolarz[1], Jerzy WALOCHA[2,3], and Przemysław PĘKALA[2,3]. [1]Jagiellonian University Medical College, Faculty of Medicine, Kraków, 31008, Poland; [2]International Evidence-Based Anatomy Working Group, Kraków, 31034, Poland; [3]Department of Anatomy, Jagiellonian University Medical College, Kraków, 31034, Poland; [4]Department of Orthopedics and Traumatology, Jagiellonian University Medical College, Kraków, 30688, Poland;

Pes Anserinus Variability and Accessory Bands: A Novel Morphological Classification.

INTRODUCTION. The pes anserinus is a knee region formed by semitendinosus, gracilis, and sartorius tendons. Accessory tendon bands are frequently described, but their prevalence, morphology, and distal attachments remain inconsistently reported because terminology and classification do not capture combined variants. This study evaluated the prevalence, morphology, and distal attachment patterns of accessory pes anserinus tendon bands and proposed a classification system for complex configurations. METHODS. Sixty-two formalin-fixed lower limbs from 41 cadavers were dissected using a standardized protocol. The presence, number, and distal attachment sites of accessory semitendinosus, gracilis, and sartorius tendon bands were recorded. Measurements included band length, width, and distance from the tibial footprint to band origin. Data were analyzed by sample and sex. SUMMARY. Accessory pes anserinus bands were common and arose mainly from the semitendinosus tendon. At least one accessory semitendinosus band was identified in 58 of 62 limbs (93.5%); primary, secondary, and tertiary bands occurred in 28 (45.2%), 30 (48.4%), and 2 limbs (3.2%), respectively. Accessory gracilis bands occurred in 14 limbs (22.6%) and accessory sartorius bands in 2 limbs (3.2%). Fourteen configurations were

continued on next page

identified, with type 1-1-3ba most common (29.0%). Primary accessory semitendinosus bands most often inserted on tibia, whereas secondary and tertiary bands most often inserted into the crural fascia. Male specimens showed greater distances between the semitendinosus footprint and band origin. These findings may improve surgical planning and interpretation of medial knee anatomy. CONCLUSIONS. Accessory pes anserinus tendons, especially accessory semitendinosus bands, appear to be a common configuration rather than a rare variant. A modular classification based on tendon number and attachment topology provides a practical framework for consistent description of pes anserinus complexity.(This research, and dissemination of its results was funded by the Ministry of Science and Higher Education (Republic of Poland) under the program “Support for students in enhancing their competitions and skills” grant number [MNiSW/2025/DPI/648]).

26.

*FIBIGER Grzegorz[1], Kamil MOŻDŻEŃ , Ignacy JASTRZĘBSKI[1], Michał MALCZAK[2], Edward PĘDZIWIATR[1], Jerzy WALOCHA [3], Przemysław PĘKALA[3]. [1]Jagiellonian University Medical College, Faculty of Medicine, Kraków, Poland; [2]Department of Orthopedics and Traumatology, Jagiellonian University Medical College, Kraków, Poland; [3]Department of Anatomy, Jagiellonian University Medical College, Kraków, Poland.

Congenital Cruciate Ligament Agenesis with Distal Femoral Dysplasia: A Two-Stage Approach.

INTRODUCTION. Congenital agenesis of the cruciate ligaments is a rare developmental anomaly that may involve the anterior (ACL), posterior (PCL), or both ligaments. Combined absence with distal femoral dysplasia presents major anatomical and surgical challenges. We report a case of ACL and PCL agenesis associated with intercondylar notch dysplasia treated with a planned two-stage reconstructive procedure aimed at restoring physiological knee kinematics and long-term joint stability. RESOURCES. Clinical examination and magnetic resonance imaging (MRI) confirmed the absence of both cruciate ligaments and narrowing of the intercondylar notch. Imaging also demonstrated abnormal femoral morphology that affected the graft placement corridors. Standard orthopedic techniques were used, including notch osteoplasty and ligament reconstruction with Achilles tendon allografts. DESCRIPTION. The patient demonstrated significant anterior and posterior instability with functional limitations in daily activities. A planned two-stage surgical approach was implemented. The first stage consisted of PCL reconstruction preceded by distal femoral osteoplasty to restore notch morphology and optimize graft placement. Following structured rehabilitation and recovery of range of motion, ACL reconstruction was performed as the second stage using an Achilles tendon allograft. At one-year follow-up, the patient reported marked functional improvement with near-complete resolution of instability and only mild discomfort after excessive activity, without recurrent giving-way episodes. SIGNIFICANCE. This case emphasizes the importance of anatomical correction of distal femoral dysplasia in congenital cruciate agenesis. A staged, anatomy-driven approach may facilitate biomechanical restoration, reduce graft-related complications, and improve long-term functional outcomes. (This research and dissemination of its results were funded by the Ministry of Science and Higher Education (Republic of Poland) under the program “Support for students in enhancing their competitions and skills” grant number [MNiSW/2025/DPI/648]).

continued on next page

27.
*NGUYEN, Alicia and Manuel CEVALLOS. Department of Medical Education, Creighton University School of Medicine, Phoenix, AZ, 85012, USA.

Beyond Killian's Triangle: An Incidentally Identified Retropharyngeal Wall Outpouching.

INTRODUCTION. In general, pharyngoesophageal diverticula arise from a weak area in the posterior wall of the pharynx (pharyngeal constrictor) and the cervical esophagus and are classified based on their relationship to the cricopharyngeal muscle. Outpouching lesions in this region can be true or false diverticula and are related to the areas classified as Zenker diverticulum, Killian–Jamieson diverticulum, Laimer diverticulum, and atypical pharyngeal pouches. Size and location determine whether they are asymptomatic or have clinical implications. RESOURCES. Standard cadaveric dissection techniques were used to expose the retropharyngeal space during the anatomy course; a donor preserved in 4% formaldehyde exhibited an outpouching of the posterior pharyngeal wall. Direct measurements were obtained to determine the lesion's size and spatial relationship. DESCRIPTION. In the retropharyngeal wall, an outpouching measured 7.9 mm in diameter and 5.3 mm in depth, located on the left side of the midline (it doesn't cross the midline). It is a complete outpouching. The relationship between the diverticula and the cricopharyngeal muscle will be discussed during the conference presentation to differentiate the types of diverticula in this region.SIGNIFICANCE. Incidental cadaveric identification of a retropharyngeal wall outpouching underscores the importance of recognizing anatomical structures and lesions in the pharyngoesophageal region. Careful localization relative to surrounding musculature and adjacent structures strengthens understanding of neck anatomy. Documentation and discussion of such variations contribute to clinical anatomical education and highlight structural relationships that may not be fully appreciated in standard anatomical descriptions. The final diagnostic interpretation, based on anatomical relationships, prevalence, clinical implications, and treatment, will be discussed.

28.
*MCMAHAN, Evan R.[1], Joseph CHERULLO[2], Caleb MOFFETT[2], Daniel T DALY[2], and Yun TAN[2].[1]Saint Louis University School of Medicine, St. Louis, MO, 63104, USA; [2]Center for Anatomical Science and Education, Saint Louis University School of Medicine, St. Louis, MO, 63104, USA.

Variability of the Dorsal Scapular Artery Relative to the Brachial Plexus: A Cadaveric Study.

INTRODUCTION. The dorsal scapular artery (DSA) demonstrates variability in its origin and course relative to the brachial plexus and anterior scalene muscle (ASM), yet detailed anatomical characterization in large cadaveric samples is limited. This study aimed to determine the subclavian origin and course of the DSA, quantify its anatomical relationships to the ASM and first rib, and compare findings between sexes. METHODS. Cadaveric dissection study was performed on 133 cadavers (67 female, 66 male) received through the Saint Louis University School of Medicine Gift Body Program with signed informed consent. The DSA was identified when present, and its origin and course relative to the brachial plexus trunks were recorded. Distances from the lateral border of the ASM to the DSA and to the first rib were recorded. SUMMARY. The DSA originated from the subclavian artery in all identifiable specimens and was present bilaterally in 46 cadavers (34.59%), unilaterally in 38 (28.57%), and absent in 49 (36.84%); overall, a DSA was identified on the left side in 73 cadavers (54.9%) and on the right side in 64 cadavers (48.1%). Sex-specific analysis showed similar distributions between males and females. When present, the DSA most commonly coursed between the upper and middle trunks of the brachial plexus (left: 67.15%; right: 65.63%), with fewer cases between the middle and lower trunks. Mean distances from the ASM to the DSA were 7.58mm on the left and 9.37mm on the right, while the ASM-to-first rib interval measured 25.58mm

continued on next page

on the left and 23.91mm on the right. CONCLUSIONS. The DSA shows a consistent subclavian origin but variable relationships to the brachial plexus, ASM and first rib, providing quantitative reference data on vascular variation in the root of the neck. These findings are clinically relevant for supraclavicular and interscalene nerve blocks and other procedures in this region, where unrecognized DSA variation may increase risk of procedural complications.

29.
*BECKER, Eric B., Rani RANDELL, Hibah AHSAN, William SEXTON, Zara MANNA, Jacob THOMAS, and Malli BARREMKALA. Oakland University William Beaumont School of Medicine, Rochester, MI, 48309, USA.

Corona Mortis: Cadaveric Prevalence and Clinical Significance of a Retropubic Vascular Variant.

INTRODUCTION. Corona mortis (CMOR) is a clinically important vascular variation in the retropubic region, formed by an anastomosis between the obturator vessels and branches of the external iliac or inferior epigastric system. Because it courses along the superior pubic ramus within the retropubic space of Retzius, this vessel is particularly vulnerable during pelvic, inguinal hernia, and acetabular surgical procedures, where unrecognized injury can lead to significant hemorrhage. The purpose of this study was to document the prevalence and anatomical characteristics of CMOR identified during human donor dissection and to emphasize its relevance to surgical practice. RESOURCES. Standard pelvic dissections were performed on 22 human donors (44 hemi-pelvises) in a medical gross anatomy laboratory. The obturator canal and adjacent retropubic region were carefully exposed, and the obturator vessels were traced proximally to determine their origin and identify arterial, venous, or combined CMOR variants. All findings were photographically documented. DESCRIPTION. Corona mortis was identified in 3 of 22 donors (13.6%). Two donors demonstrated unilateral CMOR, while one donor demonstrated bilateral CMOR, resulting in a hemi-pelvic prevalence of 9.1%. Arterial CMOR was observed in two donors, venous CMOR in two donors, and one donor demonstrated both arterial and venous components. Although the prevalence observed in this cohort was lower than that reported in many previous studies, these findings highlight the considerable anatomical variability of CMOR and its potential for bilateral presentation. SIGNIFICANCE. Corona mortis is a clinically significant retropubic vascular variant with important implications for pelvic surgery. Recognition of its possible presence, laterality, and vascular composition is essential to minimize the risk of iatrogenic injury and hemorrhagic complications during surgical and interventional procedures.

30.
*VATANPOOR, Iman[1], Majid ALIMOHAMMADI[1], Manouchehr MADANI CIVI[1], and Majid DOROUDI[1]. [1]Department of Cellular and Physiological Sciences, Faculty of Medicine, University of British Columbia, Vancouver, BC, V6T 1Z3, Canada.

Anterior Course of the Phrenic Nerve with Subclavian Vein Indentation: A Cadaveric Observation.

INTRODUCTION. The phrenic nerve typically descends on the anterior scalene muscle and enters the thorax posterior to the subclavian vein. A variation in which the nerve passes anterior to the subclavian vein may increase the risk of iatrogenic injury during subclavian venous access. METHODS. Standard cervical dissection was performed on an adult cadaver. Neurovascular relationships at the thoracic inlet were documented with high-resolution photography and evaluated in relation to central venous catheterization practices. SUMMARY. At the thoracic inlet, the right phrenic nerve coursed anterior to the subclavian vein. Dissection images demonstrated a clear external indentation on the anterior wall of the vein caused by the nerve, indicating sustained mechanical contact. This finding suggests that similar contour changes of the subclavian vein may be detectable in vivo using ultrasonography prior to venipuncture or central venous catheter placement. CONCLUSIONS. An anteriorly positioned phrenic nerve may lie within the needle trajectory during subclavian access, increasing the risk of

continued on next page

hemi-diaphragmatic paralysis if injured. We propose a preventive strategy: pre-procedural ultrasound assessment of the subclavian vein to identify focal indentation or contour irregularity suggestive of an anterior phrenic nerve. Recognition of this variation may guide modification of puncture site or technique and reduce the risk of iatrogenic nerve injury. This anatomically informed, ultrasound-based safeguard may enhance procedural safety.

31.
*VATANPOOR, Iman, Majid ALIMOHAMMADI, Manouchehr MADANI CIVI, and Majid DOROUDI. Department of Cellular and Physiological Sciences, Faculty of Medicine, University of British Columbia, Vancouver, BC, V6T 1Z3, Canada.

Intramuscular Piercing of Brachial Plexus Roots in the Anterior Scalene Muscle: A Cadaveric Case.

INTRODUCTION. The brachial plexus normally emerges between the anterior and middle scalene muscles within the interscalene triangle before contributing branches that enter the upper limb. However, anatomical variations may occur in which individual nerve roots pierce the anterior scalene muscle, altering the expected anatomical course. These variants represent clinically important yet underrecognized configurations that may predispose patients to nerve compression and neurogenic symptoms. Conventional imaging modalities such as MRI and CT scans may not reliably detect such variants, which can be contribute to diagnostic uncertainty in patients presenting with otherwise unexplained neurological symptoms. RESOURCES. A variation was identified during routine cadaveric dissection performed to investigate clinically relevant anatomical relationships of the brachial plexus and surrounding musculature. DESCRIPTION. During dissection, C5 and C6 nerve roots were observed to be passing directly through anterior scalene muscle fibers rather than following the typical interscalene pathway. This intramuscular course altered the expected anatomical configuration and created a potential site of nerve entrapment. Adjacent muscular and vascular structures demonstrated otherwise normal anatomical relationships. The contralateral side demonstrated typical brachial plexus anatomy. SIGNIFICANCE. This variation provides an anatomical basis for otherwise unexplained upper limb symptoms such as pain, paresthesia, or weakness when standard imaging fails to identify a cause. Recognition of this variant is important in evaluation of suspected neurogenic thoracic outlet syndrome. This configuration may also increase the risk of nerve injury during cervical surgical procedures, regional anesthesia, and brachial plexus block. Awareness of this variation improves diagnostic accuracy and procedural safety.

32.
*GUO, Wenwen[1], Travis BENTLEY[1], Daniel DALY[2], Meadow CAMPBELL[2], and Yun TAN[2]. [1]School of Medicine, Saint Louis University, St. Louis, MO, 63104, USA. [2]Center for Anatomical Science and Education, Department of Surgery, School of Medicine, Saint Louis University, St. Louis, MO, 63104, USA.

Rare Bilateral Variations of the Costocervical Trunk.

INTRODUCTION. The thyrocervical (TCT) and costocervical (CCT) trunks typically arise from the first and second parts of the subclavian artery, respectively. TCT usually gives rise to the inferior thyroid, suprascapular, and transverse cervical arteries, while CCT branches into the deep cervical and highest intercostal arteries. Research on CCT variability is limited. TCT is more prone to variation, commonly associated with the internal thoracic, inferior thyroid, and ascending cervical arteries. Though studies have identified variable origins of transverse cervical and suprascapular arteries, CCT is rarely involved. RESOURCES. This case was identified in a 92-year-old male cadaver, which was obtained through the Saint Louis University School of Medicine (SLUSOM) Gift Body Program in the Center for Anatomical Science and Education (CASE), with informed consent from the donor. DESCRIPTION. This case presented a bilateral variation of the transverse cervical artery and a right-sided

continued on next page

variation of the suprascapular artery. Instead of originating from the TCT, these vessels branched from the large CCT in the second part of the subclavian arteries. This CCT gave off the deep cervical, highest intercostal, and superficial and deep branches of the transverse cervical bilaterally, as well as the right suprascapular artery. The CCT ran between the C7/C8 roots of the brachial plexus and between the middle and posterior scalene muscles on the left side, while on the right side, it passed anterior to the middle scalene muscles and between the middle and inferior trunks of the brachial plexus. SIGNIFICANCE. The anatomy of the thyrocervical and costocervical trunks is of great significance in endovascular interventions. Knowing the course and origin of the transverse cervical and suprascapular arteries ensures successful trauma care, coronary bypass, head and neck reconstructive procedures, and the management of suprascapular neuropathy.

33.

*SEXTON, William K., Malli BARREMKALA, Jacob THOMAS, Rani RANDELL[1], Zara MANNA, Hibah AHSAN, and Eric BECKER. Oakland University William Beaumont School of Medicine, Rochester, MI, 48309, USA.

Complete Absence of the Musculocutaneous Nerve with Median Nerve Substitution: A Cadaveric Study.

INTRODUCTION. Variations in the musculocutaneous nerve (MCN) are fairly common, occurring in 10–30% of people, but complete absence of MCN is rare and clinically relevant. When MCN is absent, the median nerve takes over its usual motor and sensory roles, which can lead to unexpected findings or a higher risk of injury during surgery. The aim of this study was to describe a rare case of complete absence of MCN identified during cadaveric dissection and to explore its prevalence and clinical relevance. RESOURCES. A routine bilateral dissection of the brachial plexus was performed in a gross anatomy laboratory on an 88-year-old female donor, with careful tracing of all cords and terminal branches. The nerve variation was classified using the Le Minor system. To estimate prevalence, 31 additional donors (51 upper limbs) were examined for musculocutaneous nerve anatomy. All findings were documented photographically. DESCRIPTION. The MCN was absent on the right side and the median nerve supplied the muscles of the anterior compartment of the arm and continued distally as the lateral antebrachial cutaneous nerve, consistent with a Le Minor type V variation. Among the additional upper limbs examined, absence of the musculocutaneous nerve was observed in 1 of 51 limbs (1.96%), while the remaining limbs showed typical anatomy. SIGNIFICANCE. Although rare, complete absence of MCN has important clinical implications. This variation may complicate surgical approaches, regional anesthesia, and interpretation of median nerve injuries. Recognizing this anatomy can help reduce diagnostic errors and prevent unintended nerve injury.

34.

*BOGARD, Madeline R.[1], David HU2, Mehri FAYAZI[2], Arshad KALEEM[2], Daniel A. CONDE[3], Aliasghar ARABI MIANROODI[1] and Balachandar KATHIRVELU[3]. [1]Paul L. Foster School of Medicine, Texas Tech University Health Sciences Center at El Paso, El Paso, TX, 79905, USA; [2]Woody L. Hunt School of Dental Medicine, Texas Tech University Health Sciences Center at El Paso, El Paso, TX, 79905, USA; [3]Physical Therapy and Movement Sciences, College of Health Sciences, The University of Texas at El Paso, El Paso, TX, 79902, USA.

Surgical Anatomy of the Facial Nerve: Distance to First Branch and Variations in Branching Patterns.

INTRODUCTION. This study aimed to measure the distance at which the facial nerve branches from the stylomastoid foramen and to document its patterns of division. A detailed understanding of these anatomical relationships is essential, as variations in the course and branching of the facial nerve have direct implications for surgical procedures involving the parotid gland and facial region. Accurate knowledge of these patterns and measurements enhances surgical safety, aids in operative planning, and helps reduce the risk of iatrogenic nerve injury. METHODS. Twenty-nine facial nerve specimens from sixteen cadavers were examined. The facial

continued on next page

nerve was carefully dissected in relation to the retromandibular vein and traced superiorly to identify its first branch. This branch was then tracked retrograde to the facial nerve trunk, and the branching pattern was then followed anteriorly through the parotid gland. After the stylomastoid process was digitally palpated, a digital width gauge was used to measure the distance from the stylomastoid foramen to the first branch point of the facial nerve trunk. SUMMARY. The mean distance from the stylomastoid foramen to the first facial nerve branch was 14.04 mm, with no sex-related differences observed. Three branching patterns were identified: the most common involved the buccal branch arising from the lower division (44.83%), followed by emergence from the upper division (37.93%), and less frequently directly from the main trunk (17.24%). CONCLUSIONS. This study offers practical guidance for locating the first division of the facial nerve relative to the stylomastoid foramen and characterizing its major branching patterns. These anatomical insights are highly relevant in surgical settings, providing clinicians with information that can help minimize the risk of facial nerve injury during parotid and other facial procedures. (Acknowledgments: TTUHSC Lubbock, Institute of Anatomical Sciences—Willed Body Program).

35.

*KOUL, Shweta S.[1], David G. ADAMS[1], Steven N. POPOFF[1], and Nicole L. GRIFFIN[1]. [1]Department of Biomedical Education and Data Science, Lewis Katz School of Medicine at Temple University, Philadelphia, PA, 19140, USA.

The Persistent Median Artery Extending into the Palm: A Cadaveric Survey.

INTRODUCTION. The persistent median artery (PMA) represents incomplete regression of an embryonic vessel that has been reported with increasing frequency in the general population. A PMA that crosses the wrist is clinically relevant as it may compress the median nerve and/or be at risk for iatrogenic injury during specific surgeries. This study aimed to characterize each PMA from origin to termination for the purpose of determining whether course in the forearm predicts distribution in the hand. METHODS. A total of 124 forearms (n=62 human donors: 36 females; 26 males) were dissected and the PMA was identified in 114 forearms. Of the 114 forearms, sixteen (n=11 donors: 7 females; 4 males) crossed the wrist. SUMMARY. PMAs originated from either the ulnar (n=9), common interosseous (n=3), or anterior interosseous (n=4) artery. Of the nine PMAs that originated from the ulnar artery, seven of them bifurcated the median nerve in the forearm. In six hands, the PMA joined the ulnar artery to form the superficial palmar arch (SPA). In the other ten hands, the PMA was not involved in formation of the SPA. Of these ten, eight supplied digits of the hand along with the radial artery. CONCLUSIONS. The origin of the specific type of PMAs that crossed the wrist was variable, however only those derived from the ulnar artery bifurcated the median nerve in the forearm. This finding suggests that a PMA of ulnar artery origin may be a risk factor for median nerve compression. Furthermore, though PMA origin was neither predictive of its contribution to the SPA nor its involvement in palmar and digital perfusion, it was demonstrated that PMAs crossing the wrist contribute significantly to palmar and digital blood supply. Overall, the results of this study underscore the importance of identifying the presence and distribution of a PMA prior to performing surgical procedures at the wrist and within the hand.

continued on next page

36.

*ROST, Maxwell J.[1], Ryan PROHOFSKY[1], Jackson P. DORSETT[1], Sophie J. BAKRI[2], and Ethan L. SNOW[1]. [1]College of Natural Sciences, South Dakota State University, Brookings, SD, 57007, USA; [2]Department of Ophthalmology, Mayo Clinic, Rochester, MN, 55902, USA.

Involvement of Vortex Vein Anatomy in Chorioretinal Diseases: A Multi-Resource Study.

INTRODUCTION. Vortex veins serve as the primary drainage for the ocular choroid. However, their anatomical characterization is complex due to variation in number of ampullae and scleral exit sites. The purpose of this study is to comprehensively link anatomical, histological, radiographic, and literature-based analyses of vortex veins to their pathophysiological involvement in chorioretinal diseases. METHODS. Cadaveric dissections, histological analyses via digital light microscopy, and wide-field indocyanine green angiography (ICGA) imaging were performed to provide primary data about vortex vein anatomy. A comprehensive literature review was performed using PubMed, Web of Science, and ScienceDirect databases to identify existing human studies involving vortex vein imaging, anatomical measurements, and clinical outcomes from disease-associated findings. SUMMARY. In central serous chorioretinopathy (CSC) subgroups, eyes with asymmetric vortex veins exhibited shorter axial lengths. Across CSC, retinal vein occlusion (RVO), diabetic retinopathy (DR), polypoidal choroidal vasculopathy (PCV), and high myopia subgroups, macular anastomoses were reported more frequently than in unaffected eyes. Additionally, drainage asymmetries were identified at atypical frequencies within pathological cohorts, and posterior vortex veins were observed more commonly in myopic eyes than in healthy emmetropic controls. CONCLUSIONS. While vortex vein anatomy varies widely among individuals, recognizable patterns link specific anatomical presentations to chorioretinal diseases. Shortened axial length, choroidal thickness, and venous congestion all demonstrate pathological markers with related venous drainage patterns. This study organizes and synthesizes a breadth of evidence with multiple imaging modalities and thus may serve as a valuable anatomic-clinical reference for clinicians, educators, and students seeking information about vortex vein anatomy and its relation to clinical phenomena.

37.

*KARTCHNER, Cade R.[1], Andrew C. STUART[1], Daniel A. CONDE[2], and Balachandar KATHIRVELU[2]. [1]Paul L. Foster School of Medicine, Texas Tech Health Sciences Center University, El Paso, TX, 79902, USA; [2] Physical Therapy and Movement Sciences, College of Health Sciences, The University of Texas at El Paso, El Paso, TX, 79902, USA.

Anatomical Variation in Distance from Aortic Arch to Carotid Bifurcation and Clinical Implications.

INTRODUCTION. The carotid bifurcation is the most frequent site of low–shear stress plaque formation, and its anatomical features—including its distance from the aortic arch—are central to understanding stroke-related atherosclerosis. Variability in carotid geometry further contributes to plaque pathogenesis. This study measured the distance of the carotid bifurcation from the aortic arch along with other anatomical parameters. METHODS. Twenty-four carotid artery specimens (10 female, 14 male) from 12 cadavers were examined. After dissection of the carotid triangle, each common carotid artery was isolated from the aortic base to the bifurcation, including approximately one inch of internal and external carotid branches, respectively. Calibrated images were obtained, and two observers recorded diameters of the common carotid artery, carotid sinus, and internal and external carotid arteries using a digital width gauge. Carotid length from the aortic base to the bifurcation was estimated using a -Pythagorean based- geometric model. Statistical analyses were performed using paired and independent t-tests. SUMMARY. Paired t-tests demonstrated a significant right-left difference in the distance from the aortic arch to the carotid bifurcation with mean lengths of 12.82 cm and 13.36 cm, respectively (p= 0.03).

continued on next page

Females demonstrated a significantly greater arch to bifurcation distance than males (13.81 cm vs 11.72 cm). Additionally, the external carotid artery was significantly wider in females (6.27 mm) compared with males (5.26 mm). CONCLUSIONS. Variation in arch-to-bifurcation distance and sex-related differences in carotid dimensions highlight the anatomical diversity of the carotid system. These findings have clinical relevance, as such variability may influence plaque susceptibility, diagnostic interpretation, and surgical or endovascular planning. Further research is warranted. (Acknowledgments: TTUHSC Lubbock, Institute of Anatomical Sciences—Willed Body Program)

38.

*SMESTAD, Nora M.[1], Ethan YOUNG[1], Carly J. ALLEY[2], and Ethan L. SNOW[1]. [1]College of Natural Sciences, South Dakota State University, Brookings, SD, 57007, USA; [2]Sanford School of Medicine, University of South Dakota, Vermillion, SD, 57069, USA.

Comparative Histopathology between Venous Aneurysms and Varicosities: Case Findings.

INTRODUCTION. Chronic venous insufficiency (CVI) is characterized by structural weakening of vein walls and valve cusps, often leading to valve insufficiency and gravitational blood flow. Venous aneurysms (VA) and varicose veins (VV) are common sequelae. Risk of CVI is exacerbated by dysregulation of extracellular matrix remodeling proteins known as matrix metalloproteinases (MMP). This study aims to perform gross and histological analyses of VA and VV pathologies with an evidence-based clinical discussion. RESOURCES. Three separate cadaveric cases were included in the study – Case 1: cephalic vein VA; Case 2: great saphenous vein VA and VV; and Case 3: healthy vein and valve (for reference/control). Each case was photographed with scale. Tissue samples were collected, processed for histology (paraffin embedded), sectioned (5 µm), stained (H&E, McLetchie trichrome), and examined via digital light microscopy (Motic Digital Slide Assistant) for structural and compositional irregularities. DESCRIPTION. The 11 cm x 3.4 cm (length x diameter) cephalic vein VA (Case 1) presented at the distal brachium. Surgical intervention was evident, and a 5.5 cm stent was discovered 18 cm proximal to the VA at the cephalic-axillary venous junction. The 2.2 cm x 2.1 cm great saphenous vein VA (Case 2) presented at the inguinal region, just proximal to a very convoluted 26.7 cm x 0.65 cm VV. Histopathological comparisons revealed compositional irregularities of the weakened (VA) and folded (VV) vein walls compared to a healthy wall and valve (Case 3). SIGNIFICANCE. Comparative gross and histopathological findings between VA and VV cases may provide insight into their systemic comorbidities (e.g., obesity, diabetes, hypertension) and the mechanism by which dysregulated MMP activity impacts vein structures. Understanding how comorbid conditions interact with molecular degradation pathways may influence the development of more targeted preventative, diagnostic, and therapeutic strategies.

39.

*BROWN, Madison E, Cory MCEVOY, Savannah MILLER, Saradha MIRIYALA, Suman MOHANTY, Alena MOLDAN and Miguel ANGELES. Division of Clinical Anatomy, Stanford University School of Medicine, Stanford, CA, 94305, USA.

Anatomical Variants of the Inferior Vena Cava in Anatomy Lab: Educational and Clinical Implication.

INTRODUCTION. The inferior vena cava (IVC) develops through a complex, coordinated sequence of appearance, anastomosis, and regression of venous channels. Deviations in this developmental process can result in congenital anomalies such as a left-sided IVC and duplicated IVC. The purpose of this study was to document two IVC variants found during cadaveric dissection and correlate the findings with embryologic development and clinical relevance. RESOURCES. Donor specimens in an anatomical dissection laboratory were examined

continued on next page

using standard dissection techniques. Photogrammetry was used to create a three-dimensional digital model to preserve the vascular anatomy for continued analysis and teaching. DESCRIPTION. One donor demonstrated a duplicated IVC with bilateral venous channels on either side of the aorta. A second donor demonstrated a dominant left-sided IVC with a right remnant. Both findings likely reflect the persistence of both left and right supracardinal veins, with partial regression on the right in the second case. SIGNIFICANCE. IVC variants may mimic retroperitoneal pathology and complicate surgical procedures, including IVC filter placement. These cases reinforce the importance of embryologic understanding in clinical anatomy and increase awareness that can help prevent diagnostic errors, operative planning, procedural complications and safe retroperitoneal and endovascular interventions.

40.

*GRIMES, Hunter L.[1], Peter J. CHMIEL[1], Divyam GOEL[1], Angel ZEININGER[2], and Daniel SCHMITT[2]. [1]Duke University School of Medicine, Durham, NC, 27710, USA; [2]Department of Evolutionary Anthropology, Trinity College of Arts and Sciences, Duke University, Durham, NC 27708, USA.

Influence Beyond the Lab: How Gross Anatomy Shapes Existential Views of Health Professions Students.

INTRODUCTION. Gross anatomy (GA) challenges health professions students with the complexities of the human body, early-career exposure to death, and existential questions that may arise from the invasive nature of cadaveric dissection. In the context of reduced use of cadaveric dissection in medical education, this study asks how participation in GA affects students' philosophy and prepares them for the emotional challenges of medicine. METHODS. A conditional logic survey was distributed to three healthcare training institutions to query students' existential beliefs and reflections on topics including spirituality, death, end-of-life, and personal relationships before and after participation in GA. Complete de-identified Likert scale responses were compared by Chi-Square. SUMMARY. One hundred and four (91 MD/DO, 13 allied health) responses were included. 80% of students stated that participation in GA stimulated reflection on their existential beliefs and their responses were further analyzed. Students who stated increased comfort after GA with their own mortality were significantly more likely to express comfort with the mortality of others ($p<0.001$). For 47% of respondents, GA strengthened the importance they placed on end-of-life ceremonies. 15.7% of respondents experienced seeing or feeling the presence of their donor; 10.8% reported the presence of other deceased persons. Those endorsing donor presence increasingly reported incompatibilities between their personal beliefs and the biomedical principles of anatomical sciences ($p<0.001$). Overall, 68.6% of students' personal beliefs were strengthened by participation in GA while 13.2% of students found that the experience challenged their preexisting beliefs. CONCLUSIONS. In the everchanging landscape of medical education, these data emphasize the importance of cadaveric gross anatomy and highlight its role in shaping the humanistic perspectives of students in a way that prepares them for the philosophical demands of practicing medicine.

41.

*TAI Dong-Hui, Yu-Ran HEO, Hyun-Ju JI, Kyung-Sik Yoon, Kyung-Seok HU, and Hee-Jin KIM**.** Division in Anatomy and Developmental Biology, Department of Oral Biology, Yonsei University College of Dentistry, Seoul, 03722, South Korea**.**

Ultrasonographic Evaluation of the Facial Muscle Thickness Asymmetry in Asian Adults.

INTRODUCTION. Facial asymmetry is common in anatomical and clinical aspect; however, quantitative reference data on bilateral facial muscle thickness in Asian adults remain limited for the clinical implications. This study evaluated thickness asymmetry of selected facial muscles using ultrasonography (US). METHODS. Twenty healthy Korean and Chinese adults underwent ultrasonographic examination using a high-frequency linear transducer.

continued on next page

On the reproducible three anatomical reference points, bilateral measurements were obtained for the frontalis, zygomaticus major, and depressor anguli oris muscles, respectively. Paired t-tests were performed to evaluate the laterality of the muscle thickness. SUMMARY. Under US images, the average muscle thickness of the frontalis, zygomaticus major and depressor anguli oris were 0.35, 1.57, and 2.55mm, respectively. Bilateral muscle thickness differences were clearly observed from all the volunteers. The muscle thicknesses on the left side were greater than the right side (18 of 20, $p<.05$). CONCLUSIONS. Facial muscle thickness asymmetry were shown in Asian adults, The present findings indicate a tendency toward relatively greater thickness on the left side. These data provide crucial reference that may guide personalized treatment strategies in aesthetic and reconstructive procedures.

42.
*WANG, Michelle J., Jericho ANSAY, Gulseerut GREWAL, Aidan PETTIT-MILLER, Gavin SULLIVAN, Dylan A. WALTEMEYER, and Manuel E. CEVALLOS. School of Medicine, Creighton University, Phoenix, AZ, 85012, USA.

Three in One: Rare Variants of Basilar Artery Branches.

INTRODUCTION. Branches of the basilar artery (BA) supply regions of the brainstem, cerebellum, and cerebrum. Typically, the superior cerebellar arteries (SCAs) and anterior inferior cerebellar arteries (AICAs) arise bilaterally from the BA, with reported prevalence rates of 69-79.5% and 85.5-92.3%, respectively. This report describes an unprecedented case involving a combination of rare BA branch variants (<0.9-5%) and their clinical significance. RESOURCES. During a cadaveric dissection course at Creighton University, twenty cadavers preserved with a 3-9% formaldehyde solution were systematically examined. One 67-year-old male cadaver, with acute hypoxic respiratory failure, aspiration pneumonia, and amyotrophic lateral sclerosis documented as cause of death, exhibited rare anatomical variations of basilar artery branches. Vascular measurements were obtained with a Simhevn digital caliper, with values averaged over three separate measurements to ensure accuracy. DESCRIPTION. One donor exhibited a unique combination of multiple variants in BA branches: duplication of the left SCA, a common trunk of the right SCA with two branches, and duplication of the right AICA. SIGNIFICANCE. Reported prevalence rates in cadaveric studies for bilateral SCA duplication are 0.9-5%, and unilateral AICA duplication are 3.8-7.7%; however, a combination of all three variants in one donor has not been reported in the literature. Documentation of SCA and AICA variants is important for clinical pathologies including trigeminal neuralgia, hemifacial spasm, vestibulocochlear dysfunction, and other neurovascular compression syndromes given proximity of the SCA and AICA with cranial nerves III, IV and VI, VII, VIII, respectively. Awareness of these anatomical variants can significantly improve cerebrovascular disease management, neurovascular surgical interventions, and radiographic interpretation by contributing to the understanding of BA anatomical variations.

43.
* MÉNARD, Arnaud L.[1], Majid DORUDI[1], Matthew I. TINNEY[1] and Manouchehr MADANI CIVI[1].[1]Department of Cellular and Physiological Sciences, University of British Columbia, Vancouver, BC, V6T 1Z4, Canada.

Intraneural Splitting of the Femoral Nerve by the Psoas Major Muscle: Cadaveric Study.

INTRODUCTION. The femoral nerve is the largest branch of the lumbar plexus, originating from the dorsal divisions of the ventral rami of spinal nerves L2-L4. Normally, the femoral nerve descends through the pelvis, between the psoas major and the Iliacus muscles, before passing under the inguinal ligament. It innervates the four heads of the quadriceps femoris muscle, and provides sensory branches to the anterior and medial thigh, as well as the medial aspect of the leg down to the medial side of the big toe. Variations in branching are documented; however, true intraneural penetration by skeletal muscle fibres is exceptionally rare. Such

continued on next page

anomalies may predispose individuals to nerve entrapment, typically presenting with quadriceps weakness that can progress to atrophy in severe cases, along with a diminished or absent patellar tendon reflex. These variants may also represent under-recognized causes of femoral neuropathy when routine spinal imaging is unremarkable. RESSOURCES. This variation was identified during routine cadaveric dissection of a 65-year-old male donor in a university anatomy laboratory to characterize the relationship between the femoral nerve and surrounding musculature. DESCRIPTION. On the right side, 2 cm distal to its formation within the psoas major muscle, the femoral nerve was penetrated by a discrete bundle of muscle fibres. The fibres traversed the nerve without complete fascicular division. The contralateral side showed typical anatomy. SIGNIFICANCE. Although rare, intraneural muscular penetration of the femoral nerve may contribute to anterior thigh pain, quadriceps weakness, or sensory disturbance. Standard lumbar MRI may fail to detect this anatomy, potentially delaying diagnoses. Targeted pelvic MRI or high-resolution musculoskeletal ultrasound may be more appropriate in patients with femoral nerve symptoms. Recognition of this variant is important for anatomists, radiologists, and surgeons to improve diagnostic accuracy and avoid unnecessary interventions.

44.

* SANTHAPPA, Vivin C. A.[1], Juan CHOI[1], Revin J. K. JOSE[1], Shwe Yee WIN MOHT MOHT[1], Sayed Aheed SHAH[1], Michael ADENIYI[1,2], Nansak DASHE[1,2], AND Sadia JAVAID[1,2]. [1]St. George's International School of Medicine, Northumbria University, Newcastle, NE1 8ST, United Kingdom; [2] Department of Anatomy, St. George's University, Grenada, West Indies.

In Vivo Ultrasonographical Architecture of Berrettini Anastomosis and Anthropometric Independence.

INTRODUCTION. The Berrettini anastomosis (BA), a neural communication between median and ulnar common digital nerves, is vulnerable to iatrogenic injury during palmar surgery. Prevalence estimates derive largely from cadaveric studies with wide variability and no in vivo assessment of bilateral architecture or morphometric scaling. Whether BA dimensions are predictable from external anthropometry remains unknown, limiting pre-operative risk stratification. METHODS. One hundred healthy volunteers (200 hands) underwent bilateral high-frequency B-mode ultrasound (GE LOGIQ e, 12L-RS probe). BA presence, width, length, and depth from skin were recorded. Wilson confidence intervals quantified prevalence. Bilateral morphometry was compared using paired t-tests with Cohen's d. Pearson/Spearman correlations and multivariable linear regression assessed associations between BA dimensions and hand length, hand width, height, and BMI. SUMMARY. BA was identified in 176/200 hands (88.0%; 95% CI: 82.8–91.8%), with 95% of participants demonstrating BA in at least one hand and 81% bilaterally. In bilateral participants (n=81), the right BA was significantly wider (0.195 vs 0.152 mm; $p<0.001$; $d=1.09$) and longer (0.290 vs 0.264 mm; $p<0.001$; $d=0.44$), while depth was symmetric ($p=0.128$). Anthropometric correlations were uniformly weak (all $|r|<0.18$), and multivariable models explained <3% of variance, demonstrating dimensional independence from external body size. BMI correlated moderately with depth ($\rho=0.317$; $p<0.001$) but not width or length. CONCLUSIONS. The BA is a near-universal in vivo structure exhibiting consistent bilateral presence yet significant morphometric asymmetry. Its dimensions cannot be inferred from external anthropometry, indicating that surface anatomy does not predict internal neural architecture. These findings challenge assumptions of anatomical proportionality and support individualized pre-operative ultrasound mapping to mitigate iatrogenic nerve injury.

continued on next page

45.
* PAPPAS, Melina, Ian WHITMORE, and Sakti SRIVASTAVA. Division of Clinical Anatomy, Stanford University School of Medicine, Stanford, CA, 94305, USA.

The Classification and Findings of a Rare Digastric Extensor Digitorum Variation: A Case Report.

INTRODUCTION. The extensor digitorum (ED) is commonly known to have variations such as duplicated or split tendons, accessory muscle bellies, and intertendinous interconnections. During routine dissection, a unique bilateral digastric ED tendon to the long finger was encountered. This study aims to present a classification and provide the findings of this extremely rare variation. RESOURCES. Two upper limbs were dissected in routine student dissection to reveal the posterior forearm and hand. Further dissection to remove additional fascia by the investigator revealed the accessory muscle and tendon. After extensive literature review, this variation was vaguely described and never classified. DESCRIPTION. The ED muscle produces a duplicate tendon that connects to a distal supernumerary muscle in the hand. Before entering the extensor hood, the supernumerary muscle transitions back to a tendon. This digastric pattern has rarely been seen in the extensor compartment of the dorsum of the hand before. The proposed classification, Musculus Digatricus Extensor Digiti Medii, was created following the international standard for human anatomical terminology and translates to digastric extensor of the middle finger. SIGNIFICANCE. Description and classification of this variation allow future anatomists, physicians, and surgeons to better identify this variation. Further studies may reveal the prevalence of this variation and aid clinicians in diagnosis and treatment if needed.

46.
* MATTEO, Mika F., Sanjana PRASAD, Martin N. MEDINA, Flora M. HEYDARI, Keira A. PRINCE, Morgan A. MALONE, Leeza-Marie T. WILLIAMS, and Shiv DHIMAN. Department of Bio-Medical Science, Philadelphia College of Osteopathic Medicine, Moultrie, GA, 31768, USA.

Pancytopenia and Myelodysplastic Anemia with Splenomegaly and Bone Remodeling: Cadaver Case Study.

INTRODUCTION. Pancytopenia is a reduction in erythrocytes, leukocytes, and platelets and is commonly associated with myelodysplastic syndromes, bone marrow disorders characterized by ineffective hematopoiesis. Splenomegaly, or pathological enlargement of the spleen, may worsen pancytopenia through sequestration and premature destruction of blood cells. This study examines the relationship between marrow dysfunction, splenic enlargement, and skeletal remodeling observed during cadaveric dissection. RESOURCES. Standard cadaveric dissection techniques were used to isolate thoracic and abdominal cavities. The spleen was identified based on anatomical landmarks, measured, and weighed. The clavicles and sternum were inspected for osseous variation and documented photographically. DESCRIPTION. Dissection revealed marked splenomegaly and exceeding expected dimensions. Three areas of cortical bony elevation were observed along the bilateral clavicles and internal sternum without evidence of trauma. The cadaver's limited medical history was reviewed, revealing pancytopenia and myelodysplastic syndrome in a 65-year-old male. Literature review revealed a study of 22 patients with myelodysplastic syndromes supporting a mechanistic link between marrow dysfunction and skeletal remodeling. SIGNIFICANCE. This case highlights the systemic impact of bone marrow dysfunction, splenic pathology, and osseous abnormalities. Recognition of these interconnected processes emphasizes the importance of integrating hematologic and structural findings in both clinical and anatomical research and may aid clinicians in identifying disease progression, anticipating complications, and guiding more comprehensive patient evaluation. (We acknowledge the generosity of this donor, their family, and PCOM South Georgia, whose contributions to medical education have made this study possible.)

continued on next page

47.

* BARRIENTOS CERNA Lorena Paz, Yu-Ran HEO, Hyewon HU, Hee-Jin KIM. Department of Oral Biology, Human Identification Research Institute, BK21 FOUR Project, Yonsei University College of Dentistry, Seoul, 03722, South Korea.

Zygomaticus Major Changes After Midface HIFES+RF: Ultrasound and Myoton Study.

INTRODUCTION. This study evaluated the clinical efficacy of a non-invasive device combining radiofrequency (RF) and high-intensity facial electrical stimulation (HIFES) technologies for natural facial rejuvenation. The synergistic effect of these two modalities is expected to improve skin elasticity and muscle tone. We performed a comparative analysis focusing on mechanical and structural changes of zygomatic major muscle in the midface. METHODS. A total of 11 healthy volunteers underwent midface using device combining HIFEs and RF treatment targeting the zygomaticus major muscle. One volunteer received 3 sessions with 24-hour follow-up, three volunteers received 5 sessions with 1-month follow-up, and seven volunteers received 2 sessions with 1-week follow-up. Treatments were performed using EMFACE (BTL Industries, Inc., Boston, MA, USA). Applicators were placed bilaterally on the cheeks targeting the zygomaticus major, zygomaticus minor. Ultrasonography and Myoton measurements were obtained before each session, with baseline defined as measurements before the first treatment. Muscle thickness was measured from ultrasonography images using Horos software. Myoton measurements were performed twice each side and averaged. SUMMARY. Ultrasonography analysis demonstrated an overall increase in zygomaticus major muscle thickness after EMFACE treatment, indicating positive structural muscle changes. In contrast, Moton measurements showed a tendency toward reduced tone and stiffness compared to baseline in most volunteers. CONCLUSIONS. These results suggest a dissociation between structural and mechanical muscle responses.

48.

* TURNER, Kaitlyn, Ashlyn PARKHURST, Sarah PAGE-RAMSEY, and Jessica S. BERGDEN. Department of Cell Systems and Anatomy, Long School of Medicine, University of Texas San Antonio Health Sciences Campus, San Antonio, TX, 78229, USA.

Bridging the Gap: A Clinical Pelvic Anatomy E-Learning Tool to Prepare Interns for OB-GYN Residency.

INTRODUCTION. OB-GYN residency program directors have begun to voice a concern that the anatomy knowledge of incoming residents may not be adequate at the start of residency training. There have been several proposed methods, such as 4th-year bootcamps, to address the anatomy knowledge gap of medical students transitioning to residency. However, a lack of standardized, consistent measures exists for evaluating anatomy knowledge readiness for OB-GYN residency across varying medical school preparation methods. RESOURCES. Pelvic laparoscopic images and videos, cadaveric dissection images, diagrams, and interactive quizzing were utilized to create a comprehensive pelvic anatomy learning tool developed in e-learning software. OB-GYN physicians assisted in the development of the clinical case, with diagnostic decision-making required by the user. Labelled images and short narrated videos highlight clinical anatomy necessary for incoming OB-GYN residents. Quizzing features allow self-testing of anatomy knowledge. DESCRIPTION. An interactive digital learning tool reviewing normal and pathological pelvic anatomy, requiring diagnostic decision-making, was developed to help prepare interns for OB-GYN residency. This widely accessible tool allows for consistency across methods of preparing interns to begin residency. The self-assessment feature allows the user to test their own anatomy knowledge as they progress through the learning tool. SIGNIFICANCE. E-learning offers wide accessibility as a teaching tool to bring incoming OB-GYN residents to a uniform and adequate level of anatomy knowledge. The

continued on next page

OB-GYN residency, with its heavy surgical focus, is a prime candidate for the implementation of an anatomy teaching tool targeted towards the highest yield anatomy for the specialty. This could serve as a template for administering a widely accessible, digital teaching tool for other anatomy-focused surgical specialties.

49.

*RICHARDSON, Avery [1], Jason WAGNER [2], Christine VO[3], Lauren ANTHONY [1], and Mary MOON[4].[1]College of Medicine, University of Oklahoma Health Center, Oklahoma City, OK, 73104, USA; [2]Department of Radiologic Sciences, OU Health, Oklahoma City, OK, 73104, USA; [3] Department of Anesthesiology, OU Health, Oklahoma City, OK, 73104, USA; [4]Department of Cell Biology, University of Oklahoma Health Center, Oklahoma City, OK, 73104, USA.

Using the Stomach as an Acoustic Window: Overcoming Air Artifact in Donor Ultrasound.

INTRODUCTION. Point-of-care ultrasound (POCUS) is increasingly integrated into early medical curricula to enhance anatomical understanding and spatial reasoning. While imaging organs such as the kidney, heart, liver, and bladder is relatively straightforward, visualization of the pancreas remains difficult due to its deep retroperitoneal position and overlying gas. These challenges limit effective integration of pancreatic imaging into anatomy education. Donor-based ultrasound training is expanding; however, fixation may degrade image quality by altering tissue properties and introducing intra-abdominal gas. This descriptive study evaluates the feasibility of imaging the pancreas in a soft-fixed donor using direct probe placement on the anterior stomach wall to eliminate air artifact. RESOURCES. A soft-fixed donor was used for all imaging. Standard dissection instruments, including #20 scalpel blades, were used to access the abdominal cavity. Imaging was performed using a GE Logiq V2 ultrasound machine with an L12-6 linear transducer. Water-soluble ultrasound gel was applied directly to tissue surfaces. DESCRIPTION. An incision was made along the costal margin and extended inferiorly through the linea alba to enter the peritoneal cavity. The ultrasound probe was placed directly on the anterior stomach wall with gel to eliminate air interfaces. By bypassing the abdominal wall and bowel gas, the stomach functioned as an acoustic window to the retroperitoneum. This approach improved visualization of the pancreatic body and tail and allowed identification of adjacent structures. Probe manipulation was performed while maintaining direct correlation between sonographic findings and exposed anatomy. SIGNIFICANCE. Direct ultrasound on the anterior stomach wall mitigates common in vivo limitations, including overlying gas and depth. This method enables reliable visualization of the pancreatic body and tail while facilitating immediate imaging–anatomy correlation. It provides a reproducible, cost-effective model for integrating abdominal ultrasound into preclinical anatomy curricula.

50.

* CHANG, Alexander H.[1],Natalia MEJIA[1], Louis HAN[2], Adam WALCHAK[1], and Sameer PATEL[1]. [1]Division of Plastic and Reconstructive Surgery, Fox Chase Cancer Center, Philadelphia, PA, 19111, USA; [2]School of Engineering and Applied Sciences, University of Pennsylvania, Philadelphia, PA, 19104, USA.

Biomechanical Modelling of Breast-Induced Tension on Sternal Incisions.

INTRODUCTION. Many cardiothoracic procedures utilize a vertical midline sternotomy. Sternal wound dehiscence remains a significant source of morbidity. Traditional risk stratification emphasizes diabetes, obesity, smoking, and radiation exposure; however, the mechanical contribution of breast mass to incision tension has not been quantified. We hypothesized that breast mass generates tensile forces across midline incisions that contribute to wound breakdown. The purpose of this study was threefold: (1) to characterize patterns of sternal dehiscence

continued on next page

in females in whom breast mass may represent a risk factor; (2) to develop a biomechanical model to quantify breast-induced tension; and (3) to propose mitigation strategies. METHODS. A biomechanical model was developed to quantify tension under supine conditions. Computed tomography scans were reviewed to obtain sternal-to-lateral chest wall angle, chest contour, circumference, and breast position relative to the midline. Breast mass was estimated using bra size–based volume proxies and soft-tissue density approximations. Measured angles and estimated lateral overhang were used to approximate center-of-gravity displacement and lever-arm distance. A free body diagram and lever-arm mechanics were applied to calculate tensile force along the closure and approximate per-suture tension. SUMMARY. The model permits patient-specific variables to calculate forces of tension along an incision. Larger simulated breast morphologies generated greater distraction forces under similar body habitus conditions, suggesting breast mass and position represent a quantifiable, modifiable mechanical risk factor for wound separation. Proposed mitigation strategies include contralateral taping and development of supportive devices to redistribute forces. CONCLUSIONS. Large breast morphology increases tensile forces across midline sternotomy incisions through predictable biomechanical mechanisms. Quantification of these forces provides a framework for improved risk stratification and targeted mechanical mitigation. Further clinical validation is warranted to determine whether reducing breast-induced tension decreases postoperative wound complications.

51.

* CHANG, Alexander H.,[1] Natalia MEJIA[1], Adam WALCHAK[1], and Sameer PATEL[1]. [1]Division of Plastic and Reconstructive Surgery, Fox Chase Cancer Center, Philadelphia, PA, 19111, USA.

The Anatomical and Clinical Considerations of the Retrorectus Mesh.

INTRODUCTION. The deep inferior epigastric perforator (DIEP) flap is widely used for autologous breast reconstruction because it preserves abdominal musculature while providing reliable soft-tissue replacement. Donor-site hernia and abdominal wall bulge remain significant sources of morbidity. Retrorectus mesh reinforcement has been proposed to mitigate abdominal wall weakness, yet routine use remains controversial due to concerns regarding infection and unclear benefit. The purpose of this study was to quantify donor-site hernia and bulge incidence and determine whether routine retrorectus mesh placement reduces donor-site morbidity. METHODS. A retrospective cohort study was conducted of patients undergoing unilateral or bilateral DIEP flap reconstruction between January 2017 and July 2025 by two microsurgeons using a standardized technique. Patients were stratified into mesh and no-mesh cohorts. The primary outcome was clinically or radiographically diagnosed donor-site hernia or bulge. Secondary outcomes included postoperative complications and donor-site infection. A comprehensive literature review contextualized findings within abdominal wall anatomy and reconstructive outcomes. SUMMARY. A total of 402 patients were included (mesh: 268; no-mesh: 134). Donor-site hernia or bulge occurred in 1.1% of mesh patients versus 20.1% of no-mesh patients, representing a 94% relative risk reduction and 19% absolute risk reduction, with a number needed to treat of 6. Donor-site infection and overall medical complication rates were similar between groups. CONCLUSIONS. Routine retrorectus mesh placement during DIEP flap reconstruction was associated with a significant reduction in donor-site hernia and bulge without increased infection or systemic complications, supporting routine reinforcement to improve abdominal wall integrity and reconstructive durability.

continued on next page

52.

* CHANG, Alexander H.[1],Kye LEE[1], Natalia MEJIA[1], Alex STRATTON[1], Edbert HSU[2], Adam WALCHAK[1], and Sameer PATEL[1]. [1]Division of Plastic and Reconstructive Surgery, Fox Chase Cancer Center, Philadelphia, PA, 19111, USA; [2]Department of Emergency Medicine, Johns Hopkins University, Baltimore, MD, 21287, USA.

Clinical Anatomy of the Peruvian Necktie: Choke Mechanics and the Spectrum of Grappling Submissions.

INTRODUCTION. The Peruvian Necktie is a choke technique in Brazilian Jiu-Jitsu and mixed martial arts involving entrapment of an opponent's head and arm using a figure-four leg configuration to generate compression. Although less common than traditional variations, it is frequently applied during transitional scrambles. Understanding its biomechanics, physiologic effects, and potential injury risks is important for practitioners and ringside medical personnel. RESOURCES. A narrative review was conducted utilizing the clinical literature, competition footage, coaching analyses, and available sports medicine data related to triangle choke variations and other vascular submissions. DESCRIPTION. Proper application combines cervical flexion with hip extension, increasing compressive force through the hamstrings and adductors. Transient loss of consciousness results from reversible cerebral hypoperfusion. Potential complications include cervical strain, laryngeal trauma, brachial plexus compression, and rare vascular injury. Compared with traditional closed-guard triangle chokes, the technique is often initiated from top or transitional positions and requires rapid lower-extity dexterity and positional control. SIGNIFICANCE. From a clinical anatomy perspective, this submission demonstrates how lower-extremity leverage can generate effective carotid compression while maintaining positional dominance. Differentiating vascular chokes from airway obstruction is essential for ringside assessment and athlete safety. Greater integration of biomechanical analysis and medical education may improve referee vigilance, tap recognition, and prevention of prolonged cerebral hypoxia in grappling sports.

53.

* CHANG, Alexander[1], Funiba NGWA[2], Sameer PATEL[1], Adam WALCHAK[1], and Feroz SAAD[3]. [1]Division of Plastic and Reconstructive Surgery at Fox Chase Cancer Center/LKSOM Temple University Hospital, Philadelphia, Pennsylvania, 19111, USA; [2]Lewis Katz School of Medicine at Temple University, Philadelphia, Pennsylvania, 19140, USA; [3]Pediatric Critical Care Medicine at St. Christopher's Hospital, Philadelphia, Pennsylvania,19134, USA.

Diaphragmatic Dysfunction Following Nerve Graft for Brachial Plexus Injury in a 5-Month-Old.

INTRODUCTION. Brachial plexus birth injuries resulting from shoulder dystocia are a well-recognized cause of upper extremity dysfunction in neonates, with nerve grafting serving as an established surgical intervention. Diaphragmatic dysfunction secondary to phrenic nerve involvement represents a rare but serious complication of brachial plexus surgery. This case highlights the anatomical vulnerability of the phrenic nerve during brachial plexus reconstruction and its clinical consequences in a pediatric patient. RESOURCES. Patient chart review, imaging studies, and operative history were analyzed to characterize the clinical presentation and postoperative course. A focused literature review and anatomical review of the cervical roots and phrenic nerve relationships were conducted to contextualize the observed complication. DESCRIPTION. A 5-month-old male was diagnosed with brachial plexus birth injury and presented with severe upper extremity neuromuscular paralysis. Following diagnosis, he underwent a nerve grafting procedure to restore upper extremity function. After surgery, the patient developed respiratory distress and failed extubation, requiring placement on mechanical ventilation. Fluoroscopy demonstrated negligible excursion of the bilateral diaphragms during spontaneous breathing, necessitating continued positive pressure ventilation, consistent with severe bilateral diaphragmatic paresis. The presentation was concerning for inadvertent phrenic nerve injury during brachial plexus grafting, highlighting the intimate

continued on next page

anatomical relationship between the phrenic nerve and the brachial plexus at the level of the cervical roots. SIGNIFICANCE. This case underscores the critical importance of phrenic nerve anatomy in the surgical planning of brachial plexus reconstruction, particularly in pediatric patients where respiratory reserve is limited. It supports routine preoperative and postoperative respiratory monitoring in this population and advocates for heightened anatomical awareness of cervical root contributions to the phrenic nerve during nerve grafting procedures.

54.
* GARDNER, William P., William ZALOGA, Todd GREEN, and Karen POOLE. College of Osteopathic Medicine, New York Institute of Technology at Arkansas State University, Jonesboro, AR, 72401, USA.

Aberrant Left Gastric Vein Discovered in Cadaver Dissection: Clinical and Physiological Associations.

INTRODUCTION. The aberrant left gastric vein (ALGV) is an anatomical variation in which the left gastric vein directly enters the liver at a site separate from the hepatic portal vein. ALGVs are rare (0.06-0.8% prevalence) and have surgical, imaging, and physiological significance such as hepatic fat sparing and atrophy in areas supplied only by the left gastric vein. Clinically these manifestations can present as pseudolesions on arterial portography and have been mistaken as neoplasms in cancer patients, leading to misdiagnosis and unnecessary treatments. METHODS. Standard anatomy laboratory dissection tools were used in the discovery and biopsy. Standard H&E stain and mounting protocol were used for histology. SUMMARY. An ALGV was found in a 70-79-year-old male cadaver during routine dissection. This ALGV travels along the lesser curvature of the stomach and enters the liver to the left of the hepatic portal vein. A frontal slice through the liver revealed the ALGV travels anteriorly within the liver approximately 15 mm then anastomoses with the intrahepatic portal venous system and is therefore classified as a type III ALGV. This person had been diagnosed with pancreatic cancer premortem. Upon dissection, widespread nodules were found within the abdominal fascia and the greater and lesser omentum,. The frontal slice of the liver revealed a nodule grossly similar to those found nearby at the site of entry of the ALGV, as well as a high concentration of nodules around the gastroesophageal junction. H&E staining revealed highly undifferentiated cells within the periportal nodule as well as in section III of the liver, both matching the undifferentiated cells found at the GE junction. A biopsy of section VII did not contain any identified cell differentiation. Also found in all biopsied sections of the liver was microsteatosis and bile stasis surrounding the central veins within hepatic lobules. These nodules and their close proximity of the ALGV lead us to hypothesize that its presence played a role in the grossly visible metastases throughout the upper gastrointestinal tract and thoracic cavity. CONCLUSIONS. ALGVs have a complex interplay with physiology, imaging, and surgery. While they are uncommon, they should be considered when treating patients with upper GI symptoms.

55.
* PEREZ BRUNO, Jenny, Brianna BHOOPSINGH, and Ramona BAEZ. College of Osteopathic Medicine, Touro University ,Harlem, NY, 10027, USA.

Complex Multi-Bellied Accessory Abductor Pollicis Longus with Distal Tendon Fusion: A Case Report.

INTRODUCTION. The abductor pollicis longus (APL) demonstrates anatomical variability, most commonly involving multiple tendon slips within the first dorsal compartment (FDC). Accessory muscle bellies (AAPL) with complex distal fusion patterns are less frequently described, but are clinically significant due to their association with FDC pathology and surgical interventions. The purpose of this study was to document and characterize a rare configuration of medial & lateral accessory APL muscle bellies identified during dissection. RESOURCES. Routine anatomical dissection of the posterior compartment of the forearms was performed on an embalmed 86 y/o Caucasian female donor. Variations of the AAPL were documented, measured using a digital caliper, and

continued on next page

photographed. DESCRIPTION. In addition to the primary APL muscle, distinct medial & lateral accessory muscle bellies were identified on the left forearm. The lateral accessory components consisted of two muscle bellies measuring 46.52 mm and 67.35 mm in length, respectively, attaching superficially to the primary APL. Distally, these fibers converged to form a well-defined tendon measuring 40.85 mm x 6.22 mm, inserting at the base of the first metacarpal with distal fusion in the FDC. The medial accessory belly measuring 64.42 mm × 4.76 mm shared fibers with the extensor pollicis brevis & formed a 22.85 mm tendon fused along the medial aspect of the primary APL tendon, prior to insertion. This configuration created a complex tendinous architecture before insertion at the base of the first metacarpal. SIGNIFICANCE. Recognition of multi-bellied APL variants with distal tendon fusion and fiber sharing with the extensor pollicis brevis is clinically important for surgical decompression of the FDC and other reconstructive hand procedures. Such anatomical complexity also contributes to persistent De Quervain's tenosynovitis and influences surgical planning to avoid incomplete release or iatrogenic injury.

56.

* RUBINSTEIN, Sarah J., Thanisorn SAENGTORNGPINIJ, Pran PRAPHNPHOJ, Ayana FURUKAWA, Bharatsinai PEDDI, Sadia JAVAID, Haider HILAL, Tarek ALMABROUK, and Chinedu ENWEREM. Department of Anatomy, St. George's University, Grenada, West Indies.

Ultrasound Assessment of the Peroneus Quartus Muscle and its Significance in Peroneal Tendinopathy.

INTRODUCTION. The peroneus quartus (PQ) is an accessory lateral ankle muscle linked to peroneal tendon pathology. It typically arises from fibularis brevis and inserts onto the lateral calcaneus or retinaculum, potentially crowding the retromalleolar groove and altering tendon biomechanics. PQ has been associated with fibularis brevis split tears, tenosynovitis, and chronic lateral ankle instability. Reported prevalence ranges from 12–22% and may vary by ethnicity. This study used high-frequency ultrasound to determine PQ prevalence in healthy young adults of East and South Asian ethnicity and to assess associations with clinical factors related to peroneal tendinopathy. METHODS. Fifty-two young adults underwent bilateral lateral ankle ultrasound using a high-frequency linear transducer to identify PQ and laterality. Participants provided demographic data and completed questionnaires on activity level, ankle sprain history, and lateral ankle pain. Associations between PQ presence and clinical variables were analyzed. RESULTS. Participants had a mean age of 22.8 ± 3.9 years (30 males, 22 females). PQ was identified in 6 individuals (11.5%): 3 unilateral (1 left, 2 right) and 3 bilateral. Ankle sprain history was reported by 66.7% of PQ-positive participants versus 43.5% of PQ-negative participants. Lateral ankle pain was reported by 0% of PQ-positive and 4.3% of PQ-negative participants. Physical activity <150 min/week was reported by 50.0% of PQ-positive and 39.1% of PQ-negative participants. No significant differences in age or BMI were found between groups. CONCLUSIONS. PQ was detected by ultrasound in ~11% of this cohort. PQ presence was not significantly associated with ankle pain, sprain history, activity level, or anthropometrics. High-frequency ultrasound is a low-cost, accessible method for identifying PQ. Larger, ethnically diverse studies with standardized imaging are needed to clarify its clinical relevance.

continued on next page

57.
* NORRIS, Brett J., Tyler GALLAGHER, and Sara SLOAN.Department of Anatomical Sciences, College of Osteopathic Medicine, Kansas City University , Kansas City, MO, 64106, USA.

The Tensor Vastus Intermedius and its Association with Altered Meniscal Morphology.

INTRODUCTION. The Tensor Vastus Intermedius (TVI) is an accessory quadriceps muscle first discovered in 2016. While its prevalence and morphology have been examined both in vivo and in cadaveric specimens, its impact on surrounding musculature and knee structures remains poorly understood. This study compares meniscus thickness and surface area in cadaveric specimens with and without a TVI. METHODS. Twenty-seven cadavers (54 limbs) were dissected, and anterior musculature was examined to determine TVI presence, verified by two researchers. Medial and lateral menisci were dissected from the same limbs, and thickness and surface area were measured at the anterior, posterior, and midbody using digital calipers. All statistical analyses were conducted in Python® (v3.x). SUMMARY. Sixteen TVI muscles were identified in 11 cadavers, with a prevalence of 29.6%. TVI presence was associated with decreased meniscal dimensions. The strongest association was with decreased medial meniscus thickness ($r = -0.605$, $p = 0.0008$). Additional negative correlations were observed for medial midbody thickness and anterior horn thickness; however, these did not remain significant in multivariable analysis. Altogether, this study identifies a correlation between TVI presence and altered meniscal morphology. As the TVI lies laterally in the anterior thigh, its presence introduces asymmetry to the extensor mechanism of the knee. This asymmetry may affect knee tracking and meniscal loading – potentially contributing to changes in meniscus thickness over time. While our findings suggest a plausible relationship, additional biomechanical analysis is needed to clarify the mechanisms linking TVI presence and meniscus morphology. CONCLUSIONS.TVI presence was associated with decreased medial meniscus thickness, and a decreased anterior horn thickness of the lateral meniscus. These findings suggest a relationship between TVI morphology and knee joint mechanics. Larger datasets and additional biomechanical testing are warranted to further analyze this relationship.

58.
* BAE, Hope[1], Brian BUCHANAN[1], Francesco LITTLE[1], Garrett WEGH[1], Beneshia ROBINSON[1], Brenna HART[2], and Christian HECK[2]. [1]College of Osteopathic Medicine, Pacific Northwest University of Health Sciences, Yakima, WA, 98901, USA; [2]Department of Anatomy, College of Osteopathic Medicine, Pacific Northwest University of Health Sciences, Yakima, WA, 98901, USA.

Untreated Subtrochanteric Malunion in an Anatomical Donor: A Case Report.

INTRODUCTION. The femur is critical for weight bearing, stability, and mobility, making femoral fractures serious orthopedic injuries. Consequently, very few studies describe their healing progression without medical intervention. Subtrochanteric fractures are especially unstable due to high biomechanical stress and strong muscular forces that can significantly alter alignment during healing. Here, we explore the anatomical compensation and malunion following a subtrochanteric fracture without medical intervention in an unusual femur of a donor body. RESOURCES. We compared differences in the size and shape of the left and right femurs of a 76-year-old male donor with an unknown cause of death. Specifically, we measured femur length; circumferences of the metaphysis, diaphysis, and epiphysis; and overall lower extremity length. Using a goniometer, we measured the angle of the lateral femoral longitudinal axis at the site of the bony lesion. DESCRIPTION. The left femur exhibits an abnormally elongated neck with bony outgrowths and a posterior rotation of the proximal diaphysis. Two bony outgrowths are present along the neck of the femur – one posterior and one anterior. Morphological changes to the femoral neck are hypothesized to be a compensatory mechanism in response to a subtrochanteric femoral fracture that went untreated. Further, the pathologic left femur showed

continued on next page

a significant difference in length compared to the right. SIGNIFICANCE. This case highlights the structural consequences of an untreated subtrochanteric femoral fracture. Investigation of untreated femoral fractures improves understanding of natural bone remodeling, compensatory musculoskeletal and vascular adaptation, and the functional impact of malunion. This knowledge may inform management of delayed presentations occurring in rural or medically underserved communities and contributes perspective to bone remodeling following biomechanical disruption.

59.

* PEACE, Andrew W.[1], Brandon R. SNYDER[1], Nathan WILLIAMS[2], and Spencer MATTINGLY[3]. Department of Clinical Education, Burrell College of Osteopathic Medicine, Las Cruces, NM, 88001, USA; [2]Department of Preclinical Medicine, Burrell College of Osteopathic Medicine, Las Cruces, NM, 88001, USA; [3]Department of Anatomy, Burrell College of Osteopathic Medicine, Las Cruces, NM, 88001, USA.

Efficacy and Cost-Benefit Ratio of Real Tissue Adjuncts in Surgical Procedural Training.

INTRODUCTION. Within anatomy education and surgical skills training, the use of human cadaveric models has long been considered the “gold standard”. However, cadaveric materials can often be prohibitively expensive. Adjunct models may offer a cheaper alternative but often lack anatomical detail. Animal tissue has long been used as a substitute for human tissue in biomedical research and may similarly prove useful in surgical skills training. This study compared three teaching adjunct types – cadavers, porcine tissue, and self-constructed (DIY) anatomical models – for perceived utility and cost in thoracostomy training. METHODS. Second-year medical students completed a pre-instruction survey to evaluate procedural comfort with tube thoracostomy using a Likert scale. Students performed chest thoracostomies on a cadaver, a porcine thorax, and the DIY model, rating each on anatomic accuracy, tissue feel, ease of practice, and sensory acceptability. SUMMARY. Data analysis demonstrated no significant difference in student experience between the porcine and cadaveric models ($p = 0.488$), but significant differences were observed when comparing the DIY model to both ($p < 0.001$ each). No significant difference was found in procedural confidence between porcine and cadaveric sessions ($p > 0.999$), indicating no order bias. CONCLUSIONS. Porcine models were viewed as favorably as cadaveric for thoracostomy training. Given the significant cost difference, porcine models may represent a highly cost-effective adjunct in surgical training. In contrast, DIY anatomical models, while still considered useful, do not supply the same level of realism or quality as real tissue counterparts, and are therefore only recommended as a last resort.

60.

* HERNANDEZ, Abraham, Jasmyn A. LOPEZ, Madison E. BROWN, and Beth HABELOW. Stanford University School of Medicine, Division of Clinical Anatomy, Stanford CA, 94305, USA.

Anatomy-Based Health Education: Effects on Adolescents’ Health Knowledge, Beliefs, and Motivation.

INTRODUCTION. Adolescence is a critical period for the development of lifelong health behaviors, yet many adolescents have limited understanding of how lifestyle choices affect physiological health. This study evaluated whether an anatomy-based health education session could influence high school students’ health knowledge, beliefs about the relationship between lifestyle choices and physiological outcomes, and motivation to engage in positive health behaviors. METHODS. High school students ages 15–17 participated in a two-hour anatomy-based health education session consisting of three components: mental health, nutrition and physical activity, and substance use (smoking/vaping, alcohol, and drugs). Human anatomical specimens related to each component were presented to demonstrate relevant structures, and illustrate the effects of healthy and unhealthy behaviors through the comparison of normal and pathological specimens. Students completed anonymous pre- and post-

continued on next page

session surveys containing five-point Likert scale and free response questions to assess health knowledge, health beliefs, and motivation. Composite scores were calculated for each domain by averaging responses to related survey items, and paired analyses compared pre- and post-session responses. SUMMARY. Among 70 participants, significant improvements were observed across all domains. Health knowledge increased (mean difference = 0.693, $t(69) = 9.90$, $p < 0.001$), belief in the connection between lifestyle choices and physiological health increased (mean difference = 0.300, $t(69) = 4.38$, $p < 0.001$), and motivation to engage in healthy behaviors increased (mean difference = 0.500, $t(69) = 5.92$, $p < 0.001$). CONCLUSIONS. Anatomy-based health education may improve adolescents' understanding of health behaviors and strengthen motivation to adopt healthier lifestyles by linking behavioral choices to observable physiological outcomes. These results highlight the potential value of incorporating anatomy-based instruction into new or existing health education programs for adolescents.

61.

* KARAPANON, Sorasit[1], Jutharat SIRIDONTHANAKASEM[2], Suphatsorn HATHAIDECHADUSADEE[1], Ratchathorn NAKABUT[1], Natcha CHAIBURANONT[1], and Jiraroch MEEVASSANA[1,2]. [1]Department of Anatomy, Faculty of Medicine, Chulalongkorn University, Bangkok, 10330, Thailand; [2]Division of Plastic and Reconstructive Surgery, Department of Surgery, Faculty of Medicine, Chulalongkorn University, Bangkok, 10330, Thailand.

Morphometry of the Platysma and Anterior Jugular Vein: Applications for Targeted Neck BoNT Injection.

INTRODUCTION. Botulinum toxin (BoNT) injection into platysma muscle could reduce the platysmal bands and horizontal neck lines. The procedure carries inherent risk due to variations of the nearby structures. Common complications include hematoma from the rupture of anterior jugular vein (AJV), while excessive depth of BoNT diffusion can result in dysphonia and dysphagia. Despite the rising popularity of aesthetic interventions, standardized anatomical safety margins remain poorly defined. This study aims to establish a safe injection zone by quantifying the topographical relationship between the medial platysma border, AJV, and midline of thyroid cartilage. METHODS. Fifty-nine embalmed Thai cadaver (30 men and 29 women) were dissected to expose the platysma between the mandible and clavicle, revealing structures medial to platysma borders including AJV and thyroid cartilage. Distance from medial border of platysma to midline of thyroid cartilage, left and right AJV to platysma, and AJV to midline of thyroid cartilage were measured by a digital Vernier caliper. Types of AJV were classified according to unilateral and bilateral presence. SUMMARY. Mean distances between the medial platysma border and AJV were 0.5 ± 0.4 cm on the right side and 0.5 ± 0.5 cm on the left side. The medial border of the platysma was located at a mean distance from the thyroid cartilage of 1.3 ± 0.6 cm on the right side, and 1.4 ± 0.6 cm on the left side. The thyroid cartilage to the right and left AJV averaged 0.9 ± 0.7 cm and 1.1 ± 0.8 cm, respectively. 67.80% of cadavers exhibit bilateral presence of AJV. CONCLUSIONS. The significant proximity of AJV to medial platysma border and the high prevalence of bilateral venous structures establish a narrow safety margin for BoNT delivery. To mitigate risks of hematoma and excessive diffusion, potentially resulting in dysphagia or dysphonia, injections should be performed superficially within intradermal or subcutaneous layers, avoiding excessive medial placement. These findings highlight the need for patient dynamic assessment before the procedures to ensure efficacy and safety of the interventions.

continued on next page

62.
* HELGESON, Tianna M., and Caroline ROWE. Department of Integrative Biology and Physiology, University of Minnesota Twin Cities, Minneapolis, MN, 55414, USA.

A Histological Characterization of the Paraurethral Glands in Four Uterine-Bodied Donors.

INTRODUCTION. The paraurethral glands, an integral component of the clitourethrovaginal (CUV) complex, have remained an elusive structure in anatomical literature since their discovery over three centuries ago. Because these glands share a common embryonic origin with the prostate, they are thought to be functionally similar and are commonly known as the 'female prostate.' Although initially believed to be vestigial, previous studies have implicated the glands in the secretion of prostate-specific antigen (PSA) and prostatic acid phosphatase (PAP). Furthermore, it has been hypothesized that their secretory cells release antimicrobial and antifungal by-products, such as zinc. Disagreements exist in the medical literature regarding the histological characterization of the glands, with previous reports finding simple columnar, pseudostratified columnar, cuboidal, and moderately tall cylindrical cells. The glands' prevalence, arrangement, and secretory capabilities are also heavily debated. Our preliminary study aimed to characterize the paraurethral glands via detailed dissection and histological analysis. METHODS. We obtained four unpreserved postmenopausal CUV complexes from donors aged 59–90+. The CUV complexes were dissected en bloc sliced in the sagittal or coronal plane, fixed, dyed with hematoxylin and eosin (H&E) staining and examined using bright light microscopy. SUMMARY. Glandular structures, recognized as the paraurethral glands, were observed flanking the urethra in all four CUV complexes sampled. These structures were lined by simple and stratified cuboidal epithelia, which suggests a highly protective and selective function. CONCLUSIONS. Further research into the secretory function of the gland within the larger CUV complex must be conducted to confirm these results. (Sponsored by Undergraduate Research Opportunities Program Grant No. 11720 from the Office of Undergraduate Research.)

63.
* CRAWFORD, Kayla E.[1], Krystal M. LOZIER[1], Thornton A. MARDIS[1], and Anthony B. OLINGER[1].[1]Department of Pathology and Anatomical Sciences, Kansas City University, Kansas City, MO 64106, USA.

Ultrasound Presets for Abdominal Wall Thickness: A Cadaveric Validation Study.

INTRODUCTION. Appropriate trocar length selection is essential for safe laparoscopic entry and maintenance of pneumoperitoneum. Trocar choice is often based on estimation rather than patient-specific abdominal wall thickness. Point-of-care ultrasound offers a non-invasive method to assess abdominal wall thickness preoperatively; however, it remains unclear whether abdominal or musculoskeletal/soft tissue presets provide more reliable measurements. The purpose of this study was to determine which ultrasound preset more accurately estimates abdominal wall thickness compared to direct measurement. METHODS. Abdominal wall thickness was measured at standard laparoscopic port sites in formalin-fixed cadavers using a high-frequency linear transducer with both abdominal and musculoskeletal/soft tissue presets. Skin-to-peritoneum distance was recorded for each preset. Following imaging, careful dissection was performed and digital calipers were used to obtain direct measurements at the same sites. Ultrasound measurements were compared to caliper measurements to assess accuracy and reliability. SUMMARY. Both presets demonstrated correlation with direct measurements; however, differences in measurement consistency were observed between presets. Variability in abdominal wall thickness across sites supports individualized assessment rather than estimation alone. These findings suggest that preset selection may influence measurement reliability during preoperative planning. CONCLUSIONS. Point-of-care ultrasound is a viable method for estimating abdominal wall thickness at standard trocar sites. Selection of an appropriate imaging preset may improve accuracy of trocar length planning and support safer laparoscopic access.

continued on next page

68.

* LABIB, Mark[1] and Maikel MEKHAEIL[1], Nayan BANSAL[1], Maria HABASHY[1], George KALAD[1], Chukwuebuka ORKIAKO[1], Tarek ALMABROUK[1], Henry OKODASO[1].[1]St. George's University School of Medicine, West Indies, Grenada; Northumbria University, Newcastle upon Tyne, Tyne and Wear, NE1 8ST, United Kingdom.

Early Recovery of Carotid Arterial Strain Post Acute Exercise Using Conventional B-Mode Ultrasound.

INTRODUCTION. Acute changes in carotid arterial mechanics during physiological stress are typically assessed using automated wall-tracking systems. However, the feasibility of detecting vascular recovery kinetics using conventional B-mode ultrasound measurements remains unclear. This study aimed to investigate time-dependent changes in carotid strain following high-intensity dynamic exercise using standard B-mode ultrasound. METHODS. Healthy adults (n = 44; n = 41 analyzed) underwent ultrasound imaging of the right distal common carotid artery at rest, immediately post-exercise, and during recovery at 3 and 5 minutes following high-intensity exercise (≥75% age-predicted maximal heart rate). End-diastolic (Dd) and peak systolic (Ds) diameters were measured using B-mode ultrasound, and carotid strain was calculated as (Ds – Dd)/Dd. Repeated-measures ANOVA evaluated temporal changes, and regression analyses assessed associations with demographic and cardiometabolic variables. SUMMARY. Carotid strain increased significantly from rest (0.124 ± 0.041) to immediately post-exercise (0.167 ± 0.054, $p < 0.001$) and remained elevated at 3 minutes of recovery (0.165 ± 0.050, $p < 0.001$ vs. rest). Partial recovery was observed at 5 minutes (0.152 ± 0.049) although values remained significantly higher than baseline ($p<0.001$). A significant reduction from peak was observed only at 5 minutes ($p = 0.038$). Resting pulse pressure was positively associated with resting carotid strain ($r = 0.49$, $p = 0.001$), and peak pulse pressure correlated with peak strain ($r = 0.41$, $p = 0.008$). No significant sex-based differences in strain or recovery were observed. CONCLUSION. Conventional B-mode ultrasound can detect acute exercise-induced changes in carotid arterial strain and early recovery dynamics. The persistence of elevated strain during recovery suggests sustained vascular effects following high-intensity exercise. This accessible imaging approach may have utility in assessing arterial function and cardiovascular risk in both clinical and research settings.

69.

* ABDALLAH, Fares[1], Aaliya PATHAN[1], Akshaya Ganesh BABU[1], Yuktha SABHNANI[1], Muhammad Ismail Faisal KHANANI[1], Malek FARJALLAH[1], Tarek ALMABROUK[1], Sadia JAVAID[1]. [1]St. George's International School of Medicine, Northumbria University, Newcastle, NE1 8ST, United Kingdom.

Ultrasound Evaluation of APL Tendon Thickness, Tendon Sheath Diameter, and Peritendinous Fluid in Relation To BMI, Age, Hand Dominance, and Repetitive Hand Activity for Reconstructive Surgery Graft Selection and Preoperative Planning.

INTRODUCTION. The abductor pollicis longus tendon (APL) originates from the posterior surfaces of the radius and ulna and inserts on the base of the first metacarpal, functioning primarily to abduct the thumb. Its structure and accessibility make it a common graft in reconstructive surgeries, including tendon transfers and ligament reconstructions. Despite its clinical importance, literature describing how lifestyle factors influence APL morphology remains limited. Understanding activity-related variation in APL structure can aid in preoperative planning and graft selection. METHODS. To investigate the effects of certain factors, 100 participants, 50 male and 50 female, were tested between the ages of 18–52 with BMI ranging from 16.25–36.36 kg/m^2. Bilateral APL ultrasounds were performed using GE LOGIQ ultrasound with the hand upright and fully extended. Variables such as APL tendon thickness, tendon sheath diameter, and peritendinous fluid in relation to body mass index (BMI), age, hand dominance, and repetitive hand activities (sports participation, writing, musical instrument use, and gaming) were recorded to assess how mechanical loads contributes to tendon structural differences relevant to surgical applications. Associations with demographic variables and activity patterns were analyzed

continued on next page

using correlation and regression models. SUMMARY. The results have shown that sports participation emerged as an independent predictor of increased APL tendon thickness, while BMI and instrument playing demonstrated borderline associations. Hand dominance, age, and writing duration were not a significant determinant of tendon morphology. Tendon thickness and sheath diameter were strongly correlated, suggesting linked adaptive or pathological remodeling. CONCLUSIONS. APL tendon morphology is more strongly influenced by mechanical load particularly sports participation, instrument used, and body mass rather than hand dominance or low-intensity repetitive tasks such as writing. These findings support a load-adaptation or early overuse mechanism detectable by ultrasound and provide clinically relevant insight for reconstructive procedures utilizing the APL tendon.

70.

* MARDIS, Thornton A.[1,2], Kayla E. CRAWFORD[1,2], Ryan A. MOON[1], Sara S. SLOAN[2], and Hana HAMDAN[2]. [1]Kansas City University College of Osteopathic Medicine, Kansas City, MO, 64106, USA; [2]Department of Pathology and Anatomical Sciences, Kansas City University, Kansas City, MO, 64106, USA.

Comparing Coronary Atherosclerosis and Hepatic Steatosis: A Cadaveric Study.

INTRODUCTION. Metabolic dysfunction-associated steatotic liver disease (MASLD) is increasingly appreciated as a multisystem condition closely associated with insulin resistance, obesity, type 2 diabetes mellitus, and cardiovascular disease, the leading cause of death in this population. Although it is a primary liver disease, MASLD reflects a broader metabolic and inflammatory milieu that promotes vascular pathology. Accumulating evidence suggests that shared mechanisms such as insulin resistance, systemic inflammation, and endothelial dysfunction drive both steatohepatitis progression and atherogenesis. METHODS. Formalin-embalmed cadavers were dissected. A standardized 1 cm2 section of liver parenchyma was harvested from Couinaud segment VII, and a segment of the left anterior descending (LAD) artery was excised approximately 1 cm distal to its origin from the left coronary artery. Liver and LAD samples were fixed, paraffin-embedded and sectioned using standard histologic protocols. Liver tissue underwent hematoxylin and eosin staining. MASLD severity was graded using Nonalcoholic Fatty Liver Disease Activity Score (NAS) by light microscopy. Correlative analyses were performed to assess the relationship between hepatic NAS and coronary plaque burden. SUMMARY. This study investigated the relationship between steatohepatitis severity and atherosclerotic plaque burden within the LAD artery to better characterize the liver-heart axis and its structural manifestations in advanced metabolic disease. CONCLUSIONS. This study did not demonstrate a significant correlation between steatohepatitis severity and coronary atherosclerotic plaque burden in this cadaveric sample. These findings suggest that the relationship between MASLD and cardiovascular disease may not be directly reflected by parallel histopathologic severity in liver and coronary arteries, and that additional systemic or temporal factors may contribute to cardiovascular risk in this population.

71.

*BRADLEY, A. Taylor, Thornton A. MARDIS, Anthony B. OLINGER, and Jonathan T. LEO. Kansas City University, 1750 Independence Ave. Kansas City, MO, 64106, USA.

Aberrant Subclavian Artery and Unique Vertebral Artery Origin - A Unique Aortic Arch Variant.

INTRODUCTION: This case report presents a 79-year-old female donor with an unreported anomaly of the aortic arch. The aortic arch lacks a brachiocephalic trunk, has an aberrant right subclavian artery (RSCA) which originates near the descending aorta which then travels posterior to the trachea as it approaches the upper extremity, and a right vertebral artery (RVA) originating from the right common carotid artery. Previous literature states the incidence of an aberrant RSCA alone being .5 -2%, while the occurrence of an abnormal RVA alone

continued on next page

being .18%. The incidence of these two anomalies together is not known. The relevant medical history for this patient was high blood pressure and an unknown heart murmur. Cause of death was pulmonary hypertension. While the cause of death and history are limited, they could be linked to the underlying anomaly. RESOURCES: Cadaveric donor from the KCU gift body program.

72.
* CHINEN, Doulton R., Cara L. FISHER, Matthew J. KLING, Erin C. BLANKENSHIP-SEFCZEK, and Ethan SCHROEDER. Department of Oral Biology, School of Dentistry, Creighton University, Omaha, NE, 68102, USA.

A Comparison of Osteoarthritis in the Temporomandibular and Distal Interphalangeal Joints.

INTRODUCTION. Osteoarthritis (OA) is a complex chronic joint disease involving degeneration of articular cartilage, subchondral bone, and adjacent tissues, often affecting multiple joints in an individual. This study aimed to determine whether OA severity and spatial wear patterns are concordant across joints with distinct biomechanics and ossification processes by comparing the temporomandibular joint (TMJ) and the distal interphalangeal joint (DIPJ). While most OA studies rely on imaging, cadaveric dissection enables direct assessment of articular surface wear and subchondral changes. METHODS. Twenty TMJs and DIPJs from ten cadaveric donors were dissected to determine degeneration severity and the distribution of osteoarthritic wear on the mandibular condyle, glenoid fossa, head of the middle phalanx, and base of the distal phalanx. Lesions were graded using a validated disease severity scale, and wear location was categorized into three zones per surface. Age, sex, and sidedness were included as covariates. Two mixed-effect models were used to evaluate osteoarthritic changes. SUMMARY. The head of DIPJs demonstrated the highest predicted probability of severe OA. Individuals aged 76-85 showed the greatest probability of severe OA across all joint surfaces, whereas individuals younger than 75 were more likely to exhibit moderate OA. Spatially, the central regions of the mandibular condyle and radial surface of the DIPJ head showed the highest probability of OA presence, compared to all other observed surfaces. CONCLUSIONS. OA severity and spatial wear patterns differ between the TMJ and DIPJ, reflecting joint-specific biomechanics and developmental processes. Cadaveric analysis provides detailed characterization of articular degeneration not captured by imaging and may help clarify mechanisms underlying joint-specific OA progression.

73.
* LOAIZA, Giraldo, Jessica Paola[1], José J. VALENZUELA[2], Juan SANCHIS-GIMENO[3], Matías ORELLANA[4] and, Pablo NOVA[5]. [1]School of Medicine, Universidad Central del Valle del Cauca, Tuluá, Colombia; [2]Department of Anatomy, Universidad de Chile, Santiago, Chile; [3]Department of Anatomy and Human Embryology, University of Valencia, Valencia, Spain; [4]Faculty of Medicine, Universidad de los Andes, Santiago, Chile; [5]Faculty of Medicine, Pontificia Universidad Católica de Chile, Santiago, Chile.

Posterior Cerebral Artery Variants: A Systematic Review and Meta-analysis.

INTRODUCTION. Morphological variants of the posterior cerebral artery (PCA) influence posterior circulation hemodynamics and may affect cerebrovascular risk and neurointerventional planning. Reported prevalence varies widely across anatomical and imaging studies. This study aimed to quantify the prevalence of PCA variants and summarize their anatomical patterns. METHODS. A systematic review and meta-analysis was conducted in accordance with PRISMA 2020 guidelines and registered in PROSPERO. MEDLINE, Scopus, Web of Science, CINAHL, LILACS, and Google Scholar were searched from inception to December 2025. Studies reporting PCA variants using imaging or cadaveric methods were included. Risk of bias was assessed using the AQUA tool. Pooled prevalence estimates were calculated using a random-effects model. SUMMARY. Fifty-two studies (10,537 individuals) were included, with 15 studies (8,418 individuals) contributing to meta-analysis. The pooled

continued on next page

prevalence of PCA variants was 18% (95% CI: 10–25%), with substantial heterogeneity (I^2=98.2%), reflecting methodological variability across studies. Imaging-based studies reported higher prevalence (20%) than cadaveric studies (10%). Hypoplasia (14%) and aplasia (4%) were the most common variants, while duplication (1%) and fenestration (0.6%) were rare. Publication bias was detected. CONCLUSIONS. PCA variants are common but highly heterogeneous across studies and methodologies. Reported estimates should be interpreted with caution, as pooled results may overestimate population-level prevalence. Standardized anatomical definitions and prospective studies integrating imaging and clinical outcomes are required.

74.
* SON[1,2], Ji-Young and Seung-Ho HAN[1,2]. [1]Department of Anatomy, College of Medicine, Ewha Womans University, Seoul, 07804, South Korea; [2]Ewha Medical Academy, Ewha Womans University Medical Center, Seoul, 07804, South Korea.

Topographical Analysis of Arterial Perforators in the Face: A Cadaveric Study.

INTRODUCTION. Arterial perforators in the face are clinically significant in plastic surgery; however, comprehensive anatomical data are limited. The aim of this study was to investigate the number, diameter, and topographic distribution of arterial perforators in the face with a diameter of 0.5 mm or greater, regarded as clinically suitable donor vessels for flap transplantation. METHODS. Seven cadavers (14 hemifaces; mean age, 80.3 years) were examined using micro-computed tomography combined with dissection. The number and average diameter at the origin of each perforator were recorded, and their locations were mapped based on the Frankfort horizontal plane and a vertical line through the porion. SUMMARY. A total of 134 perforators were identified from 7 major arteries: the main trunk of the facial artery, the submental artery, the lateral nasal branch of the facial artery, the transverse facial artery, the anterior auricular branch of the superficial temporal artery, the zygomaticoorbital artery, and the frontal branch of the superficial temporal artery. The main trunk of the facial artery exhibited the greatest number of perforators (number, 47; prevalence, 100%; average per hemiface, 3.4), and the largest mean diameter (1.01 ± 0.34 mm). In the heat map from perforator coordinates, the frontal branch of the superficial temporal artery demonstrated the widest dispersion, with a projected area of 22.7 cm^2. However, the lateral nasal branch of the facial artery exhibited the highest density of coordinates at 4.8 per cm^2. Perforators originating from the facial artery and the transverse facial artery showed distinct distribution patterns relative to a horizontal line passing through the subnasale, suggesting that this line may be used as a reference in facial flap design. CONCLUSIONS. A comprehensive analysis of arterial perforators in the face was conducted in this study, providing quantitative and visualized data that may inform medical procedures of the face.

POSTER SESSION 2 – SATURDAY, JUNE 13 FROM 2:00 PM - 3:15 PM

75.
*GHAFARI, Daniella, Allison LEONARD, Nicholas MORALES, Marc TITSWORTH, Jake FOGEL, Aakriti SINGLA, and Malli BARREMKALA. Oakland University William Beaumont School of Medicine, Rochester MI, 48309.

From Foramen to Fragment - A Study of the Persistent Suprahyoid Thyroglossal Duct.

INTRODUCTION. Persistent thyroglossal duct tissue extending to the hyoid bone influences surgical planning for thyroglossal duct cyst (TGDC) excision. This case report examines the prevalence of this anatomical variant and explores its potential implications for surgical management. RESOURCES. Dissection of the neck was performed as part of a medical student gross anatomy lab course. Anatomical variation of the thyroglossal duct was documented photographically. The incidence of this finding was assessed across a total of 23 donors (12 male, 11

continued on next page

female). DESCRIPTION. Seven donors demonstrated a pyramidal lobe (30%). Of these, one donor had a pyramidal lobe with a thyroglossal duct present (4%), though it did not extend to the hyoid bone. One other donor had a pyramidal lobe, with a thyroglossal duct remnant extending from the pyramidal lobe to the suprahyoid region (4%). SIGNIFICANCE. During embryologic development, thyroid cells descend from the foramen cecum via the thyroglossal duct, passing anterior to the hyoid and the laryngeal cartilage, to reach the final destination in the neck around the seventh week of gestation. Typically, the thyroglossal duct involutes by the tenth week. Persistence of the caudal end of the duct results in a pyramidal lobe in up to 50% of the population, whereas persistence of the superior portion, may lead to formation of TGDC in 7% of the population. Although uncommon, persistent thyroglossal duct may develop into TGDC, which requires surgical excision. The Sistrunk procedure is used, in which the central portion of the hyoid bone is removed, as TGDC are commonly adherent to the bone, and to reduce recurrence. Surgeons must ensure that the patient has other thyroid tissue present before removing the duct in the case that the duct was the patient's only thyroid tissue. Understanding this variation is critical for surgical education for safe thyroglossal duct and TGDC excision.

76.

*BARWARI, Arene S.[1], Joseph X. ANDERS[2], Rylan M. WILLIS[1], Sarah A. KNUTSON[1], Denise ARRICK[1], and Ethan L. SNOW[2]. [1]Sanford School of Medicine, University of South Dakota, Vermillion, SD, 57069, USA; [2]College of Natural Sciences, South Dakota State University, Brookings, SD, 57007, USA..

Situs Inversus Totalis: Cadaveric Analysis and Clinical Implications of Dextrocardia.

INTRODUCTION. Situs inversus totalis (SIT) is a rare (1:10,000) congenital aberrancy in which the thoracic and abdominal organs develop in mirror-image to their typical anatomical arrangement. SIT is associated with multiple comorbidities. Cadaveric studies can provide valuable insights about how SIT presents clinically, though few publications are available. The purpose of this study is to investigate cardiothoracic irregularities in a cadaveric case of SIT. RESOURCES. SIT was discovered upon routine dissection of an adult human cadaver. The variations were photographed in situ and ex situ with scale. Seven tissue samples (~3 mm^3) from the ascending aorta were collected, processed for histology (paraffin embedded), sectioned (5 μm), stained (H&E, McLetchie trichrome), and examined via digital light microscopy for compositional irregularities. DESCRIPTION. The ascending aorta was noticeably dilated and displaced the superior vena cava posteriorly. Upon cross-section, a 3.3 cm x 2.5 cm subseptate diverticulum was discovered on a comparably sized aorta. The septum exhibited medial cystic necrosis and significant smooth muscle degradation in the tunica media on the diverticulum side. Analysis of a separate atypical ridge in the aorta wall revealed similar findings. The aorta side of the septum and other aortic wall tissues appeared normal. Aside from their complete anatomical transposition, the other cardiothoracic anatomy was also unremarkable. SIGNIFICANCE. Persistent embryological vestiges associated with dextrocardia present serious clinical concerns (e.g., hemodynamic unpredictability, vascular constriction, aortic dissection) for individuals with SIT. Knowledge about SIT is also relevant for navigating unique considerations for organ transplantations, PICC line placements, and other anatomically influenced procedures. This report may therefore serve as a valuable anatomical and pathohistological reference for clinicians, medical educators, students, and patients.

continued on next page

77.

* KNUTSON, Sarah A.[1], Caylee A. WEBER[2], Rylan M. WILLIS[1], Arene S. BARWARI[1], Denise ARRICK[1], and Ethan L. SNOW[2]. [1]Sanford School of Medicine, University of South Dakota, Vermillion, SD, 57069, USA; [2]College of Natural Sciences, South Dakota State University, Brookings, SD, 57007, USA.

Situs Inversus Totalis: Cadaveric Analysis with Abdominal Vascular Implications.

INTRODUCTION. Situs inversus totalis (SIT) is distinguished by the mirror-image transposition of the thoracoabdominal viscera. The rarity of SIT limits the number of available reports describing its unique characteristics. While patient cases often involve non-invasive clinical imaging and an interactive history, cadaveric studies offer unobstructed views of the anatomy and unlimited dissection. This study aims to perform an anatomical investigation of the abdominal vasculature in a cadaveric case of SIT. RESOURCES. The case was discovered during regular academic dissection of an adult human cadaver. Systematic dissection was performed to identify the main branches of the celiac trunk, superior mesenteric artery, and inferior mesenteric artery. The unpaired branches of the abdominal aorta were then also identified. Serial photos were taken, and gross parametric measurements were collected. DESCRIPTION. As expected with SIT, each abdominal organ was anatomically transposed. The unpaired branches of the abdominal aorta exhibited branching patterns consistent with typical variability; however, the left kidney exhibited significant vascular variation. A small left superior renal artery (d = 3.2 mm) followed a typical course while a larger inferior supply (d = 7.2 mm) branched 8.6 cm lower and traversed anterior to the inferior vena cava. The left kidney also exhibited a significantly enlarged amorphic hilum. The right kidney and renal artery (d = 7.6 mm) were unremarkable. SIGNIFICANCE. SIT is known to instigate serious vascular sequelae (vascular rings, nutcracker syndrome, hematuria, radiant pain, etc.), and the kidneys may be especially prone to resulting issues. In serious cases, surgical vascular reconstruction may be warranted to prevent irreversible damage. This study may translationally guide cardiovascular specialists and medical anatomy educators when deliberating clinical diagnoses, procedural planning, and interventional therapies for patients with SIT.

78.

* HAWI Jihad1, Joelle MILAN[2], Mohamad ALQASSAB[2], Ghassan NABBOUT[2], Hisham DAOUK[1], Antoine CHRABIE[1], Rosalyn JURJUS[1], and Abdo JURJUS[1]. [1]Department of Anatomy, Cell Biology and Physiological Sciences, Faculty of Medicine, American University of Beirut, 1107-2020 Beirut, Lebanon; [2]Department of Biomedical Sciences, Clinical Human Anatomy, Faculty of Medicine and Medical Sciences, University of Balamand, Koura, P.O. Box 100 Tripoli, Lebanon.

Aberrant Unilateral Axillary and Brachial Arteries: A Case Report.

INTRODUCTION. An unusual case of unilateral left double axillary and brachial arteries was observed on an embalmed male cadaver. RESOURCE. The variation was identified during routine cadaveric dissection performed in a medical anatomy class. DESCRIPTION. The axillary artery bifurcated at the beginning of its third part, giving two branches: deep and superficial. The deep branch followed the usual path of the axillary artery in relation to the brachial plexus and gave the three branches of the third part of the axillary artery to continue its course then as a deep brachial artery. The superficial branch gave no branches in the axilla and continued as the second and superficial brachial artery, which gave no named branches in the arm but bifurcated into radial and ulnar arteries midway in the arm. No deviations in the branching or path of the latter two arteries were observed except for their proximal branching level from the superficial brachial artery. The deep brachial artery gave the profunda brachii branch and continued itself as the superior ulnar collateral artery, with the absence of the inferior ulnar

continued on next page

collateral branch. The nerves of the brachial plexus coursed with the deep branch of the axillary artery. The nerves of the arm and forearm followed their normal anatomical pattern in relation to the different vessels and muscles. SIGNIFICANCE. Such a radical variation in the course and branching of the major arterial supply of the axilla and arm have an embryological basis and a significant clinical relevance.

79.

*FAYAZI, Mehri. Woody L. Hunt School of Dental Medicine, Texas Tech University Health Sciences Center, El Paso, TX 79905, USA.

Comprehensive Review of Anatomical Variability of the Spinal Accessory Nerve; Clinical Implications.

INTRODUCTION. The spinal accessory nerve (SAN), the eleventh cranial nerve, innervates the sternocleidomastoid (SCM) and trapezius. It ranked as the fifth most commonly injured nerve during neck and cervical lymph node surgeries. Its variable origin, relationship to the internal jugular vein (IJV), and branching increase the risk of iatrogenic injury and shoulder syndrome. RESOURCES. A comprehensive search of PubMed, Scopus, and Web of Science was conducted, including cadaveric, imaging, meta-analytic, and clinical studies, to examine SAN variations. DESCRIPTION. Across previous cadaveric data, the SAN spinal root arose from C1–C4 or C1–C5 (range C1–C7), with C2 contributing most (38.3%), while C5–C7 were minimal. Analyses of previous neck specimens identified principal anatomical patterns: the SAN superficial to the IJV (39.8–96.6%) and deep to the IJV (2.6–57.4%). Rare variants included the nerve traversing the IJV (0.9–2.8%) and splitting to pass around the IJV (0.5%). Rare cases of duplication were reported. Lateral IJV crossings were associated with larger level IIb lymph nodes. Previous studies have shown that SAN branching in relation to the SCM and trapezius varies, with about half penetrating the muscle; non-penetrating branches were more prone to injury. The trapezius division showed four branching patterns, mostly running deep to the SCM (58.3%), entering as a single trunk in 75% and dual branches in 21%. The extracranial length of the SAN was 12.02 ± 2.32 cm, and its position correlated with neck length and height. The most reliable landmarks for the SAN are the greater auricular point, Erb's point, mastoid process, posterior belly of the digastric muscle, SCM, and angle of the mandible. SIGNIFICANCE. The SAN shows marked variability in origin, cervical root contributions, relationship to the IJV, and branching to the SCM and trapezius. SAN variations can increase surgical risk, and awareness of these patterns and the use of reliable landmarks are essential to reduce postoperative shoulder dysfunction

80.

*FAYAZI, Mehri[1], Liam P. BALLON[1], Rachel E. LIN[1], Kylee G. MARKOWSKY[1], Miriam B. MECHREF[1], Varun PASAPULA[2], Aliasghar ARABI MIANROODI[2], and Heather A. BALSIGER[2]. [1]Woody L. Hunt School of Dental Medicine, Texas Tech University Health Sciences Center El Paso, El Paso, TX, 79905, USA; [2]Paul L. Foster School of Medicine, Texas Tech University Health Sciences Center El Paso, El Paso, TX, 79905, USA.

Anatomical and Morphometric Analysis of the Mental Foramen in Adult Cadaveric Mandibles.

INTRODUCTION. The mental foramen (MF) transmits the mental nerve and vessels through the mandibular body. Precise localization is essential for nerve block anesthesia, implant placement, periapical and orthognathic surgery, and fracture fixation. Variability in MF morphology across populations is documented, yet cadaveric data from the U.S.-Mexico border remain limited. This study characterized the position, shape, orientation, and dimensions of the MF in adult cadaveric mandibles. METHODS. Measurements were obtained from 38 mandibular specimens (19 adult cadavers over 18 years old). Specimens presenting pathological lesions, premolar fractures, congenital deformities, or severe alveolar erosion were excluded. Measurements were recorded, including the vertical height and horizontal width of the MF, as well as its distances to the alveolar crest, inferior

continued on next page

mandibular border, mental symphysis, mandibular angle, and mental protuberance. Additionally, the shape, opening orientation, tooth position relative to the MF, and presence of accessory foramina were documented (IBC #26006). SUMMARY. Mean vertical height and horizontal width of the MF were 2.41 mm and 3.32 mm (SD ± 0.59 and 0.77). Mean distances to the alveolar crest, inferior mandibular border, mental symphysis, mandibular angle, and mental protuberance were 12.39, 14.13, 25.97, 59.81, and 20.92 mm respectively (SD ± 2.34, 1.95, 2.58, 4.47, and 5.16). The MF was predominantly oval (76.3%), posterosuperiorly oriented in 78.95% of cases, and most commonly located below the second premolar (68.42%). No accessory foramina were observed. CONCLUSIONS. The MF was most commonly oval, located below the second premolar, and oriented posterosuperiorly. These findings provide useful morphometric and anatomical references for dental and maxillofacial procedures and support improved preoperative planning in the U.S.–Mexico border region. (Acknowledgments: TTUHSC, Institute of Anatomical Sciences; Willed Body Program).

81.

*KUMAR, Sushil, Kathleen BUBB, Ritwik BAIDYA, Tanya MAISTRY, and Estomih MTUI. Division of Anatomy, Department of Radiology, Weill Cornell Medicine, New York City, NY, 10065, USA.

High Division of the Brachial Artery,Unusual Connection,and Persistent Median Artery: A Case Report.

INTRODUCTION. The brachial artery, the main source of arterial supply to the upper limb, begins as a continuation of the axillary artery at the distal border of the teres major muscle and terminates into the radial and ulnar arteries in the cubital fossa. The common interosseous artery branches off from the ulnar artery, splitting into the anterior and posterior interosseous arteries. Abnormal development of the primitive axial artery leads to various upper limb vascular anomalies. RESOURCES. A case of high division of the brachial artery with unusual connection (median cubital arterial arch) and persistent median artery was found during routine dissection of a 59-year-old female donor's right upper limb at the anatomy lab, Division of Anatomy, Weill Cornell Medicine, New York, USA. DESCRIPTION. The brachial artery divided into the ulnar and radial (brachioradial) arteries distal to the teres major muscle. Both branches had a torturous course in the arm. The radial artery crossed the median nerve, while the ulnar artery traveled deep to the biceps brachii and the median nerve. An oblique artery connected the radial and ulnar arteries in the cubital fossa. The ulnar artery gave rise to a common trunk branching into the median artery, the anterior interosseous artery, and the posterior interosseous artery. The median artery accompanies the median nerve in the forearm. SIGNIFICANCE. This anatomical variation is significant as it may lead to accidental arterial injection, inaccurate blood pressure readings, or median nerve compression due to the persistent median artery.

82.

*CHHABRA[1], Prabhjot K. and Mahindra K. ANAND[2]. [1]Department of Anatomy, Mahatma Gandhi Medical College & Hospital, Sitapura 302022, Jaipur, Rajasthan, India; [2]Department of Anatomy, Noida International Institute of Medical Sciences, Gautam Buddha Nagar, Uttar Pradesh, 203201, India.

Evaluation of the Impact of Structured Reflections on Students Learning in Anatomy.

INTRODUCTION. Many undergraduate medical students struggle to connect anatomical structures with their clinical applications, resulting in gaps in knowledge that can hinder their future clinical practice. Literature reports that there is lack of integration of reflections as learning tool in undergraduate curriculum especially in preclinical years in spite of its proven ability to develop case diagnosing abilities, case solving approach and educational impact. Present research was therefore undertaken to introduce and explore the impact of structured reflection exercises on improving students ability to integrate and apply anatomical knowledge effectively. METHODS.

continued on next page

Intervention included structured reflections written by students using lecture as a learning experience. Students were divided into two groups having same baseline knowledge. One group (Group A) wrote reflections on a structured reflection template at the end of each lecture for four consecutive sessions. The other group (Group B) learned gross anatomy through lectures only. Four lectures were taken at one week duration. Students submitted a final reflection after the four sessions. The structured reflections of Group A were assessed through pre-existing validated assessment rubric and feedback was given for improvement after each lecture. Post test was taken and perceptions of the students and faculty were analysed. SUMMARY. The mean post test scores of the group of students who wrote structured reflections additionally were significantly higher($p<0.05$) than those who learned from lectures only. Most of the students and faculty perceived the structured reflective writing exercises as a feasible and effective learning tool. CONCLUSIONS. Structured reflection exercises have been found helpful as an additional learning tool in anatomy for students to integrate and correlate anatomical knowledge with its clinical applications.

83.

*MCDOWELL, Maresa[1], John BOUGHTER[2], and Joseph CALLAWAY[2]. [1]Department of Medical Education, The University of Tennessee Health Science Center, Memphis, TN 38103, USA; [2]Department of Anatomy and Neurobiology, The University of Tennessee Health Science Center, Memphis, TN, 38103, USA.

Morphology of the Human Maxillary Sinus: Septal Prevalence, Depth, and Neurovascular Relationships.

INTRODUCTION. Anatomical variation of the maxillary sinus is of clinical importance for maxillofacial procedures, with respect to the presence of septa and sinus depth. Septa are small projections of bone that arise from the walls or floor of the sinus, creating chambers or cavities within the sinus. Their presence increases surgical complexity, yet their prevalence, symmetry and neurovascular relationship is still being elucidated. The purpose of this study was to document the prevalence and symmetry of septa, describe their spatial orientation with respect to the infraorbital canal (IOC) and its neurovasculature and quantify maxillary sinus depth. METHODS. Dissections of the maxillary sinuses from 55 cadavers (110 sinuses) were done bilaterally. The demographics included 30 females, 25 males with the average age of 86 for females and 81 for males. The depth of each sinus was measured and examined for the presence the septa. When present the number, height, width, location and orientation relative to the IOC were documented. Statistical analyses were further used to assess the relationship among sex, depth, septa and age. SUMMARY. Mean depth of the maxillary sinus was 25.72 mm in females, 28.54 mm in males which was significantly different (t-test, $p = 0.005$) with no significant side-to-side differences or correlation with age. Septa were present in slightly more than half of cadavers: 40% had no septa, 36% had unilateral septa, and 24% had bilateral septa. Overall, 42% demonstrated side-to-side asymmetry. Septa were most commonly vertical and located posterior to the IOC, with mean width 1.42 mm, height 9.18 mm, and distance 6.71 mm posterior to the IOC, forming a cavity averaging 4.7 mm in depth. Neurovascular structures, likely middle superior alveolar branches, were frequently observed within these septa. Several anatomical variants were identified, including secondary, horizontal, and accessory canal–associated septa. CONCLUSIONS. For this study maxillary sinus septa proved common and frequently asymmetrical with sinus depth differing most by sex but not age and septal presence. The recurrent proximity of septa to the neurovascular structure highlights the importance of anatomical assessment for maxillofacial surgical procedures.

continued on next page

84.
*SHORT, Nathan[1], Carlos SUAREZ-QUIAN[2], and Joel VILENSKY[3]. [1]Department of Occupational Therapy, Abilene Christian University, Abilene, TX, 79601, USA; [2]Department of Biochemistry, Molecular, and Cellular Biology, Georgetown University, Washington, D.C., 20057, USA; [3] Department of Anatomy and Cell Biology, Indiana University, Indianapolis, IN, 46202, USA.

Dry Needling Restores Hand Function for a Professional Skydiver with Chronic Interossei Tightness.

INTRODUCTION. Because of their attachment to the lateral bands of the extensor digitorum, tightness and shortening of the interossei muscles after immobilization or injury, limits the distal migration of the extensor mechanism when flexing the fingers. This passive insufficiency of the interossei impairs mobility, strength, and function of the hand. This case report presents the use of dry needling to restore hand function for a professional skydiver with chronic interossei tightness. RESOURCES. The case involved dry needling, the insertion of a thin, filiform needle into muscle or connective tissue to reduce tension, improve micro circulation, and normalize pain response. DESCRIPTION. A 74-year-old male presented with chronic interossei tightness that had persisted since a distal radius fracture sustained 15 months prior. Clinical assessment revealed limited active hook fist (flexing the PIP/DIP joints with the MCP joints extended), a positive Bunnel-Littler test (indicative of interossei tightness) weakness in grip strength, and impaired functional use of the hand. He was treated by an occupational therapist (OT) who is also a certified hand therapist (CHT) using traditional interventions (e.g. tendon gliding, exercise splinting) in addition to dry needling of the interossei with electrical stimulation for 6 therapy sessions over the course of 5 weeks. His limitations completely resolved with full active hook fist, a negative Bunnel-Littler test, and a return to baseline grip strength (in comparison to his non-affected hand) and function. SIGNIFICANCE. Tightness of the interosseous muscles is a common complication that results in significant impairment to motion, strength, and function of the human hand. Dry needling presents the unique ability to access the tight anatomical space in which the interossei are contained with direct, intermuscular stimulation. This case warrants further exploration of dry needling to address chronic interossei restrictions and restore function within hand therapy practice.

85.
*NOEL, Geoffroy P.J.C. and Megan TRAN-HEFLINGER. Division of Anatomy, Department of Surgery, University of California San Diego School of Medicine, San Diego, CA, 92093, USA.

Painting or Tattooing? Comparing Body Painting and Temporary Tattoos for Learning Surface Anatomy.

INTRODUCTION. Body painting is a well-established active learning strategy in anatomy education that promotes engagement and spatial understanding of surface anatomy. However, it is time-intensive and may disadvantage students with limited artistic confidence. Temporary tattoos may offer a faster, standardized alternative. METHODS. An intensive undergraduate anatomy course included four weekly surface anatomy sessions (face/neck, arm/forearm, hand, leg). Participants were randomly assigned to Body Painting (BP) or Temporary Tattoos (TT) for each session and participated in both modalities twice. Quiz scores and time-on-task were recorded after each session. Control scores were derived from regions not associated with either modality. Statistical analyses included Friedman tests and Wilcoxon signed-rank tests. Per-participant costs were calculated for both modalities. SUMMARY. Learning condition significantly affected quiz performance ($Q(2) = 6.595$, $p = 0.037$). Median scores were 78% [IQR: 72–84] for control regions, 85% [80–89] for BP, and 84% [79–88] for TT. Both BP and TT significantly outperformed control regions (ΔBP, $p < 0.0001$; ΔTT, $p = 0.019$). Absolute quiz scores

continued on next page

did not differ between BP and TT (p = 0.657), but TT yielded significantly larger relative gains within-subjects (ΔTT – ΔBP, p < 0.0001). BP required more time than TT (26.5 vs 15.0 min; p < 0.0001). Per-participant costs were comparable (BP: USD$8.92; TT: USD$9.64). CONCLUSIONS. Both modalities enhanced surface anatomy learning. Temporary tattoos produced larger relative gains while requiring less time, suggesting a more time-efficient alternative to body painting without compromising learning outcomes.

86.

*NOEL Geoffroy[1], Brenda GARCIA[1], Tiffany HO[1], Dong-Jin Eastern KANG SIM1, and Andrej SUCHOMLINOV2. [1]University of California San Diego, La Jolla, CA, 92037, USA; [2]Vilnius University, Vilnius, 01513, Lithuania.

Formation Patterns of the Sural Nerve Predict Its Course Through the Deep Crural Fascia.

INTRODUCTION. The sural nerve (SN) demonstrates substantial variability in its formation. Whether specific formation patterns are associated with distinct courses of the nerve and its contributing branches through the deep crural fascia has not been systematically investigated. Branches may simply perforate the fascia or course within defined intrafascial canals. This study aims to examine the relationship between sural nerve formation patterns and the manner in which the nerve and its contributing branches traverse the deep crural fascia. METHODS. A cross-sectional cadaveric study was conducted on 27 lower limbs from 22 formalin-fixed adult donors. The SN and its contributing branches were traced from formation to the lateral malleolus. Fascial relationships were classified as: no contact, simple perforation, or intrafascial tunneling within a defined canal. Formation patterns were categorized as complex dual, simple dual, single-dominant, or rare variants. Associations between formation type and fascial course were analyzed using descriptive statistics and Bayesian logistic regression. SUMMARY. Single-dominant formations were most common (59.3%), followed by complex dual (18.5%) and simple dual (18.5%) patterns. Complex dual formations consistently demonstrated traversal of the deep crural fascia by both contributing branches, most frequently via intrafascial tunneling. In contrast, single-dominant formations more often showed either no fascial contact or simple perforation, with fewer intrafascial courses. Bayesian analysis demonstrated a 98.8% posterior probability that complex dual formations are associated with a greater likelihood of bilateral fascial traversal compared with single-dominant formations. Model discrimination was good (AUC = 0.802). CONCLUSIONS. Sural nerve formation patterns are associated with distinct fascial courses. Complex dual formations more frequently involve bilateral intrafascial traversal, whereas single-dominant formations typically exhibit simpler or absent fascial crossings. These findings refine the anatomical understanding of sural nerve–fascia relationships and provide a structural basis for future clinical and biomechanical investigation.

87.

* DIMATTEO, Brigida, Jessica LIN, Philip SKORZEWSKI, Terri LAWRENCE, and Anna FARIAS. Schulich School of Medicine & Dentistry, Windsor, ON, N6A 5C1, Canada.

Advanced Prosection and Anatomy Education Program.

INTRODUCTION. Human cadaveric dissection has been an integral cornerstone of medical training for over a millennium, facilitating three-dimensional anatomical knowledge, clinical correlation, and soft skills foundational to medicine. Moreover, prosection development can serve as a scaffold to enhance medical trainees' skill sets as they transition from in-class didactic training to clinical observerships and clerkship rotations. Thus, a team of preclinical medical students collaborated with anatomists to develop an innovative cadaveric prosection program to enhance medical teaching and community outreach at the Schulich School of Medicine, Windsor

continued on next page

campus. RESOURCES. Netter Atlas of Human Anatomy (8th edition), Grant's Atlas of Anatomy (14th edition), and Anatomy A Photographic Atlas (8th edition) were used in conjunction with Schulich School of Medicine anatomy modules. Online apps such as Touch Anatomy Surgery and Ortho Bullets were utilized. DESCRIPTION. The prosection development program was created in partnership with anatomists and pre-clerkship medical students. By reviewing medical curricula and human cadaveric specimens, we designed and tailored several interactive prosections to highlight pertinent musculoskeletal and neurovascular relationships. SIGNIFICANCE. The collaborative development of cadaveric prosections resulted in noteworthy improvements in teamwork, clinical decision making, visuospatial awareness, and manual dexterity; skills fundamental to the transition from pre-clerkship to clinical observerships and clerkship training. Specifically, in hospital- and clinic-based settings, the program increased our effectiveness as surgical team members, our ability to identify anomalies, our proficiency in radiographic analysis, and our engagement with medical teams. Furthermore, the prosections were utilized to facilitate interactive, educational community outreach sessions led by medical students, expanding our teaching and communication competencies.

88.

*RAEBURN, Kazzara[1], Paulette MITCHELL[1], Abhigna KANDIMALLA [1], Marios LOUKAS[1,2,3], and Robert GRANT[4]. [1]Department of Anatomical Sciences, St. George's University, School of Medicine, Grenada, West Indies; [2]Department of Pathology, St. George's University, School of Medicine, Grenada, West Indies; [3]Department of Clinical Anatomy, Mayo Clinic, Rochester, MN, 55905, USA; [4]Department of Surgery, St. George's University, School of Medicine, Grenada, West Indies.

Ultrasound investigation of the Arcuate Line.

INTRODUCTION**.** The arcuate line (AL) is a key anatomical landmark of the lower abdominal wall, marking the transition from the posterior rectus sheath to the transversalis fascia. Variability in its location has important implications for procedures such as hernia repair, abdominoplasty, and rectus muscle flap reconstruction. Despite its clinical relevance, its relationship to surface anatomical landmarks and the impact of postural changes remain poorly defined. This study used ultrasound to examine the relationship between the AL and surface anatomical landmarks including the umbilicus, pubic symphysis, xiphoid process, and anterior superior iliac spine, and to assess the influence of postural changes on these relationships. METHODS. A cross-sectional study was conducted on a cohort of participants, with ultrasound imaging used to locate the AL and measure its distance from key anatomical landmarks in both supine and standing positions. Statistical analyses, including paired t-tests, independent t-tests, and Pearson correlation, were performed to assess the effects of posture and the influence of anthropometric variables such as BMI and waist-hip ratio. SUMMARY. The study found significant variability in the AL's location across individuals. Postural changes significantly affected the measured distances between the AL and surface landmarks ($p < 0.05$). BMI demonstrated a negative correlation with AL positioning ($r = -0.67$, $p = 0.017$), whereas waist-hip ratio did not exhibit a strong relationship ($p = 0.935$). No significant sex-based differences were observed ($p = 0.167$). CONCLUSION. The location of the AL varies among individuals and is influenced by posture. These findings emphasize the importance of preoperative imaging, particularly ultrasonography, for accurate anatomical identification and have broader implications for preoperative site marking in plastic surgery, which is often performed with the patient standing. Awareness of posture-related shifts in anatomical structures is essential when translating surface markings to the supine intraoperative setting, underscoring the need for precise anatomical knowledge to optimize surgical planning and minimize complications in plastic and reconstructive procedures.

continued on next page

89.
*BISHOP, Keith N, Brandt SCHNEIDER, Gurvinder KAUR, and Dan WEBSTER. Department of Medical Education, School of Medicine, Texas Tech University Health Sciences Center, Lubbock, Texas, 79430, USA.

Integrating Self-Directed Learning into the Anatomy Lab: A Model for Early Clinical Thinking.

INTRODUCTION. Anatomical variation is a critical component of clinical anatomy, yet early medical learners often focus primarily on identifying "normal" structures. The purpose of this project was to use a self-directed learning (SDL) activity within a donor-based anatomy course to help first-year medical students recognize anatomical variation, consider its potential clinical implications, and reflect on the donor as a former patient. RESOURCES. Resources required for this project included a cadaver-based anatomy laboratory with whole-body donors, a structured SDL worksheet, access to peer-reviewed literature databases through the library, and faculty and graduate teaching assistant facilitators to provide formative feedback. Expectations and assessment criteria were aligned across instructors through verbally communicated, shared guidelines for evaluating student work. DESCRIPTION. Each student selected an anatomical finding from any donor in the laboratory and conducted independent research using four to five credible sources. Students evaluated whether the finding represented a normal variation, pathological condition, or prior medical intervention and whether it may have impacted the donor's health or cause of death. Students summarized their findings on a worksheet, discussed with peers and teaching assistants, and presented to faculty. Students revised their work based on feedback before final submission. Reflective items assessed perceptions of donor respect, clinical relevance, and the role of anatomy in medical practice. SIGNIFICANCE. This project reinforces clinical anatomy by requiring students to distinguish normal anatomy from variation and pathology using real human donors. It promotes early clinical reasoning, professional identity formation, and appreciation of anatomical variability encountered in patient care. The activity provides a practical model for integrating SDL into donor-based anatomy education.

90.
*CHERULLO, Joseph E.[1], Scott ECHOLS[2], and Daniel T. DALY[1]. [1]Center for Anatomical Science and Education, Department of Surgery, Saint Louis University School of Medicine, Saint Louis, MO, 63104, United States; [2]Scarlet Imaging LLC, PO Box 57515 Murray, UT 84157-0515, USA.

Use of a Novel Contrast Agent to Evaluate Renal Vasculature of Cadaveric Kidneys.

INTRODUCTION. Visualization of the human vascular system has utilized various techniques from casting to contrast agent use during advanced imaging. To visualize the microvasculature of the human kidney, a proprietary contrast agent, BriteVu, was utilized in conjunction with computed tomography (CT) imaging. BriteVu is quite radiodense, perfuses vasculature to the capillary level, and is non-toxic and environmentally friendly, though few have looked at its utility in evaluation of vasculature in human tissue. RESOURCES. Four cadaveric kidneys were obtained from three anatomical donors to the Saint Louis University School of Medicine Gift Body Program. These kidneys were "lightly fixed" with an ethylene glycol based embalming solution. Following harvesting, each kidney was flushed with distilled water and then perfused with BriteVu per manufacturer recommendations. Following BriteVu perfusion, CT was performed using a SOMATOM force CT scanner and images were analyzed with RadiAnt DICOM viewer software. DESCRIPTION. Following distilled water flush and BriteVu perfusion the renal vasculature was observed and analyzed using CT imaging and RadiAnt software. Average cortical thickness, which is an indirect measure of vascularity correlated with renal function, was found to be 1.34 cm, 0.96 cm, 1.80 cm, and 1.49 cm. Renal vessels as small as 0.54 mm in diameter were able to be accurately measured. Future studies should utilize refined CT settings or microCT for increased resolution to allow for analysis of renal vasculature

continued on next page

at the capillary level. SIGNIFICANCE. Utilization of BriteVu to visualize and quantify vasculature in anatomical specimens creates a new approach to evaluate the vascular system. This technique can be applied to any organ or tissue thus providing new opportunities for anatomical research in the realm of human microvasculature.

91.
*RICCI, Anna L. and Abigail C. HIELSCHER. Department of Neurological Sciences, College of Medicine, University of Vermont, Burlington, VT, 05405.

Development of a Formative Anatomy Question Bank for Preclinical Medical Students.

INTRODUCTION. Formative assessments are excellent resources for students to perform spaced retrieval practice, which is essential for learning and memory. This is particularly important in anatomy education as students are exposed to large amounts of information, often in short periods of time. To address this, we developed an interactive question bank for medical students to assess their anatomical knowledge and receive formative feedback. RESOURCES. Two anatomy faculty developed a bank of 240 multiple-choice-questions (MCQs) with explanations. The Curriculum Team integrated the MCQs and explanations into an interactive Articulate Storyline 360 platform (Articulate Global, LLC). DESCRIPTION. The resource is organized into 8 sections: Back, Upper Limb, Lower Limb, Thorax, Abdomen, Pelvis, Head, and Neck. Each section has a total of 30 MCQs: 15 on foundational anatomical concepts and 15 applying anatomy to clinical scenarios. Students may select the anatomical region, then the foundational anatomy or clinical anatomy questions. Students select an answer for the MCQ, then receive immediate feedback on whether their answer choice is correct and additionally receive an explanation describing each answer option. Students who have engaged with the anatomy question bank will be prompted to take a survey on its efficacy. The University's IRB determined this to be exempt from full review (STUDY00003670). SIGNIFICANCE. This resource provides additional opportunities for students to practice spaced retrieval of anatomical knowledge and apply it to clinical scenarios, which could improve long-term knowledge retention. This study tool may be used when learning anatomy for the first-time or when returning to it during preparation for USMLE Step exams, for example. Future work will expand this resource to be publicly available on a website for widespread use. (Sponsored by the College of Medicine's Teaching Academy Curriculum Development and Educational Scholarship Award.)

92.
*OZCAN, Ayse G.[1], Busra PIRINC[1], Betul SEVINDIK[1], Ekrem SOLMAZ[1], Mustafa KOPLAY[2] and Ahmet K. KARABULUT[1]. [1]Department of Anatomy, Faculty of Medicine, Selcuk University, Konya, 42130, Turkey; [2]Department of Radiology, Faculty of Medicine, Selcuk University, Konya, 42130, Turkey.

Renal Morphometry Using 3D Slicer: Determining Normal Reference Values with Advanced Imaging Methods.

INTRODUCTION. This study aimed to establish comprehensive reference values for kidney volume and surface area in healthy individuals using 3D Slicer software, based on computed tomography (CT) scans. METHODS. In this study, a total of 582 kidneys from 291 individuals aged 19 to 89 who underwent abdominal CT scans and had no renal pathology were retrospectively examined. The images were imported into the 3D Slicer software (version 5.6.2) in DICOM format, and automatic segmentation was performed using the Total Segmentator module. The volumes and surface areas of both kidneys were measured and compared according to age and sex groups. SUMMARY. Kidney volume and surface area values were found to be significantly higher in men than in women ($p<0.05$). This difference was particularly pronounced in the 30-69 age range. The highest volume values in women were found in the 40–49 age group, while in men they were found in the 30–59 age group. However, in

continued on next page

groups over seventy years old, the gender difference lost its statistical significance. Additionally, the left kidney was found to be significantly larger than the right kidney ($p<0.05$). As age increases, a gradual decrease in kidney volume and surface area is observed in both sexes. CONCLUSIONS. This study presents age- and sex-specific reference values for kidney volume and surface area in healthy individuals using 3D Slicer software. The findings support the reliability of 3D segmentation in assessing kidney morphometry and contribute to the determination of normal values in clinical applications.

93.
*BRENDAL, Courtney R. and Sue M. SIMON. Department of Anatomy, St. George's University, Grenada, West Indies.

Misdiagnosed Masses – Spreading Awareness of Splenogonadal Fusion Through Medical Illustration.

INTRODUCTION. Anatomical variations are not thoroughly explored in standard medical education. Consequently, encounters with variations can frequently be misinterpreted as other structural features or pathologies due to lack of clinically relevant knowledge. Splenogonadal fusion (SGF) is an especially complex case. It is a congenital condition usually observed in male infants, in which splenic tissue attaches to gonadal tissue as a non-malignant mass. Misdiagnoses due to suspicion of malignancy have historically resulted in unnecessary removal of one or both testes. RESOURCES. A series of illustrations of SGF were created using Adobe® Photoshop® and Adobe® Illustrator®. These images were informed by descriptions from literature reviews and figures of specimens from case studies, which included photographs, ultrasound, CT, and MR imaging. Other medical illustrations about SGF were also referenced. DESCRIPTION. This is a visual learning resource about the types of SGF, its pathogenesis, and surgical treatment. It includes clinically important terminology intended to educate medical audiences. SIGNIFICANCE. It is essential to increase physician awareness of SGF to avoid needless surgical intervention. A medical educational resource using detailed imagery and succinct descriptions may encourage more thorough consideration of SGF as a diagnostic possibility during pre-operative investigation. Furthermore, these materials could become a standard format for efficient instruction on similarly challenging anatomical variation cases.

94.
*TESSEMA, Chernet B.Department of Biomedical Sciences, School of Medicine and Health Sciences, University of North Dakota, Grand Forks, ND, 58202, USA.

Double Coronary Artery Bypass in a Donor with Type II Bovine Arch and Left-Dominant Coronary Artery.

INTRODUCTION. A bovine aortic arch (BAA) is the most common variation of the branches of the aortic arch (AA), with a prevalence of 15–35% in the general population. It is classified as Type I or Type II BAA. In Type I, the brachiocephalic trunk (BCT) and the left common carotid artery (LCCA) share a common origin from AA. In Type II, the LCCA arises from BCT. Coronary artery dominance (CAD) depends on which of the two coronary arteries (CAs) gives rise to the posterior descending artery (PDA) to supply the posterior third of the interventricular septum. Based on this, CA circulation can be right-dominant, left-dominant, or codominant. In most cases, the PDA originates from the right coronary artery, and therefore, the CA circulation is right-dominant. RESOURCES. Unusual combinations of a Type II BAA and a dominant left CA, with double CA bypass grafts (CABG), were incidentally identified in a 90-year-old donor. DESCRIPTION. The LCCA arose from the BCT about 1–2 cm above the AA and crossed obliquely to the left, ascending to the neck anterior and medial to the left subclavian artery. A left-dominant CA configuration was also noted, with the circumflex branch of the left CA continuing as the PDA in the posterior interventricular sulcus. Double CA bypass grafts, 1) ascending aorta-to-PDA and 2) left internal thoracic artery-to-LADA, were also observed. SIGNIFICANCE. Studies have shown that both BAA and

continued on next page

CA dominance do not cause clinical symptoms but are risk factors for cardiovascular and neurological diseases. The combined occurrence of the two risk factors in a single heart, as seen in this donor, may further increase the risk of associated diseases that may require interventions, including CABG, to improve coronary circulation and quality of life. Therefore, knowledge and awareness of such variations, as risk factors for significant life-threatening conditions, are of paramount importance in the diagnosis and management of associated diseases.

95.

*NATION, Haley L.[1], and Kelly LEMKE.[2], [1] Department of Cell Systems and Anatomy, Long School of Medicine, UT Health San Antonio, San Antonio, Texas, 78229, USA; [2] Department of Developmental Dentistry, School of Dentistry, UT Health San Antonio, San Antonio, Texas, 78229, USA.

Predental Anatomy and Physiology Coursework Does Not Predict Dental School Success.

INTRODUCTION. Although anatomy and physiology are foundational to dentistry, they are not universal admissions prerequisites, and their association with dental school performance remains unclear. This study investigated whether predental completion of anatomy and physiology coursework increased students' performance in biomedical science courses in the first and second year of dental school. METHODS. In this retrospective study of 599 students matriculating from 2017–2022, predental anatomy and physiology coursework (credit hours and institution type) was extracted from predental transcripts and analyzed. Data was compared to the DS1 and DS2 biomedical science GPA and dental gross anatomy course GPA using linear regression and an OLS (Ordinary Least Squares) model. SUMMARY. No statistically significant associations were found between predental anatomy/physiology coursework (completion or total hours) and DS1 biomedical science GPA (p=0.622 and p=0.210, respectively) or dental gross anatomy GPA (p=0.106 and p=0.740, respectively). Similarly, DS2 GPA was not associated with course predental anatomy/physiology course completion (p = 0.623); however, total predental lecture and lab anatomy/physiology hours were negatively associated with DS2 GPA (p=0.003). CONCLUSIONS. While various advanced foundational science courses may be a requirement or recommendation for admissions at some dental schools, and performance in these courses is a standard component of academic history review, anatomy and physiology coursework are not significant indicators of student performance in subsequent related coursework. Other predental factors such as DAT scores, course loads, and grade trends may be better indicators of dental school success.

96.

* LEONEL, Luciano[1], Punnose KATTIL[1], Morgan FORSTON[1], Yolanda SALINAS-ALVAREZ[1], Juan Antonio RIVERA-PEREZ[1], Stephen GRAEPEL[2], Megan BAUMAN[3], Nirusha Lachman[1] , and Maria PERIS-CELDA[2]. [1]Department of Clinical Anatomy, Mayo Clinic College of Medicine and Science, Rochester, MN, 55902, USA; [2]Department of Neurologic Surgery, Mayo Clinic, Rochester, MN, 55905, USA; [3]Department of Neurological Surgery, Washington University School of Medicine, St. Louis, MO, 63110, USA.

Integration of Cadaveric Dissections and Emerging Digital Technologies in Neurosurgery Residency.

INTRODUCTION. Cadaveric dissection remains one of the most reliable educational resources for developing and refining manual skills and dexterity in neuroanatomy and neurosurgical residency training. When combined with emerging technologies, the learning experience of clinical trainees offers an enhancement over standard approaches. We describe the use of formalin fixed cadaveric dissections integrated with stereoscopic images, photogrammetry and virtual reality (VR) in a residency program in neurosurgery. RESOURCES. A cadaveric course where residents in neurosurgery perform dissections of complex neurosurgical approaches to treat and access the skull base. The course takes place once a year integrating anatomical 3D lectures, VR and 3D photogrammetry

continued on next page

models along with hands-on dissections using cadaveric tissue previously injected with latex. An online app is also used to guide and assist residents during the activities. DESCRIPTION. Residents perform cadaveric dissections as part of a skull base curriculum focusing on open and endoscopic procedures. 3D lectures using stereoscopic images are used to highlight key anatomy and step-by-step guidance on procedures. Within the laboratory, the hands-on dissections are integrated with an online app created to guide residents throughout the dissections. VR associated with 3D photogrammetry models and medical imaging – computed tomography and magnetic resonance imaging – are also used to enhance and improve the laboratory experience. Residents have access to clinical cases manipulating and rotating 3D models to better comprehend the approaches. SIGNIFICANCE. Integration of digital technologies with cadaveric dissection enhances the hands-on learning experience of neurosurgical residents. Stereoscopic projections offer improved three-dimensional views of anatomical structures while photogrammetry models and virtual reality technologies help to better understand spatial anatomical relationships.

97.
* ATHAVALE, Sunita, Chhabi KHEMUKA, Rekha LALWANI, and Sheetal KOTGIRWAR. Department of Anatomy, All India Institute of Medical Sciences Bhopal, Bhopal, MP, 462020, India.

Perceived Educational Environment among Medical Students in India: Insights from a National DREEM Study.

INTRODUCTION. The educational climate is a critical determinant of learner engagement, professional identity formation, and competency acquisition in medical education. In large, heterogeneous training systems, governance structures and curricular reforms may significantly influence student experience. This study evaluated undergraduate medical students' perceptions of their educational environment across institutional and curricular frameworks in India using the Dundee Ready Education Environment Measure (DREEM). METHODS. A cross-sectional electronic survey was conducted among 784 undergraduate medical students from public and private medical colleges. The 50-item DREEM instrument was administered, and comparative analyses were performed across governance models, ownership types, curricular structures, and training phases. SUMMARY. The overall mean DREEM score was 132/200, reflecting a generally positive climate. National Medical Commission–governed institutions scored higher (135.4 $\pm$ 22.8) than Institutes of National Importance (125.7 $\pm$ 27.0; $p < 0.001$). Private institutions reported higher scores (139.1 $\pm$ 21.7) compared with public models (128.5 $\pm$ 25.6; $p < 0.001$). Students under Competency-Based Medical Education perceived a more favorable environment (134.1 $\pm$ 24.1) than those in traditional curricula (129.6 $\pm$ 23.0; $p < 0.001$). Clinical-phase students demonstrated comparatively lower perceptions. CONCLUSIONS. While the overall educational climate was positive, measurable variability across governance and curricular frameworks highlights the influence of policy design on learner experience. The findings underscore the importance of structured competency-based reforms, faculty development, and strengthened learner support systems. These insights offer scalable lessons for health professional education systems undergoing curricular transition in resource-diverse and rapidly expanding contexts globally.

continued on next page

98.

*INOUE, Seiichi[1], Kosuke TABUCHI[2], Keishiro KIKUCHI[3] Shotaro KINOUCHI[2], Akihiro YAMASHITA[2], Yoko TABIRA[1], Hisashi NAKAMURA[1], Koji HIRAOKA[2], and Koichi WATANABE[1]. [1]Department of Anatomy, Kurume University School of Medicine, Kurume, Fukuoka, 8300011, Japan; [2]Department of Orthopedic Surgery, Kurume University School of Medicine, Kurume, Fukuoka, 8300011, Japan; [3]Department of Orthopedic Surgery, Social Insurance Tagawa Hospital, Tagawa, Fukuoka, 8268585, Japan

Anatomical Study of the Femoral Attachment of the Posterior Cruciate Ligament.

INTRODUCTION. Accurate femoral tunnel placement in posterior cruciate ligament (PCL) reconstruction requires anatomical knowledge of the PCL attachment. This study macroscopically and histologically evaluated the femoral attachments of the PCL and the meniscofemoral ligaments (MFLs) and investigated their associations with femoral condylar size, intercondylar notch size, age, and sex. METHODS. Forty formalin-fixed cadaveric knees (mean age 77.0 years) were used. The incidence of MFLs and its association with sex were analyzed. Long-axis widths of the PCL and posterior meniscofemoral ligament (pMFL) were measured, and their correlations with these parameters were analyzed. The PCL, including the pMFL, was divided into four parts and defined sequentially from the lateral side as slices 1–3. Short-axis widths of the PCL (slices 1–3) and the pMFL were measured macroscopically and histologically, and their correlations with these parameters were analyzed. SUMMARY. The anterior MFL was identified in 8 of 40 knees (20.0%) and the pMFL in 38 (95.0%); both were present in 6 (15.0%). No significant association with sex was observed. Long-axis width of the PCL was 19.4 ± 3.2 mm and that of the pMFL was 6.1 ± 1.7 mm; neither showed significant correlations. Short-axis widths of the PCL (slices 1–3) were 11.8 ± 1.6 mm, 12.0 ± 1.3 mm, and 9.0 ± 2.0 mm; that of the pMFL was 3.2 ± 1.2 mm, none showing significant correlations. Histologically, the medial intercondylar ridge (MIR) was identified in all specimens. The PCL was located between the anterior articular cartilage and the MIR, and the pMFL posterior to the MIR. Histological short-axis widths of the PCL (slices 1–3) were 9.2 ± 1.8 mm, 8.1 ± 1.8 mm, and 6.1 ± 1.5 mm; that of the pMFL was 2.2 ± 0.6 mm, without significant correlations. CONCLUSIONS. In PCL reconstruction, the femoral tunnel should be created within the area bounded by the anterior cartilage margin and the MIR.

99.

*NAKAMURA, Hisashi[1], Saori YOSHIKAWA[2], Yoko TABIRA[1], Seiichi INOUE[1], Tsuyoshi SAGA[3], and Koichi WATANABE[1]. [1]Department of Anatomy, Kurume University School of Medicine, Kurume, Fukuoka, 8300011, Japan; [2]Kurume University School of Medicine, Kurume, Fukuoka, 8300011, Japan; [3]Domain of Anatomy, Kurume University School of Nursing, Kurume, Fukuoka, 8300003, Japan.

Digital Enhancement of Formalin-Fixed Brain Sections: Implications for Brain Dissection Education.

INTRODUCTION. Unstained formalin-fixed human brain sections often show indistinct gray-white matter boundaries, making identification of nuclei and fiber tracts difficult, particularly in time-limited anatomy laboratory sessions. The purpose of this study was to determine whether digital image enhancement improves structural interpretability of formalin-fixed brain sections for anatomy education. METHODS. Brains from two formalin-fixed cadavers were examined: one for brainstem and cerebellum analysis and the other for the cerebrum. Eighteen transverse brainstem sections were evaluated (including 2 midbrain sections, with the remainder mainly from the pons and medulla oblongata). One cerebellar section containing the cerebellar nuclei was analyzed. For the cerebrum, three horizontal sections including the basal ganglia and two coronal sections including the basal ganglia and visual cortex were examined. Images were processed using Soft-MIEr image enhancement software (Logic & Design Co., Ltd.) and compared with unprocessed images under identical viewing conditions. Structures described in standard neuroanatomy textbooks were qualitatively assessed by comparative

continued on next page

visual analysis to determine whether enhancement improved boundary delineation and structural recognition. SUMMARY. Enhancement clarified gray-white matter contrast in the pons and medulla oblongata and facilitated identification of nuclei and tracts indistinct in unprocessed images. In the cerebellum and cerebrum, cortical and subcortical contrast improved, enhancing recognition of the cerebellar nuclei and basal ganglia, although some regions showed minimal change. CONCLUSIONS. Digital enhancement of formalin-fixed brain section images may improve structural clarity and observational efficiency in anatomy education. Development of an enhanced image database may support e-learning and pre- and post-laboratory instructional materials in neuroanatomy curricula.

100.
* KOLATOROWICZ, Adam[1], Pamela S. NELSON[2], and Amanda L. COLLINS[1]. [1]Department of Anatomy, DeBusk College of Osteopathic Medicine, Lincoln Memorial University, Knoxville, TN, 37932, USA; [2]Department of Anatomy, DeBusk College of Osteopathic Medicine, Lincoln Memorial University, Harrogate, TN, 37752, USA.

Records Retention Policies for Anatomical Donation Programs.

INTRODUCTION. Whole-body anatomical donation programs collect, retain, and dispose of numerous electronic and physical records related to the donors that support health science education and research. A records retention policy covers the entire lifecycle of a record to ensure compliance with relevant legal statutes, minimize risk, and reduce costs. Anatomical services subcommittees of professional anatomical associations recommend such policies as part of the best practices guidelines for donor programs. However, little information is available on constructing a policy specifically for a willed body program. The purpose of this presentation is to share with the anatomical services community the rationale and process for creating a records retention policy, as well as provide an example policy that could be used by other donor programs. RESOURCES. Records retention policies from organ donation programs and academic institutions were used to create a retention policy. DESCRIPTION. First, a list of all types of donor-related records was compiled. Next, a retention schedule was developed for each record type based on the needs of the program. Lastly, a plan for disposing of records, including the responsible party, was created. The university's Office of the Registrar, Information Services, and Office of the General Counsel were consulted to ensure the ADP's retention policy aligned with relevant academic, technology, and legal standards. The medical school's Dean's Council approved the policy to go into effect. SIGNIFICANCE. Records retention policies are necessary features of a well-functioning, transparent willed body program that meets the best practice guidelines of anatomical services associations. A documented policy allows for internal and external program auditing, increases operational efficiency, protects sensitive information, and aids in litigation readiness. The results of this project allow other donor programs to develop their own policy.

101.
*FISHER, Cara L., Alexander JOHNSON, and Matthew J. KLING. Department of Oral Biology, Creighton University School of Dentistry, Omaha, NE, 68178, USA.

Anatomical Variation of the Mandibular Foramen: Predictors of Inferior Alveolar Nerve Block Failure?

INTRODUCTION. The inferior alveolar nerve block (IANb) is the most common local anesthetic technique in dentistry, yet literature suggests failure rates between 5-30%. Current clinical practice typically relies on digital approximation to estimate needle placement, aiming posterior to the midpoint of the mandibular ramus. However, this method lacks precision and may be inconsistent due to anatomical variations such as the height of the mandibular foramen, differences in ramus width and thickness, and variation in the position of the lingula, a reliable landmark for the location of the mandibular foramen. This study investigates the relationship between the mandibular foramen and the midpoint of the ramus. By addressing the limitations of current approximation

continued on next page

techniques, this research aims to support more reliable anatomy-informed approaches to IANb thus reducing failure rates in clinical practice. METHODS. Using 42 embalmed hemimandibles (n=21 specimens), measurements including angle to notch, notch to lingula, ramus width, anterior border to lingula, and anterior ramus thickness were collected using digital calipers. SUMMARY. Analysis of the measurements revealed that the lingula was located anterior to the midpoint of the ramus in 19 hemimandibles, while 23 were positioned posterior to the midpoint. In regard to the height of the mandibular foramen, anterior lingula were positioned more inferiorly compared to posterior lingula. CONCLUSIONS. This study suggests that IANb needle placement posterior to the ramus midpoint may be unreliable due to significant variation in the height and anterior-posterior position of the mandibular foramen, further highlighting why traditional approximation techniques often fail. The impact of this study suggests that anatomical variation needs to be considered to increase inferior alveolar nerve block success rates and patient comfort.

102.

*IDRISS, Ahmedou M[1]., Sid A. LIMAM[1], Aboubakry SOW[1], Elhaj ADDE[1], and Sonia PUJOL[2]. [1]Clinical Anatomy Research Unit, Anatomy Lab., FMPOS, EN3S, Nouakchott University, Nouakchott, BP 880, Mauritania; [2]Brigham and Women's Hospital, Harvard Medical School, Boston, Massachusetts, MA, 02115, USA.

Comparative Study of Manual and Deep Learning Based Segmentation.

INTRODUCTION. High-quality digital anatomy atlases are essential for modern medical education and image-guided clinical practice. However, developing them often takes a lot of time and expertise due to the need for manual image segmentation. This problem is especially clear in low-resource areas, where skilled personnel may not be available. In this study, we compare expert manual segmentation with deep learning-based automatic segmentation for creating digital anatomy atlases. We focus on settings like Mauritania that are still developing. METHODS. We evaluated thirty cross-sectional imaging datasets, which included brain MRIs as well as thoracic and abdominal CT scans. Each dataset was segmented using two methods: expert manual delineation and automated segmentation using the TotalSegmentator framework within 3D Slicer platform. We assessed performance through Dice Similarity Coefficient, Hausdorff Distance, and segmentation time, along with feedback from anatomy teachers. SUMMARY. Automated segmentation consistently produced high overlap with expert annotations, with average Dice scores nearing 0.9. It also reduced processing time significantly compared to manual methods. While manual segmentation had strengths in capturing fine anatomical details and handling low-contrast structures, it was much more time-consuming and required greater expertise. Qualitative assessments showed that, with minor corrections, most automatically generated segmentations were acceptable for teaching purposes (24out of30 cases). CONCLUSIONS.These findings support hybrid approach for creating atlases, where deep learning-based segmentation is used for initial large-scale labeling, followed by targeted expert refinement and validation. This method provides practical balance between efficiency and anatomical accuracy. It also offers sustainable way to speed up the development of digital anatomy atlases in resource-limited settings.

continued on next page

103.
*IMMONEN, Jessica A[1], Jason CICCOTELLI[2] and Sung KIM[1]. [1]School of Dental Medicine, University of Nevada Las Vegas, Las Vegas, NV, 89106, USA. [2]School of Integrated Health Sciences, University of Nevada Las Vegas, Las Vegas, NV, 89154, USA.

Beyond the Lab: Clinical Anatomists Driving Solutions for Nevada Healthcare Crisis.

INTRODUCTION. An interdisciplinary team aims to fund an initiative that uses anatomy and neuroscience education to train and mentor undergraduate students for doctoral-level health professions. This initiative should increase the number of top-tier, in-state applicants to the state university doctoral-level health profession programs. Increasing the quantity of in-state applicants may directly address Nevada's healthcare shortages and improve the quality of healthcare delivery. METHODS. Our team includes members from across all of the offered doctoral-level health profession programs as well as members from Admissions, the Office of Research and the Athletics Department. SUMMARY. Bachelor's program coursework will be supplemented with early professional program biomedical sciences (BMS) training and mentorship in the form of quarterly anatomy laboratories and a monthly BMS lecture series with strong clinical application. The Athletic Department will serve as an important liaison to help recruit from undergraduate student athletes; this is a novel recruitment angle. The team is pursuing a NIH Institutional Training Grant ("T Series") to build this program under the university's umbrella initiative which aims to develop an Academic Health Center. CONCLUSIONS. The Nevada Health Authority declares that nearly all disciplines of healthcare demonstrate critical shortages in our state. As an example, 71% of Nevadans have no or only limited access to oral healthcare. Healthcare personnel shortages directly affect quality of care and patient outcomes. Professionals, families and businesses are documented to be deterred from moving to the state of Nevada based on these known issues. With increased resources and attention paid to anatomy education, the university's School of Dental Medicine has documented that there are now 2-3x the number of students entering specialized residency programs like Oromaxillofacial Surgery compared to the graduating class of 2020.

104.
*LOPEZ, Jasmyn A. and Sakti SRIVASTAVA. Division of Clinical Anatomy, Department of Surgery, Stanford University, Stanford, CA, 94305, USA.

Morphological Variations of the Brachial Artery and Distal Arterial Supply in Cadaveric Specimens.

INTRODUCTION. Brachial artery (BA) typically bifurcates into radial artery (RA) and ulnar artery (UA) at the cubital fossa. However, persistence of embryonic vessels can produce variant branching patterns, including high bifurcation of the brachial artery (HBBA). This study quantifies the prevalence of BA variations and assesses HBBA impacts on distal arterial morphology, with key implications for arteriovenous fistula (AVF) procedures. METHODS. Upper extremities in cadaveric specimens were dissected with standardized techniques. Arterial diameters were measured at the distal border of teres major, bifurcation site, and radial/ulnar styloid processes using digital calipers. Bifurcation level was recorded as distance from the proximal border of humeral epicondyles. Distal RA diameter was normalized to BA diameter (RA/BA ratio) to control for donor variation. SUMMARY. In 26 cadavers (52 limbs), prevalence of any BA branching variation was 21.2%. HBBA prevalence was 15.4% (11.5% unilateral; 3.8% bilateral), exceeding the commonly cited 7-10%. Additional variants included superficial ulnar (5.8%), high-origin superficial radial (3.8%), and median artery (1.9%). Right-sided HBBA was more frequent than left-sided HBBA (23.1% vs 7.7%) with no sex difference. HBBA limbs exhibited a 10.0% mean reduction in normalized distal RA diameter (Mann-Whitney p=0.0096), suggesting HBBA may be associated with reduced RA contribution distally. Furthermore, bifurcation level was positively correlated with BA diameter (Pearson

continued on next page

r=0.284, p=0.041). CONCLUSIONS. BA branching variants were common. HBBA occurred at a higher prevalence than previously reported and was significantly associated with reduced normalized RA diameter. Clinically, recognition of HBBA and distal morphological implications may explain discrepant non-invasive blood pressure measurements, guide intraoperative vessel selection, and inform access sites for AVF placement to improve maturation rates and reduce complications.

105.
* MEHTA ,Akshita and Prabhjot K.CHHABRA. Department of Anatomy, Mahatma Gandhi Medical College & Hospital, Jaipur , RJ, 302022, India.

Rare Variation of Hepatic Morphological Anomalies - A Cadaveric Case Report.

INTRODUCTION. Recognizing surface anatomical variations in liver is crucial to avoid misinterpretation during imaging and to ensure safety during hepatic surgery and transplantation. Among these, the combined presence of a *pons hepatis* —a parenchymal bridge connecting the right and left lobes, variations in the morphology of the caudate lobe, and complete absence of the quadrate lobe in liver is rare but clinically important anomaly. METHODS. Anatomical variations in liver specimen were found during routine abdominal dissection in a formalin-embalmed male cadaver aged 55 years conducted in the dissection hall of Department of Anatomy. Anatomical variations were noted and linear measurements were recorded using a calibrated digital vernier caliper, while curvilinear dimensions were measured using non-elastic surgical thread and subsequently quantified with the caliper. Each parameter was measured thrice to minimize observer error. DESCRIPTION. The presence of an open-type pons hepatis,an irregular caudate lobe shape variations not falling in any of the previous categories mentioned in literature, and a complete absence of the quadrate lobe were noted in cadaveric liver.The pons hepatis measuring 1.2 cm in length joined the right lobe and left lobes but it was not completely covering the fissure for ligamentum teres.H&E stained section of pons hepatis showed normal liver parenchyma with large vasculo-biliary structure. The caudate lobe demonstrated variations in elongation and width, with an underdeveloped caudate and papillary process not following any category in caudate lobe shape classification. The quadrate lobe was completely absent, with the gallbladder fossa continuous to the fissure for the ligamentum teres through pons hepatis. CONCLUSIONS. The presence of vasculo-biliary structures in the pons hepatis should be kept in mind while performing surgeries to prevent bleeding. A sound knowledge of the normal and variant liver anatomy is a prerequisite to having a favorable surgical outcome especially in the era of diagnostic imaging and minimally invasive surgical approaches. Hepatic surface variations must be taken into the differential diagnosis by radiologists and gastroenterologists.

106.
*KANDAVALLI, Naveen Babu, Bedia CASTELLANOS, Ramona BAEZ, Venkata Ramani MUDDALOOR and Sushama RICH. Department of Anatomy, School of Osteopathic Medicine, Touro University, New York City, NY 10027, USA.

Duplicated Inferior Vena Cava with a Horizontal Interiliac Vein and Double Right Gonadal Veins.

INTRODUCTION. Duplication of inferior vena cava (IVC) is a rare variation which is well-reported in the literature. Horizontal interiliac vein is reported in 10% of the duplicated IVC cases. Normal drainage of right gonadal veins into the right IVC is usually noted. The duplication of IVC is due to the persistence of left supracardinal veins. METHODS. Routine dissection of posterior abdominal wall in an 80-year-old Caucasian male donor during TouroCOM anatomy lab revealed duplicated IVC. Careful exploration of tributaries of IVC, common iliac veins, kidneys and azygous venous system was performed. SUMMARY. A right and left IVC of equal size are seen reuniting to form the main IVC at the level of L1. Right IVC measures 12 cm in length coursing on the right side

continued on next page

of abdominal aorta. Left IVC measures 14 cm coursing obliquely over the infrarenal aorta to join right IVC. A horizontal interiliac vein measuring 3 cm is connecting both common iliac veins at the body of L5 vertebra. A unique finding is duplicated right gonadal veins with medial one draining directly into right IVC. The lateral right gonadal vein is draining into the junction of right renal vein and right IVC. The left gonadal vein drains normally into the left renal vein. Hemi-azygos vein arises on the left side crosses to the right side at the level of T9 while a variation is noted in the course of accessory hemi-azygos vein as it crosses to the left side at T5 level. CONCLUSIONS. It is essential to understand the course of duplicated inferior vena cava and its associated venous variations in radiological interpretation of vascular imaging. This will help reduce the surgical risk in the treatment of any vascular dysfunctions.

108.
*PICHA, Kelsey J., Amy J. SPIES, Alex F. WONG, and Kellie C. HUXEL BLIVEN. Clinical Anatomy, Department of Interdisciplinary Health Sciences, A.T. Still University, Mesa, AZ, 85206.

Self-Regulated Learning Profiles and Exam Performance in a Graduate Human Anatomy Course.

INTRODUCTION. Anatomy is a foundational yet demanding course for graduate health sciences students requiring sustained independent study. Self-regulated learning (SRL) may support success, however, its relationships with test anxiety and exam performance remain unclear. We hypothesized that higher SRL would be associated with higher exam scores. This study described demographic profiles across SRL groups and examined if Motivated Strategies for Learning Questionnaire (MSLQ) scores predicted anatomy exam scores. METHODS. Before a 20-week anatomy course, first year physical and occupational therapy students (N=270) completed a survey on demographics, prior anatomy experience, and SRL using the 81-item MSLQ (motivation and learning strategies subscales). Total MSLQ scores were used to calculate tertiles for SRL groups (high, medium, low). The course had five practical and six written exams. Mixed ANOVA, χ^2 tests, and hierarchical regression analyses (SPSS v31) examined relationships between SRL and MSLQ subscales (including test anxiety) and exam scores. SUMMARY. No demographic or prior anatomy experience differences emerged across SRL groups. SRL groups differed in subscale composition, with motivation exceeding learning strategy in low and medium groups ($p<.001$), while high SRL learners demonstrated balanced profiles ($p=.79$). Overall grades did not differ by SRL group, though the medium SRL group outperformed the high group on one practical and four written exams ($p<.05$). Regression analysis showed limited variance explained by MSLQ motivation and learning strategy subscales ($R^2=.03$). When test anxiety was included, model fit improved ($R^2=.11$), and test anxiety emerged as a significant negative predictor of exam scores ($\beta\approx-.32$, $p<.001$), while motivation and strategy were not. CONCLUSIONS. Supporting students' emotional regulation alongside learning strategy development may enhance anatomy exam performance and promote success in rigorous anatomy courses.

109.
*YOUNG, Conor[1], Thai DO[2], Jeremy TAN[2], Grant BOXEY[1], and Mary MOON[1]. [1]Department of Cell Biology, University of Oklahoma Health Center, Oklahoma City, OK, 73104; [2]Dean McGee Eye Institute, Oklahoma City, OK, 73104

Repurposing Fully Fixed Donors for Ophthalmic Surgical Training: A Model for Eye Removal.

INTRODUCTION. Enucleation and evisceration are definitive procedures for painful blind eye, malignancy, trauma, and refractory infection. These operations require precise anatomical knowledge and technical skill. Fresh or soft-fixed donors are often used for ophthalmic training but are limited by cost and availability. Fully fixed donors, routinely used in anatomy education, may serve as a practical alternative. This descriptive study evaluates the feasibility of repurposing fully fixed donors from a clinical anatomy course to train ophthalmology residents in

continued on next page

eye removal surgery. RESOURCES. Implementation required collaboration among ophthalmologists, residents, anatomy faculty, and anatomy staff. Training used 20% formaldehyde-fixed donor heads or hemisected heads with intact orbital anatomy. Materials included appropriate PPE and standard ophthalmic instruments (forceps, blades, spring scissors, tenotomy scissors, hemostats, and eye muscle hooks). Ultrasound gel was injected to restore globe volume and replace vitreous support. Materials and processes were selected to promote feasibility and replicability. DESCRIPTION. The training was offered biannually alongside graduate clinical anatomy courses, with 7-10 residents per session. Under faculty supervision, residents performed enucleations and eviscerations; bilateral procedures were completed when possible. Reconstruction and implant placement were performed when available. Instruction emphasized anatomical identification, instrument handling, procedural sequencing, and safe dissection. SIGNIFICANCE. This model demonstrates a feasible, resource-efficient method for repeated eye removal using fully fixed donors. This approach allows learners to train with fully fixed donors in settings where budgetary or logistical constraints may limit access to soft-fixed donors, ultimately maximizing donor utilization and ethical stewardship.

110.

*JOHNSON, Mindy.[1] Daniel HANNAH[2], and Uzondu AGOCHUKWU[2]. [1]Department of Cellular Biology and Anatomy, Medical College of Georgia, Augusta University, Augusta, GA, 30912, USA; [2]Department of Orthopaedic Surgery, Medical College of Georgia, Augusta University, Augusta, GA, 30912, USA.

Integrated Anatomy for Orthopaedic Surgery: A Specialty-Focused Elective for Residency Prep.

INTRODUCTION. The Medical College of Georgia (MCG) offers four individualized curricular pathways to complete the Medical Degree. The Advanced Residency Preparation Pathway features an enrichment phase to strengthen readiness for residency. Orthopaedic Surgery demands a level of applied musculoskeletal anatomy beyond what is typically achieved in undergraduate medical education, yet no formal opportunities previously existed for students to revisit this material during the enrichment phase. To address this need, we developed a four-week elective for third-year students that integrates advanced anatomy with clinical and surgical application to support residency preparation. METHODS. The elective was developed through collaboration by anatomy faculty in the Department of Cellular Biology and Anatomy and faculty in the Department of Orthopaedic Surgery. This specialty was selected because it is a highly competitive career pathway, and its reliance on procedurally applied anatomy. The course combines cadaveric dissection, clinical and operating room observation, procedural simulation, and structured peer-teaching activities. SUMMARY. Student performance is assessed using rubrics developed for both formative and summative evaluations. Formative assessments include completeness and quality of cadaveric dissections, engagement in clinical and operating room settings, and participation in procedural simulations. Summative assessments consist of final prosections and case-based presentations that integrate anatomical, clinical, and surgical reasoning. CONCLUSIONS. This elective demonstrates how targeted, specialty-specific anatomy opportunities can reinforce and extend foundational knowledge beyond the clerkship phase of medical training. Integrating advanced anatomical study with clinical and surgical application may enhance student preparation for orthopaedic residency and support a more seamless transition to graduate medical education.

continued on next page

111.
*HUITT, Tiffany W.[1], Erica R. MALONE[1] and Manisha SINGH[2]. [1]Division of Clinical Anatomy, Department of Neuroscience, College of Medicine, University of Arkansas for Medical Sciences, Little Rock, AR 72205, USA; [2]Department of Internal Medicine, Nephrology, College of Medicine, University of Arkansas for Medical Sciences, Little Rock, AR 72205, USA.

A Multimodal Cadaveric Module for Peritoneal Dialysis: Integrating Anatomy and Procedural Realism.

INTRODUCTION. Peritoneal dialysis (PD) education often emphasizes procedural steps and simulation, with limited exposure to the anatomic principles essential for safe catheter placement, complication recognition, and effective patient counseling. To address this gap, we developed a multimodal clinical anatomy module for for PD education to enhance fellows' understanding of abdominopelvic three dimensional anatomy relevant to PD catheter function, procedural insight, and clinical confidence in caring for patients with home dialysis. RESOURCES. This module used a full embalmed cadaveric donor with abdominopelvic dissection; 3D CT reconstructions and resin-embedded cross-sections illustrating peritoneal relationships; and a soft-embalmed cadaveric donor providing near-physiologic tissue qualities for procedural exploration. Additional resources included ultrasound, PD catheters and tools, and pre-session review materials. DESCRIPTION. The module included three faculty-facilitated stations. The cadaveric dissection was used to demonstrate PD relevant anatomy of abdominal wall layers, peritoneal reflections, pelvic recesses, tunnel tracts, and relationships affecting fluid dynamics and catheter function. The radiologic and plastinated cross-sections reinforced spatial reasoning by correlating catheter pathways and potential spaces with corresponding anatomy. The procedural station used a soft-embalmed donor for ultrasound-guided localization of the peritoneal cavity, assessment of omental mobility, palpation of fascial planes, and visualization of structural causes of catheter malposition or outflow failure. SIGNIFICANCE. This module provides an anatomically grounded approach to PD training for nephrology fellows. To our knowledge, it is the first PD-focused anatomy module to incorporate cadaveric and radiologic anatomy with realistic procedural practice using soft-embalmed donors. Early feedback indicates enhanced understanding of regional anatomy, improved spatial conceptualization of catheter mechanics, and increased ability to identify anatomic contributors to common PD complications. The model is scalable and well suited for adoption in clinical anatomy and nephrology training programs.

113.
*RIVERA-PEREZ, Juan Antonio and Nirusha LACHMAN. Department of Clinical Anatomy, Mayo Clinic, Rochester, MN, 55905, USA.

Experiential Anatomy Laboratory Instruction within Structural Constraints for Clinical Trainees.

INTRODUCTION. Recent revisions to the Accreditation Council for Graduate Medical Education (ACGME) Program Requirements for Physical Medicine and Rehabilitation (PM&R) represent a shift in expectations for anatomy education. In 2026, the requirement for an anatomy laboratory for dissection was replaced with language mandating a structured anatomy program that includes access to a laboratory or equivalent experience. This change emphasizes access and educational outcomes rather than instructional modality, expanding flexibility while creating ambiguity for small programs with limited cohort size, limited protected educational time, and limited access to embalmed cadavers. The objective was to describe a blended anatomical instructional model aligned with revised PM&R requirements while preserving experiential, hands-on cadaveric learning. RESOURCES. A single PM&R residency program with a small resident cohort (n = 2) implemented a staged, specimen-anchored anatomical instructional model using regionally partitioned fresh-frozen cadaveric specimens. Faculty performed initial dissections to preserve anatomic context. Residents completed asynchronous specimen-specific video-

continued on next page

based preparation followed by hands-on dissection with synchronous remote faculty guidance. DESCRIPTION. Learners received four hours of supervised, experiential cadaver-based instruction per anatomic region within protected educational time, without requiring additional resident time for specimen preparation. Compared with fully virtual models, this approach preserved tactile engagement while maintaining faculty supervision. The dyadic format enabled focused instruction but imposed a constant learner spotlight and limited exposure to peer perspectives. Challenges included cumulative high-cost resources, including interstate logistics. SIGNIFICANCE. A blended, specimen-anchored anatomical instructional model offers a standards-aligned approach to meeting revised PM&R anatomy requirements. By providing structured access to laboratory-based cadaveric experiences through flexible instructional modalities, such models may support experiential learning while offering a practical option for small or resource-constrained programs.

115.
*CEVALLOS, Manuel, Will BRAUSCH, Katherine FREI, and Lauren PISANI. Department of Medical Education, Creighton University, Phoenix, AZ, 85012, USA.

Dissecting Deeper: Impact of Lower Extremity Fasciotomies on Anatomy Lab Medical Education.

INTRODUCTION. A cadaveric anatomy lab for medical education should provide opportunities to learn beyond dissection and the identification of anatomic structures. Students can take advantage of the anatomy lab to practice standard surgical procedures. RESOURCES. Lower-extremity fasciotomies were performed by medical students on cadaveric donors preserved in 4% formaldehyde. The procedures were first performed by a fourth-year medical student (MS4) under faculty supervision; later, an MS4 supervised second- and third-year medical students performing the procedure as part of a peer-mentoring learning experience. DESCRIPTION. In the leg, a longitudinal incision was made on the lateral aspect to expose the fascia overlying the anterior and lateral leg compartments. The superficial peroneal nerve was identified and protected. Fasciotomies of the anterior and lateral compartments were performed. A longitudinal incision over the medial leg exposed the fascia and the great saphenous vein. A fasciotomy of the superficial posterior compartment was performed. The soleus muscle was identified and elevated off the tibia to expose the deep posterior compartment. Lastly, in the thigh, a longitudinal incision was made over the lateral compartment. The iliotibial band was incised, and fasciotomies of the anterior and posterior thigh compartments were performed. Video and pictures will be discussed at the conference. SIGNIFICANCE. The opportunity to perform advanced surgical procedures, such as a fasciotomy, in a controlled setting augments the time spent in the anatomy lab. These procedures help review surface anatomy and anatomical structures, use instruments, re-evaluate potential complications to prevent them, and facilitate peer interaction. Hands-on learning of such procedures early in medical training enhances students' understanding of the approach and technique used and better prepares them to assist or perform the procedure in future clinical settings.

continued on next page

116.
*CEVALLOS, Manuel[1], Roxanne M. MURRY[2], Sarah N. PALMER[2], Jen PHILLIPS[2], Cameryn M. SAGE[2], and Brie SOLL[2].[1]Medical Education, School of Medicine, Creighton University, Phoenix, AZ, 85012, USA. [2]Physician Assistant Program, Creighton University, Phoenix, AZ, 85012, USA.

Sui Generis Tripartite Variation in Both Vertebral Arteries: Origin, Diameter, and Entry at Once.

INTRODUCTION. The vertebral arteries (VAs) originate as the first branch of the subclavian artery (95%). They travel superiorly and posteriorly, and in about 90% of people, the arteries "enter the transverse foramen" of the C6 vertebra, where they ascend vertically, passing through the transverse foramina of all subsequent cervical vertebrae (C5 through C2). After exiting the C2 foramen, they continue to the foramen magnum. Anatomical variations in the VAs can be defined by origin, cervical passage, and diameter, which are critically important for surgery, endovascular procedures, and cerebrovascular health. RESOURCES. During a cadaveric dissection in the anatomical course, a donor preserved in 4% formaldehyde was systematically examined. One female cadaver, with a documented history of congestive heart failure, emphysema, and Alzheimer's disease as the cause of death, exhibited an extremely rare vertebral artery variation, a bilateral triplet.DESCRIPTION. Dissection revealed variations in the origin, diameter, and "entry" of the vertebral arteries. The left VA originates from the aortic arch (2.4%), with an internal diameter of 1.95 mm (8%), and "enters" at C3 (0.1%). The right VA originates at the "trifurcation" (the brachiocephalic trunk splits into the right subclavian, right common carotid, and right VA; 1.2%), with an internal diameter of 5.57 mm, and "enters" at C4 (1.14%). Between parentheses is the rate of presentation for each variant. This is an unwonted tripartite of variations. SIGNIFICANCE: Variations in the vertebral artery (origin, level of entry into the transverse foramen, and caliber) are associated with clinical scenarios, including stroke, dissection risk, and iatrogenic injury during surgical procedures (e.g., ACDF). This case underscores the importance of a thorough understanding of both typical and variant vertebral artery anatomy for anatomists, radiologists, surgeons, and clinicians. Details of the variant type and clinical correlation will be presented for discussion.

117.
*HUR, Mi-Sun[1], Joe IWANAGA[2], R. Shane TUBBS[2]. [1]Department of Anatomy, Daegu Catholic University School of Medicine, Daegu, 42472, Republic of Korea; [2]Department of Neurosurgery, Tulane University School of Medicine, New Orleans, Louisiana, 70112, USA..

Depressor Anguli Oris as Convergence Site of Zygomaticus Major, Buccinator, and Orbicularis Oris.

INTRODUCTION. The depressor anguli oris (DAO) has been described as a depressor of the oral commissure; however, its anatomical relationships with adjacent perioral muscles, particularly the deep fibers of the zygomaticus major (Zmj), buccinator, and orbicularis oris, remain incompletely understood. METHODS. Microdissection was performed on seven formalin-fixed adult Korean cadavers (three males, four females); a total of fourteen hemifacial specimens were examined. The deep fibers of the zygomaticus major, buccinator, and orbicularis oris were traced toward the oral commissure and inferior perioral region, with particular attention to their integration into the depressor anguli oris, as well as their occasional redistribution into the platysma and risorius. SUMMARY. Deep fibers of the zygomaticus major descended past the lateral aspect of the oral commissure and merged into the depressor anguli oris in 10 of 14 hemifaces. Contributions from the buccinator to the DAO were identified in 9 specimens, and deep fibers of the orbicularis oris also merged into the DAO in 9 specimens. Integration of deep Zmj fibers into the risorius was observed in two specimens, while buccinator fibers contributed to the risorius in one specimen. In one specimen, deep fibers of the Zmj extended inferiorly to merge with the platysma. Co-convergence of deep Zmj fibers and buccinator fibers into the DAO

continued on next page

was a frequent finding. CONCLUSIONS. The depressor anguli oris functions as a convergence site for deep fibers from the zygomaticus major, buccinator, and orbicularis oris rather than as an isolated muscle. This anatomical arrangement provides a structural basis for functional coupling between smile-related and depressor muscle systems at the oral commissure and may be relevant to facial expression analysis, reconstructive surgery, and aesthetic interventions involving the perioral region.

118.

*HUR, Mi-Sun[1], Joe IWANAGA[2], R. Shane TUBBS[2]. [1]Department of Anatomy, Daegu Catholic University School of Medicine, Daegu, 42472, Republic of Korea; [2]Department of Neurosurgery, Tulane University School of Medicine, New Orleans, Louisiana, 70112, USA.

The Upper Orbicularis Oris: Superficial–Deep Fiber Architecture and Convergence.

INTRODUCTION. This study aimed to delineate the layered architecture and fiber continuity of the upper orbicularis oris (upper OOr) through detailed cadaveric dissection. METHODS. Twelve hemifaces from six adult Korean cadavers were dissected. The levator labii superioris (LLS), zygomaticus minor (Zmi), buccinator, and depressor anguli oris (DAO) were carefully traced with particular attention to fiber direction, interdigitation, and continuity within the upper OOr. SUMMARY. The upper OOr exhibited a predominantly layered architecture composed of superficial and deep components. The superficial layer consisted mainly of obliquely descending fibers from the LLS and Zmi. The LLS fibers either inserted into the ipsilateral upper lip or coursed medially beneath the nasal base, where they intermingled with contralateral LLS fibers to form a sling-like configuration; some of these fibers continued superiorly and attached to the contralateral side. The Zmi fibers descended obliquely and inserted into the ipsilateral upper lip. Within the upper lip, partial blending between superficial fibers and deeper muscle fibers was observed. The deep layer was composed of muscle fibers continuous with the DAO and buccinator. These fibers ascended toward the upper lip and crossed the descending fibers of the LLS and Zmi in an opposing orientation, forming a structurally integrated but directionally distinct component. CONCLUSIONS. The upper OOr demonstrates a layered yet functionally integrated architecture in which superficial and deep muscle components exhibit opposing fiber orientations. The superficial fibers descend toward the upper lip, whereas the deep fibers ascend from the lower facial musculature. Partial blending between these counter-oriented fibers within the upper lip suggests that the upper OOr functions not as a simple circumferential sphincter, but as a dynamic convergence zone capable of modulating perioral tension and lip position. This architectural arrangement may provide a structural basis for fine motor control of upper lip movement and has important implications for perioral and subnasal surgical interventions.

119.

*MARR, Eric[1], Megan C. COSPER[2], Catrin PITTACK[1], Kurt E. WEAVER[3], and Zachary R. GALLAHER[1]. [1] Neurobiology and Biophysics Department, University of Washington School of Medicine, Seattle, WA, 98195, USA; [2] Department of Human Physiology, Gonzaga University School of Health Sciences, Spokane, WA 99258, USA; [3] Department of Radiology, University of Washington School of Medicine, Seattle, WA, 98195, USA.

Integrating Dissection Videos in Anatomy Labs: Pre-Lab vs In-Lab Approaches for Novice Dissectors.

INTRODUCTION. Video-based resources are popular supplements for anatomy laboratory instruction. However, purchasable resources require costly subscriptions, and producing high-quality in-house resources may seem daunting. This study compared two feasible, low-cost approaches to integrating in-house dissection videos into gross anatomy labs: a single pre-lab video paired with a traditional guide versus multiple short videos

continued on next page

embedded into a virtual guide. METHODS. First-year medical students at two University of Washington School of Medicine sites completed their first dissections using distinct lab guide formats. Students in Seattle (pre-lab group; n = 73) viewed a 30-minute pre-lab video demonstrating the entire procedure and used a static PDF guide during lab. Students in Spokane (in-lab group; n = 45) did not view the pre-lab video and used a virtual lab guide containing the same text and images with the addition of short (15–120 s) video clips demonstrating individual steps. Student perceptions were assessed via post-lab survey. Dissection time was recorded for each group, and dissection quality was rated independently by three raters. SUMMARY. The pre-lab group reported higher satisfaction with the overall lab guide, instructional clarity, and visual elements, despite receiving the same written instructions and static images. However, the in-lab group spent more time on task and achieved higher dissection quality, especially for structures dissected later in the session. CONCLUSIONS. Both approaches to in-house video integration supported anatomy learning, suggesting a mixed approach may be best practice. For novice dissectors, slower, comprehensive pre-lab videos may be preferred; a practical advantage for faculty since these require less editing and are relatively easy to post on classroom webpages. Future studies will assess preferences and outcomes among more experienced student dissectors.

120.

*VALENZUELA FUENZALIDA, Juan J.[1,2], Claudia MOLINA-BUSTAMANTE[1], Constanza ARANEDA RAIPANE[1], Vicente BAEZA GARRIDO[1], Milovan KOSCINA[1], Jessica Paola LOAIZA GIRALDO[3], Martin TRUJILLO-RIVEROS[1], Marko KONSCHAKE[4], Maria PIAGKOU[5], George TRIANTAFYLLOU[5], Panagiotis PAPADOPOULOS MANOLARAKIS[6], Juan SANCHIS-GIMENO[7], Diego Fernando LOPEZ[3], Andrés RIVEROS-VALDES[8], Pablo NOVA-BAEZA[1], Mathias ORELLANA-DONOSO[9], Leonel Luciano CESAR[10], Morgan J. FORSTON[10], and Nirusha LACHMAN[10]. [1]Department of Morphology, Universidad Andrés Bello, Santiago, Chile; [2]Department of Chemical and Biological Sciences, Universidad Bernardo O'Higgins, Santiago, Chile; [3]Faculty of Health Sciences, Universidad Central del Valle del Cauca, Tuluá, Colombia; [4]Medical University of Innsbruck, Innsbruck, Austria; [5]National and Kapodistrian University of Athens, Athens, Greece; [6]General Hospital of Nikaia-Piraeus, Athens, Greece; [7]University of Valencia, Valencia, Spain; [8]Universidad San Sebastián, Chile; [9]Universidad Finis Terrae, Santiago, Chile; [10]Mayo Clinic College of Medicine and Science, Rochester, MN, 55905, USA.

Middle Cerebral Artery Variants: A Systematic Review and Meta-analysis.

INTRODUCTION. The middle cerebral artery (MCA) shows anatomical variability with implications for neurovascular diagnosis and intervention. Reported prevalence varies due to heterogeneity. This study aimed to synthesize the prevalence of MCA variants and evaluate the impact of sampling and definitions on estimates. METHODS. A systematic search of Medline, Scopus, Web of Science, Google Scholar, CINAHL, and LILACS was conducted through October 2025. Observational studies reporting MCA variants were included. Two reviewers independently screened and extracted data. Quality was assessed using the AQUA tool. Random-effects meta-analyses were performed. Internal validity analyses restricted estimates to representative samples. SUMMARY. A total of 129 studies were included. Nonspecific MCA variants showed a pooled prevalence of 7% (95% CI: 3–12%; I^2=94%), decreasing to 1.6% after restriction. Bifurcation was most common (74%; 95% CI: 69–80%; I^2=85.8%), followed by trifurcation (15%; 95% CI: 10–20%; I^2=84.1%) and rare tetrafurcation (0%; 95% CI: 0–1%; I^2=16.1%). MCA fenestration showed 7% prevalence (95% CI: 4–10%; I^2=98.3%), decreasing to 1.6%. MCA "absence" (often reflecting non-visualization rather than true agenesis) showed 46% (95% CI: 39–54%; I^2=99.9%); internal validity restriction reduced estimates to 1%, indicating inflation due to heterogeneous definitions and sampling. CONCLUSIONS. Reported prevalence is strongly influenced by sampling and definitions. In highly heterogeneous data, pooled estimates likely overestimate true population-level prevalence. Standardized criteria and representative sampling are required.

continued on next page

121.

JI, Hyun-Ju [1], Yu-Ran HEO [1], Jiong-Zhen PIAO [1], Young-Chun GIL [2], Kyung-Seok HU [1], and Hee-Jin KIM [1]. [1]Division in Anatomy and Developmental Biology, Department of Oral Biology, Yonsei University College of Dentistry, Seoul, 03722, South Korea; [2]Department of Anatomy, Chungbuk National University School of Medicine, Cheongju, 28644, South Korea.

Intraoral Ultrasonography for Visualizing Intrinsic Tongue Muscles and the Deep Lingual Artery.

INTRODUCTION. Understanding the complex arrangement of intrinsic tongue muscles and the location of the deep lingual artery is vital for both clinical interventions and anatomical education. Our study aimed to evaluate the effectiveness of high-resolution intraoral ultrasonography in identifying these structures by comparing the images with known anatomical landmarks. METHODS. We conducted ultrasonographic examinations on 33 Korean adults using a B-mode system equipped with a 15 MHz hockey-stick transducer. Five predefined areas on the dorsal and lateral surfaces of the tongue were systematically scanned to identify the intrinsic muscle layers and the deep lingual artery. Statistical analyses, including chi-square and independent t-tests, were used to assess the findings. SUMMARY. The intrinsic tongue muscles—superior longitudinal, transverse, vertical, and inferior longitudinal—were distinctly visualized in layered structures. Muscle separation was clear on the dorsal surface, though vertical and transverse lingual muscles appeared in the same layer. The deep lingual artery was identified in 70.6% of participants at a mean depth of 0.9 cm. The deep lingual artery was identified in 70.6% of participants, primarily in the anterior tongue, at a mean depth of 0.9 cm (range, 0.6–1.2 cm). Exploratory analysis showed participants with visible right vertical lingual muscle were younger (31.1 ± 9.7 years) than those without (36.5 ± 13.1 years; P = 0.250, Cohen's d = 0.44), suggesting a potential age-related pattern requiring validation in larger studies. We also noted that younger participants tended to have more visible vertical lingual muscles, suggesting an age-related pattern. CONCLUSIONS. High-resolution intraoral ultrasonography provides detailed and anatomically consistent visualization of the tongue's internal structures. These results support its utility as a non-invasive tool for clinical assessment and as a valuable resource for anatomical education.

122.

*NGWA, Funiba C.[1], Alexander CHANG[1], Kyle LEE[1], and Adam WALCHAK[2]. [1]Lewis Katz School of Medicine at Temple University, Philadelphia, Pennsylvania, 19140, USA; [2]Division of Plastic and Reconstructive Surgery at Temple University Hospital/Fox Chase Cancer Center, Philadelphia, Pennsylvania, 19111, USA.

Prevalence and Clinical Implications of the Peroneus Quartus Muscle: A Scoping Review.

INTRODUCTION. The peroneus quartus (PQ) muscle is a variable accessory muscle of the lateral compartment of the leg, typically originating from the fibula or peroneus brevis and inserting onto the retro trochlear eminence of the calcaneus, the peroneal tubercle, or the cuboid. Its presence can alter the biomechanics of the peroneal tendons, potentially contributing to lateral ankle pain, peroneal tendon subluxation, or tears. Recognition of PQ anatomy is therefore important for both diagnostic imaging and surgical planning. Prior reviews have summarized literature before 2014; this scoping review focuses on studies published from 2014 to 2026. METHODS. We conducted a scoping review that identified seven studies published from 2014 onward, including MRI-based and cadaveric series. These studies were analyzed for sample size, prevalence, methodology, and clinical relevance. The combined dataset encompassed 2,333 specimens or imaging cases. Overall prevalence was calculated by pooling the number of PQ-positive cases across studies relative to the total number of cases. SUMMARY. Individual study prevalence ranged from 5.0% to 20%, with MRI studies reporting slightly higher rates (10.6%–13.8%) than cadaveric studies (5.0%–20%). Across all included studies, the total prevalence of the PQ was 11.0% (368/2,333). Cadaveric studies highlighted anatomical variability, while MRI studies linked PQ presence to peroneal tendon pathology, including tendinopathy and risk of tendon tears. CONCLUSIONS. The PQ muscle is

continued on next page

present in approximately 11% of individuals in contemporary studies, a prevalence comparable to rates reported in pre-2014 series. Its identification is clinically relevant for the evaluation of lateral ankle pain and peroneal tendon disorders. Awareness of PQ morphology and prevalence aids radiologists and surgeons in accurate diagnosis and preoperative planning.

123.
*NGWA, Funiba[1], Kyle LEE[1], Alexander CHANG[1], Sameer PATEL[2], and Adam WALCHAK[2]. [1]Lewis Katz School of Medicine at Temple University, Philadelphia, Pennsylvania, 19140, USA; [2]Division of Plastic and Reconstructive Surgery at Temple University Hospital/Fox Chase Cancer Center, Philadelphia, Pennsylvania, 19111, USA.

Asymptomatic Severe Knee Osteochondritis Dissecans in an Elite Collegiate Basketball Player.

INTRODUCTION. Osteochondritis Dissecans (OCD) of the knee is a relatively uncommon joint disorder that typically manifests in athletes due to repetitive microtrauma and clinically presents with progressive pain, effusion, tenderness, and mechanical symptoms. This case aims to highlight an atypical presentation in a collegiate-level basketball player with minimal preceding symptomatology who sustained an acute, function-limiting lesion during routine play. RESOURCES. Radiographic imaging such as plain radiographs and magnetic resonance injury (MRI), as well as operative findings, clinical presentation, and patient history were obtained to characterize the defect. DESCRIPTION. A 20-year-old male collegiate basketball player presented with complaints of acute right knee discomfort following a lateral plant and defensive lunge while playing in a game. Imaging reports displayed an osteochondritis dissecans lesion of approximately 2x2 cm to the posterior aspect of the lateral femoral condyle of the right knee with an unstable, displaced fragment. Open reduction and internal fixation (ORIF) was performed. SIGNIFICANCE. This report highlights the biomechanical susceptibility to osteochondral defects, even in the absence of prior significant symptoms, challenging reliance on symptom severity for injury indication and supporting consideration of earlier imaging in athletic populations.

124.
*NGWA, Funiba C.[1], Alexander CHANG[1], Kyle LEE[1], Sameer PATEL[2], and Adam WALCHAK[2]. [1]Lewis Katz School of Medicine at Temple University, Philadelphia, Pennsylvania, 19140, USA; [2]Division of Plastic and Reconstructive Surgery at Temple University Hospital/Fox Chase Cancer Center, Philadelphia, Pennsylvania, 19111, USA.

From the Battlefield to the Textbook: War's Influence on Musculoskeletal Anatomy Education.

INTRODUCTION. Armed conflict has historically served as an unintentional yet powerful catalyst for advances in musculoskeletal anatomy. From the battlefields of the Napoleonic Wars to the trauma wards of World War II, surgeons confronted injuries of unprecedented scale and complexity, compelling rapid innovation in anatomical understanding and surgical technique. This study examines how wartime medical necessity drove foundational discoveries in MSK anatomy and permanently shaped how the subject is taught in medical education. RESOURCES. This study draws on historical medical literature, military surgical records, anatomical textbooks, and wartime case reports spanning the 18th through 20th centuries. Key texts, battlefield surgical manuals, and the published works of military surgeons are analyzed to trace how combat trauma informed evolving knowledge of bones, joints, muscles, and peripheral nerves. DESCRIPTION. This study explores how successive armed conflicts exposed surgeons to high volumes of complex musculoskeletal trauma, accelerating anatomical discovery and refining surgical approaches to fractures, amputations, nerve injuries, and soft tissue reconstruction. It examines the contributions of military surgeons such as Dominique Jean Larrey and Sir Herbert Seddon, whose wartime observations became cornerstones of modern MSK anatomy and orthopedic education. It further considers how lessons from the battlefield were codified into medical curricula, shaping anatomy

continued on next page

instruction for generations of surgeons. SIGNIFICANCE. This study highlights the profound role of military medicine in advancing musculoskeletal anatomy education. By tracing the lineage from battlefield observation to anatomical textbook, it offers educators and historians a richer understanding of how crisis-driven innovation shapes medical curricula and underscores the enduring relevance of wartime surgical heritage in contemporary MSK education.

125.

* NGWA, Funiba C.[1], Alexander CHANG[1], Kyle LEE[1], Louis HAN[2], Adam WALCHAK[3], and Theresa PAZIONIS[4]. [1]Lewis Katz School of Medicine at Temple University, Philadelphia, Pennsylvania, 19140, USA; [2]School of Engineering and Applied Science at University of Pennsylvania, Philadelphia, Pennsylvania, 19104, USA; [3]Division of Plastic and Reconstructive Surgery at Temple University Hospital/Fox Chase Cancer Center, Philadelphia, Pennsylvania, 19111, USA; [4]Department of Orthopaedics and Sports Medicine at Temple University Hospital, Philadelphia, Pennsylvania, 19140, USA.

Mechanical Thresholds of Lumbar Pars Fracture: A Scoping Review of Cadaveric Shear Force Data.

INTRODUCTION. Spondylolysis, a fracture of the pars interarticularis, is among the most common causes of low back pain in young and athletic populations. Despite its clinical prevalence, the mechanical shear forces required to produce this injury remain poorly consolidated in the literature. The purpose of this study is to aggregate cadaveric biomechanical data to establish a quantitative shear force threshold for lumbar pars fracture and inform clinical understanding of its injury mechanism. METHODS. A scoping review identified studies utilizing human cadaveric lumbar vertebrae to measure shear forces at pars interarticularis failure. Four studies met inclusion criteria: Cyron et al. (1976), Adams et al. via Gallagher et al. (2012), Skrzypiec et al. (2012), and Bisschop et al. (2012), totaling 46 human cadaveric specimens across all studies. SUMMARY. Pooled analysis yielded a mean shear force to failure of 1800.70 N (SD ±713.87 N), with individual study means ranging from 1623.94 N to 3253.33 N. Across all specimens, the minimum recorded failure force was 600 N and the maximum was 3570 N. This wide range reflects variability in specimen age, bone density, and testing methodology. Critically, the lower threshold of 600 N approaches forces plausibly generated during repetitive athletic activity, strongly supporting a cumulative fatigue fracture mechanism underlying spondylolysis rather than a single traumatic event. CONCLUSIONS. Lumbar pars fracture occurs across a broad shear force range of 600–3570 N, with a pooled mean of 1800.70 N. Standardized cadaveric testing protocols are needed to reduce inter specimen variability in future research. These findings contribute to foundational MSK anatomical knowledge and may inform injury prevention strategies, return-to-play protocols, and surgical planning for spondylolysis.

continued on next page

Thank You!

for attending the 43rd Annual Meeting of the
American Association of Clinical Anatomists in Rochester, Minnesota.

We look forward to seeing you next year.

The 2027 Annual Meeting will be held in Lubbock, Texas from June 3-7, 2027

at Texas Tech University Health Science Center.



For further information, please visit www.clinical-anatomy.org.